CPP 7/0002-01
Acc. 1991-119-01 (v. 1)

HUMAN CALCULI.

126.	Vesical.	Uric acid,	1 fragment.
127.	do	Phosphatic,	do
128.	do		1 do
129.	do	Uric acid,	1 do
130.	do		1 calculus.
131.	do		1 fragment.
132.	do	Phosphatic,	1 do
133.	do		1 do
134.	do	Phosphatic,	1 do
135.	do		1 do
136.	do		1 do
137.	do		1 do
138.	do		1 calculus.
139.	do		1 fragment.
140.	do	Uric acid,	1 do
141.	do	Nucleus uric acid. Crust phosphatic,	1 do
142.	do		1 calculus.
143.	do	Phosphatic,	fragments.
144.	do	do	1 calculus.
145.	do	Uric acid,	1 fragment.
146.	do		1 do
147.	do	Phosphatic,	1 calculus.
148.	do	do	
149.	do	do Hollow,	1 do
150.	do	do	1 calculus.
151.	do	Uric acid,	fragments.
152.	do	Phosphatic,	do
153.	do	Nucleus uric acid. Crust phosphatic,	1 do
154.	do	Phosphatic,	do
155.	do		2 do
156.	do	Phosphatic,	do
157.	do		2 do
158.	do	Passed per vias naturales. From the bladder of Mrs. S. Gray, in articulo mortis. Broad Kiln Hundred, Sussex Co., Delaware. W. W. Wolfe, M. D., Milton, Sussex Co., Delaware,	1 calculus.

CPP 7/0002-01
Acc. 1991-119-01 (v. 1)

HUMAN CALCULI.

159.	Vesical.	Phosphatic,		fragments.
160.	do		2	do
161.	do	Phosphatic,		do
162.	do		1	do
163.	do	Uric acid,	1	do
164.	do		2	do
165.	do	Phosphatic,	1	do
166.	do	do		do
167.	do	do		do
168.	do	do	1	calculus.
169.	do	do		fragments.
170.	do	do		do
171.	do	Uric acid,	1	do
172.	do	do	1	do
173.	do	do	1	calculus.
174.	do		2	fragments.
175.	do	Phosphatic,	1	do
176.	do	do		do
177.	do	Nucleus uric acid,	1	do
		Crust phosphatic,	1	calculus.
178.	do			fragments.
179.	do	Phosphatic,		do
180.	do	do	1	do
181.	do	Nucleus oxalate of lime. Crust phosphatic,	2	do
182.	do		2	do
183.	do	Uric acid,	2	do
184.	do	Phosphatic,		do
185.	do	Post-mortem specimen. Dr. Webster,	1	calculus.
186.	do	Cut from Alderman Ireland, by T. D. Mütter. Weight, 8 oz,		fragments.
187.	do	Cut by Dr. Physick, from the bladder of Chief Justice Marshall. Presented by Dr. Randolph,	6	calc. and fragments.

Total number of vesical calculi—188.

CASTS.

1. Cast of the Ogleby calculus.
2. Cast of calculus extracted, post-mortem, by Winterhooven, Brussels. Presented by C. D. Meigs, M. D.
3. Cast of cholesterin calculus, (biliary.) Filling the entire gall bladder.
4. Brick dust, used by a patient to imitate urate of soda deposits.
5. Piece of brick, shaped to imitate a calculus, and so employed by an hysterical patient. Museum of Albany Medical College.

Total number of casts—5.

NUMBER OF SPECIMENS.

Biliary Calculi. Human,	55
Intestinal, biliary, salivary and other calculi, from men and animals,	35
Renal, urethral and vesical calculi. Human,	188
Casts and fictitious calculi and deposits,	5
Total,	283

C A T A L O G U E

of the

MUTTER MUSEUM

of the

COLLEGE OF PHYSICIANS OF PHILADELPHIA.

By

Guy Hinsdale, A.M.,M.D.,

Curator 1884- 1948? no-pro 1961

SCHEME OF ENUMERATION.

1009.4N
1009.H2X Skeu
Trema

1174 - Anatomical specimens

24 - DEVELOPMENTAL SKELETONS.

16 - 1000-Articulated.

6 - 1001-Disarticulated.

11 - SKELETONS.

10 - 1002-Articulated.

1003-Disarticulated.

1 - 1004-Ligamentons.

1005-Fragmentary.

334 - SKULLS.

213 - 1006-Of the ethnological series.

36 - 1007-Unspecified. (crephining

9 - 1008-Disarticulated.

6 - 1009-Occipital bone.

9 - 1010-Parietal bones.

4 - 1011-Frontal bone.

9 - 1012-Temporal bones.

2 - 1013-Sphenoid bones.

1014-Ethmoid bone.

8 - 1015-Superior maxillary.

1016-Palatal bone.

1017-Vomer.

1018-Lachrymal bones.

1019-Nasal bones.

1020-Malar bones.

34 - 1021-Inferior maxillary.

1022-Hyoid bone.

4 - 1023-Calvaria.

VERTEBRAE.

48 - Spinal column

11 - 1024-Cervical.

22 - 1025-Thoracic. (vertebrae column.)

12 - 1026-Lumbar.

3 - 1027-Sacrum.

1028-Coccyx.

18 - thorax

5 - 1029-Sternum.

33 - 1030-Ribs.

2 - 1031-Thorax.

22 - 1032-Clavicle.

16 - 1033-Scapula.

90 - Arm

26 - 1034-Humerus.

4 - 1035-Shoulder-joint.

4 - 1036-Elbow-joint.

13 - 1037-Radius.

3 - 1038-Ulna.

23 - 1039-Radius and ulna.

5 - 1040-Wrist-joint.

1 - 1041-Carpal bones.

1 - 1042-Metacarpal bones.

1 - 1043-Phalanges.

9 - 1044-Bones of the hand articulated.

143 - Leg

29 - 1045-Innominate bone. - Pelvis

48 - 1046-Femur.

5 - 1047-Hip-joint.

4 - 1048-Knee-joint.

25 - 1049-Tibia.

5 - 1050-Fibula.

7 - 1051-Tibia and fibula.

1 - 1052-Ankle-joint.

2 - 1053-Tarsal bones.

1054-Metatarsal bones.

1055-Phalanges.

8 - 1056-Bones of the foot articulated.

8 - 1057-Patella.

1058-Sesamoid bones.

172 - 1059-Ossicles of the ear.

2 - 1060-Ligaments.

1061-Tendons.

1062-Fascia.

1063-Bursae.

1064-Muscles.

1065-Blood.

14 - CIRCULATORY SYSTEM.

1708-108-3 2 1066-Heart.

1067-Aorta.

4 - 1068-Arteries.

2 - 1069-Veins.

1070-Capillaries.

1071-Digestive tract.

1072-Mouth, pharynx, etc.

1073-Tongue.

1074-Oesophagus.

1075-Stomach.

1076-Intestine.

2 - 1077-Respiratory system. 309

2 - 1078-Larynx. 309

1079-Trachea.

1080-Bronchial tubes.

1- 1081-Lungs.

1082-Pleura.

5- NERVOUS SYSTEM.

1083-Brain.

1-1084-Spinal cord.

1- 1085-Cranial nerves.

3- 1086-Spinal nerves.

1087-Sympathetic nerves.

120 REPRODUCTIVE ORGANS.

1088-Male.

1- 1089-Female. 321

113- 1090-Products of conception.--Embryology.

2 Viscera;abdominal.

1- 1091-Liver.

1092-Spleen.

1- 1093-Kidney.

1094-Ureters.

1095-Bladder.

1096-Peritoneum.

1097-Skin.

24-1098-Teeth.

1099-Eye.

107- 1100-Ear.

OSTEOLOGICAL COLLECTION.

INJURIES OF BONES (FRACTURES). — 723

VARIETIES OF FRACTURE.

110150 — Depressed — 17

6 — 1101-Fissured.

1 — 1102-Punctured.

61 — 1103-Oblique. — ~~110350 "Contre coup"~~

45 — 1104-Comminuted.

2 — 1105-~~Splintered~~. Formed

9 — 1106-Impacted.

16 — 1107-Multiple.

3 — 1108-Compound.

23 — 1109-Separation of Epiphyses.

1 — 1110-Spontaneous fracture.

165 — 1111-Gunshot fracture.

1 — 1112-Intra-uterine.

4 — 1113-Artificial.

151 — 1114-Process of repair of fractures.

10 — 1115-Fractures united with deformity.

26 — 1116-Displacement.

4 — 1117-Rotation.

15 — 1118-Excessive callus.

4 — 1119-Failure of process of osseous union.

8 — 1120-Union of fibrous tissue.

58 — 1121-Ununited fractures.

2 — 1122-False joints.

1 — 1123-Deviations from the ordinary process of repair.

1 — 1124-From necrosis.

51 — 1125-Luxations of bones. 455

1129 series are all cross index numbers and do not appear on the specimens.

1157.04 See Vol. 1 Pg 557
29 - ~~1129.50~~ x index Hypertrophic Osteitis
1157.07 See Vol. 1 - Pg 558
2 - ~~1129.52~~ x index Osteitis Deformans
1179.01 See Vol. 1 - Pg. 629
44 - ~~1129.53~~ x index Osteitis
1299.25 Condensing Osteitis Vol. 1 - Pg 905
10 - ~~1129.56~~
1172.11 Eburnation Vol. 1 - Pg. 613
15 - ~~1129.60~~
1178.03(a) Cancrum Oris Vol. 1 - Pg 623
3 - ~~1129.66~~
1269.30 Periosteitis Vol. 1 - Pg. 827
29 - ~~1129.70~~
1404.31 Osteomyelitis Vol. 1 - Pg. 1139
3 - ~~1129.76~~

DISEASES OF BONES.—699

11- 1126-Hypertrophy.

17- 1127-Atrophy.

12- 1128-Absorption by pressure.

91- 1129-~~Inflammation~~ Exostosis and its results.
135- 1129.50 Miscellanious
95- 1130-Caries. 13- 1130.75 Pott's disease. Cross index no. - 1194 See spec no. Vol. 1 - Pg 671

55- 1131-Necrosis.

9- 1132-Rickets.

1133-Mollities ossium.

96- 1134-Syphilis.

4- 1135-Tumors. (20) see Page 17

1136-Disease of Joints.

2- 1137-Inflammation and its results. 90- 1137.50 ankylosis = 1194.25 Vol 1 Pg 681 Cross index no.

93- 1138-Changes due to rheumatoid arthritis.

1139-Changes due to gout.

1140-Loose bodies in joints.

1- 1141-Excision of joints.

1142-Foreign bodies in joints.

Peruvian skull 467

TUMORS OF BONES.-4

1135- Lymphonea.

1135.05-Sarcoma.

1135.10-Glioma.

1135.15-Gumma.

1135.20-Tubercle.

1135.25-Fibroma.

1135.30-Keloid.

1135.35-Lipoma.

1135.40-Myxoma.

1135.45-Chondroma.

4- 1135.50-Osteoma.

1135.55-Rhabdo myoma.

1135.60-Leiomyoma.

1135.65-Neuroma.

1135.70-Papilloma.

1135.75-Adenoma.

1135.80-Carcinoma.

1135.85-Epithelioma.

1135.90-Hydatids.

1135.95-Unspecified.

19- ~~1143~~ Prehistoric Trephined Skulls. 467

16- 1145- Skeletons;pathological. 471

INJURIES AND DISEASES OF PARTICULAR BONES.

SKULL.

3- 1150-Congenital malformations. 483

61- 1151-Fractures of the 485

Diseases of the

1- 1152-Hypertrophy. 547

1153-Atrophy.

1154-Sclerosis.

1155-Absorption from pressure. 549

1155 1156-Caries - 551 (1155)

1156 1157-Necrosis. 555

1157 1158-Other results of inflammation.

1159-Rickets.

1160-Mollities ossium.

1161-Syphilis. 559

1162-Tumors and their effects. (20)

1163- Hydrocephalous.

1164-Frontal suture.

1165-Wormian bones.

1166-Unspecified.

1167-Miscellaneous.

FACE.

1168-Luxation of the bones of

1169-Fractures of the bones of 561

1170-Diseases. miscellaneous.

1171-Congenital malformation. 609

1177-

1174-Caries 617

1179

1182-Tumors and their effects. 629

1172- Hypertrophy
1173- Atrophy
1174- Sclerosis
1175- Absorption from pressure
1176- Caries
1177- Necrosis
1178- Other results of inflamatie
1179- Rickets
1180- Mollities Ossium
1181- Syphilis.

Vertebrae.

1183-Congenital malformation. 635

1184-Spina bifida. 645

1185-Deficient union.

1186-Supernumerary.

1187-Luxations. 649

1188-Fractures. 651

1189-Diseases,

VERTEBRAE.

1190-Hypertrophy.

1191-Atrophy. 657

1192-Curvature. 661

1193-Absorption from pressure. 659

1194-Inflammation and its results(Caries)(Anchylosis). 673

1195-Necrosis, 713

1196-Rickets.

1197-Mollities ossium.

1198-Tumors.

1199-Hyoid bone. 717

STERNUM.

1200-Congenital malformation.

1201-Luxations.

1202-Fractures. 719

DISEASES.

1203-Hypertrophy.

1204-Atrophy.

1205-Sclerosis.

1206-Absorption from pressure. 721

1207-Caries. 723

1208-Necrosis.

1209-Other results of inflammation.

1210-Rickets.

1211-Mollities ossium.

1212-Syphilis.

1213-Tumors and their effects.

1214-Miscellaneous. 725

1215-Congenital malformations.

RIBS.

1216-Luxations.

1217-Fractures. 725

1218-1229-Diseases.

CLAVICLE.

1230-Congenital malformations.

1231-Luxations.

1232-Fractures. 747

1233-1244 Diseases.

SCAPULA.

1245-Congenital malformations. 763

1246-Luxations.

1247-Fractures.

1248-1259 Diseases.

HUMERUS.

1260-Congenital malformations.

1261-Luxations.

1262-Fractures. 775

1263-1274 Diseases.

RADIUS.

1275-Congenital malformations.

1276-Luxations.

1277-Fractures. 955

1278-1289 Diseases.

ULNA.

1290-Congenital malformations.

1291-Luxations.

1292-Fractures.

1293-1304 Diseases.

RADIUS AND ULNA.

1305-Congenital malformations.

1306-Luxations.

1307-Fractures.

1308-1319 Diseases.

CARPAL BONES.

1320-Congenital malformations.

1321-Luxations.

1322-Fractures.

1323-1334 Diseases.

METACARPAL BONES.

1335-Congenital malformations.

1336-Luxations.

1337-Fractures.

1338-1349 Diseases.

PHALANGES.

1350-Congenital malformations.

1351-Luxations.

1352-Fractures.

1353-1364 Diseases.

PELVIS.

1365-Malformation.

1366-Luxations.

1367-Fractures.

1368-1379 Diseases.

INNOMINATE.

1380-Congenital malformation.

1381-Luxations.

1382-Fractures.

1383-1394 Diseases.

FEMUR.

1395-Congenital malformations.

1396-Luxations.

1397-Fractures.

1398-1409 Diseases.

PATELLA.

1410-Congenital malformations.

1411-Luxations.

1412-Fractures.

1413-1424 Diseases.

TIBIA AND FIBULA.

1425-Congenital malformations.

1426-Luxations.

1427-Fractures.

TIBIA.

1440-Congenital malformations.

1441-Luxations.

1442-Fractures.

FIBULA.

1455-Congenital malformations.

1456-Luxations.

1457-Fractures.

1458-1469 Diseases of the ~~tibia~~ and fibula.

TARSUS.

1470-Congenital malformations.

1471-Luxations.

1472-Fractures.

1473-1484 Diseases.

METATARSUS AND PHALANGES.

1485-Congenital malformations.

1486-Luxations.

1487-Fractures.

1488-1499 Diseases.

JOINTS.

TEMPORO-MAXILLARY.

1500-Congenital malformations.

1501-Luxations.

1502-Fractures.

1503-1514 Diseases.

1519-1529 Vertebral joints.

1530-1544 Sterno clavicular.

1545-1559 Shoulder.

1560-1574 Elbow.

1575-1589 Wrist.

1590-1604 Metacarpal.

1605-1619 Phalangeal.

1620-1634 Sacro-iliac.

1635-1649 Hip.

1650-1664 Knee.

1665-1679 Ankle.

1680-1694 Metatarsal.

1695-1709 Phalangeal.

1710-Ligaments.

1720-Tendons.

1730-Fasciae.

1740-Bursae.

1750-Muscles.

1760-1774 Blood.

1800-Hair.

INJURIES AND DISEASES OF THE HEART
AND
PERICARDIUM.

PERICARDIUM.

2000-Abnormality.

INJURIES.

2001-Ecchymosis.

2002-Rupture.

2002-Wounds.

DISEASES.

2003-Effusions of Lymph.

2004-Adherent Pericardium.

2005-Tumors.

2006-Miscellaneous.

CIRCULATORY SYSTEM.

Heart and Arteries.

Malformation.

2007-Ectropia cordis.

2008-Single Ventricle.

2009-Closed pulmonary artery.

2010-Pulmonary artery from aorta.

2011-Communication between aorta and pulmonary artery.

2012-Open ductus arteriosus.

2013-Deficient septum ventriculorum.

2014-Open foramen ovale.

2015-Eustachian valve.

2003.1 Pericarditis; Chred
1689 Vol. 1-Pg. 1645
106
1

2003.5 Pericarditis
1704 Vol. 1-Pg. 1644
107
2

INJURIES AND DISEASES OF THE HEART
AND
PERICARDIUM.

PERICARDIUM.

2000-Abnormality.

INJURIES.

2001-Ecchymosis.

2002-Rupture.

2002-Wounds.

DISEASES.

1688-106-1 2003-Effusions of Lymph.

1690-106-1 2004-Adherent pericardium.

2005-Tumors.

2006-Miscellaneous.

CIRCULATORY SYSTEM.

Heart and Arteries.

~~1500~~ Malformation.

2007-Ectropia cordis.

2008-Single ventricle.

2009-Closed pulmonary artery.

2010-Pulmonary artery from aorta.

2011-Communication between aorta and pulmonary artery.

2012-Open ductus arteriosus.

2013-Deficient septum ventriculorum.

2014-Open foramen ovale.

1691-106-1 2015-Eutachian valve.

2015.10 Eustachian valve from an adult
1692 Vol. 1. Pg. 1645
106
1

2025.05 Hypertrophy of the heart
1697 Vol. 1-Pg. 1647
107
1

2025.10 Hypertrophied heart
1697 Vol. 1-Pg. 1649
107
1

2031.05 Aneurism of the heart, Left ventricle
1705 Vol. 1-Pg. 1655
107 Presented by D. Mütter
2

2031.10 Aneurism of the heart. Left ventricle
1706 Vol. 1. Pg. 1655
107 Presented by D. Mütter
2

2016-Transposition of aorta and pulmonary artery.

2017-Aorta given off from pulmonary artery.

2018-Abnormal vessels. See arteries.

2019-Malformation of valves. See valves.

1693-107-1 2020-Cyanosis.

HEART AND CAVITIES.

INJURIES.

2021-Ecchymosis.

2022-Rupture.

1694-107-1 2023-Wounds.

2024-Gunshot.

DISEASES OF THE SUBSTANCE OF THE HEART.

1695-107-1 2025-Hypertrophy.

2026-Atrophy.

2027-Fatty infiltration.

1700-106-2 2028-Fatty degeneration.

1701-106-2 2029-Rupture of the heart from disease.

1703-106-2 2030-Dilatation.

1702-106-2 2031-Aneurism of the heart.

2032-Fibrinous masses and coagula.

2033-Myocarditis.

2034-Fibrinous degeneration.

2035-From angina pectoris.

1698-108-1 2036-Tumors and allied morbid growths (20)
gummata.

2037-Bony formations.

2058.03 Ossification of Aortic semilunar valves
1710 Vol. 1 - Page 1659
106
3

2058.00 Ossification of semilunar valves of Aorta
1711 Vol. 1 - Page 1659
106
3 Presented by Dr. J. Neill

2058.15 Ossification of Aortic valves
1712 Vol. 1 - Pg 1659
106
3 Pres by Dr. Mütter

2058.20 Ossification of Aortic Valves
1713 Vol. 1 - Page 1659
106 Pres by Dr. Mütter
3

2058.26 Ossification of semilunar valves of Aorta
1714 Vol. 1 - Pg 1663
106
3

2060.5 Atheroma
1716 Vol. 1 - Pg. 1665
107
3

2061 (?) Aneurism of transverse and descending aorta
1717 Vol. 1 - 1665
107
3 Presented by Dr. J. L.

2061.05 Anomalous origin of arteries from Aorta
1720 Vol. 1 - Pg. 1665
108
3

2038-Tubercle.

2039-Fibrous tumors.

2040-Sarcoma.

2041-Melanotic tumors.

2042-Cancers.

2043-Cysts.

2044-Hydalids.

2045-Entozoa.

2046-Unspecified.

DISEASES OF THE VALVES AND ENDO CARDIUM.

1707-107-2 2050-Endocarditis.

2051-Papillary vegetations and deposits of fibrin on the valves.

2052-Ulceration of the valves and endo cardium.

2053-Thickening contraction and adhesion.

2054-Deposits of calcareous matter.

DISEASES OF PARTICULAR VALVES.

2055-Tricuspid valve.

2056-Pulmonary valve.

1699-108-1 2057-Mitral valve.

1709-108-2 2058-Aortic valve.

2059-Valvular aneurism.

1715-107-3 2060-Diseases of the blood vessels of the heart.

1718-107-3 2061-Arteries:malformations and anomalies.

2062-Injuries.

2063-Rupture. From external violence.

2064-From the effects of contignous inflammation.

2065.05 Ossification of Abdominal Aorta and
1721 Iliacs
108
3

2082.20 Atheroma of aorta with dilitation
1723
108
3

Pres by Dr Mütter

1719-107-3

2065-Atheroma.

EFFECTS OF THE APPLICATION OF LIGATURES
to
ARTERIES.

2066-Division of inner coats.

2067-Formation and adhesion of coagulum.

2068-Union of divided ends of arteries
ligatured in continuity.

2069-Obliteration of a portion of artery.

2070-Formation of collateral circulation.

2071-Failure of normal process ofclosure
of arteries.

2072-From disease.

2073-Religation of arteries for secondary
hemorrhage.

2074-Ligature of particular arteries in conti-
nuity.

2075-Changes in ligatures applied to arteries.

ANEURISM VARIETIES.

2076-Fusiform.

2077-Sacculated.

2078-Consecutive.

2079-Dissecting.

2080-varicose.

2081-Aneurismal varix.

ANEURISM OF PARTICULAR ARTERIES.

2082-Arch of aorta.

2083-Thoracic aorta.

2084-Abdominal aorta.

2085-Innominate.

2086-Carotid.

2087-Subclavian and axillary.

2088-Brachial and branches.

2089-Cerebral arteries.

2090-Branches of aorta.

2091-Iliac arteries.

2092-Femoral.

2093-Popliteal and branches.

SPECIMENS ILLUSTRATING THE MODE OF CURE OF ANEURISM.

2094-Spontaneous,

2095-Deposit of blood-clot or laminated fibrin

2096-after ligature of,or pressure on,an artery.

2097-Specimens illustrating the progress of aneurism.

2098-Specimens illustrating the pressure effects of aneurism.

OBLITERATION AND COMPRESSION OF ARTERIES FROM

2099-Disease of the vessel.

2100-By-pressure of enlarged glands and new growths.

2101-Rupture of aneurism into adjacent structures.

2102-Embolism.

2103-Thrombosis.

2104-Blood-clots removed from arteries.

2105-Pulmonary apoplexy.

2150-Veins.

2151-Anomalies of veins.

2152-Rupture of veins.
2153 Ligature " "

2160-Diseases of veins.

2161-Varicose veins.

2162-Haemorrhoids.

2200-Lymphatic system.

2400-Injuries and Diseases of the Nose, Mouth, Tongue, Palate and Fauces.

2401-Malformation of the various organs.

2402-Injuries of the various organs.

2403-Diseases of the nose.

2404-Polypi.

2405-Tumors of the antrum.

2406-Diseases of the lips and cheek.

2407-Diseases of the tongue.

2408-Diseases of the gums and hard palate.

2409-Epulis.

2410-Tumors.

2411-Diseases of the soft palate and fauces.

2412-Ulceration.

2413-Tumors.

2414-Foreign bodies in fauces.

2415-Diseases of the tonsils.

2416-Ulceration.

2417-Enlargement and new growths.

2418-Diseases of the teeth.

2419-Malformation of the teeth and jaws.

2420-Deformation of the teeth.

2421-Deferred shedding of the milk teeth.

2422-Effects of attrition.

2423-Absorption of fangs.

2424-Alveolar abscess.

2425-Caries.

2426-Necrosis.

2427-30-Other diseases.
2431-Odontones.

2400-Injuries and Diseases of the Nose,Mouth,
Tongue,Palate and Fauces,

2401-Malformation of the various organs.

2402-Injuries of the various organs.

2403-Diseases of the nose.

2404-Polypi.

2405-Tumors of the antrum.

2406-Diseases of the lips and cheek.

2407-Diseases of the tongue.

2408-Diseases of the gums and hard palate.

2409-Epulis.

2410-Tumors.

2411-Diseases of the soft palate and fauces.

2412-Ulceration.

2413-Tumors.

2414-Foreign bodies in fauces.

2415-Diseases of the tonsils.

2416-Ulceration.

2417-Enlargement and new growths.

2418-Diseases of the teeth.

2419-Malformation of the teeth and jaws,

2420-Germination of the teeth.

2421-Deferred shedding of the milk teeth.

2422-Effects of attrition,

2423-Absorption of fangs.

2424-Alveolar abscess,

2425-Caries,

2426-Necrosis.

2427-30-Other diseases.
2431-Odontomes.

2500-Injuries and diseases of the larynx and trachea.

2501-Malformations.

2502-Injuries.

2503-Laryngotomy and Tracheotomy.

2504-Foreign bodies in the air passages.

2505-Ossification of cartilages.

2506-Effects of inflammation.

2507-Oedema glottidis.

2508-Diphtheria.

2509-Ulceration of mucous membrane.

2510-Syphilitic.

2511-Tubercular.

2512-Stricture of the larynx.

2513-Necrosis of cartilages.

2514-Affections of the larynx as in typhoid fever.

2515-Affections of the larynx as in variola.

2516-Tumors.

2516-Lymphoma.

2517-Sarcoma.

2518-Glioma.

2519-Gumma.

2520-Tubercle.

2521-Fibroma.

2522-Keloid.

2523-Lipoma.

2524-Myxoma.

2525-Chondroma.

2526-Osteoma.

2527-Rhabdomyoma.

2528-Neuroma.

2529-Papilloma.

2530-Odenoma.

2531-Carcinoma.

2532-Epithelioma.

2533-Hydatids.

2534-Unspecified.

2550-Bronchial glands;enlarged.

2600-Injuries and diseases of the pleura mediastina, bronchi and lungs.

2601-Malformations.

2602-Injuries of the pleura and lungs.

2603-Diseases of the pleura.

2604-Effects of inflammation.

2605-Adhesions and false membranes.

2606-Thickening and induration of adhesions.

2607-Calcification of false membranes.

2608-Suppuration (empyema).

2609-Ulceration and perforation.

2610-Gangrene.

2611-Morbid growths of the pleura.

2612-Tubercle.

2613-Malignant growths.

2614-Other tumors.

2615-Hydatids.

2616-Miscellaneous.

2617-Diseases of the lungs.

2618-Apoplexy.

2619-Vesicular and subpleural emphysema.

2620-Collapse.

2621-Effects of inflammation.

2622-Acute pneumonia.

2623-Catarrhal or broncho pneumonia.

2624-Caseous pneumonia.

2625-Chronic pneumonia.

2626-Abscess.

2627-Gangrene.

2628-Specimens showing changes produced in the lungs of workmen following various occupations.

2629-Hemorrhagic infarcts.

2630-Embolic infarcts.

2631-Pyaemic infarcts.

2632-Phthisis and tubercle.

2633-Acute tuberculosis.

2634-Chronic tuberculosis.

2635-Acute phthisis.

2636-Chronic phthisis.

2637-Fibroid phthisis.

2638-Melanosis.

2639-Affect of gas poisoning

2640-Tumors of the lungs and mediastina.

2641-Sarcoma.

2642-Localized cancer.

2643-Dissemmated cancer.

2644-Cartilage in lungs.

2645-Other tumors.

2646-Entozoa in lungs.

2647-Diseases of the pulmonary arteries.

2648-Embolism.

2649-Thrombosis.

2650-Compression of pulmonary arteries and veins.

2651-Aneurism of branches of the pulmonary arteries.

2700-Diaphragm. Injuries.

2725-Tumors.

3000-Parotid tumors.

3001-Calculi in salivary ducts.

3002-Injuries and diseases of the pharynx and oesophagus.

3003-Abnormalities.

3004-Injuries of and operations on the oesophagus.

3005-Rupture and perforation.

3006-Impaction of foreign bodies in

3007-Effects of corrosive poisons.

3008-Oesophagotomy.

3009-Effects of inflammation.

3010-Effusion of lymph.

3011-Diphtheria.

3012-Ulceration.

3013-Syphilis.

3014-Simple stricture.

3015-Morbid growths.

3016-Cancer.

3017-Polypi, etc.

3028-Morbid growths in and around the oesophagus.

3029-Perforation of oesophagus by abscess, aneurism, etc.

3030-Dilatation of

3031-Post-mortem digestion.

3035-Injuries and diseases of the stomach.

3036-Abnormalities.

3037-Injuries and operations upon the stomach.

3038-Rupture.

3039-Effects of poison.

3040-Gastrostomy.

3000-Parotid tumors.

3001-Calculi in salivary ducts.

3002-Injuries and diseases of the pharynx and oesophagus.

3003-Abnormalities.

3004-Injuries of and operations on the oesophagus.

3005-Rupture and perforation.

3006-Impaction of foreign bodies in

3007-Effects of corrosive poisons.

3008-Oesophagotomy.

3009-Effects of inflammation.

3010-Effusion of lymph.

3011-Diphtheria.

3012-Ulceration.

3013-Syphilis.

3014-Simple stricture.

3015-Morbid growths.

3016-Cancer.

3017-Polypi,etc.

3028-Morbid growths in and around the oesophagus.

3029-Perforation of oesophagus by abscess, aneurism,etc.

3030-Dilatation of

3031-Post-mortem digestion.

3035-Injuries and diseases of the stomach.

3036-Abnormalities.

3037-Injuries and operations upon the stomach.

3038-Rupture.

3039-Effects of poison.

3040-Gastrostomy.

3050-Diseases of the stomach.

3051-Change of form.

3052-Pouch.

3053-Hour-glass contraction.

3054-Hemorrhagic erosion.

3055-Abnormal conditions of the mucous membrane.

3056-Hypertrophy.

3057-Contraction and thickening.

3058-Atrophy.

3059-Ulcers of the stomach.

3060-Suppuration.

3061-Cicatrization of ulcers.

3062-Stricture.

3063-Gastric and other fistulae involving the stomach.

3064-Postmortem digestion.

3065-Emphysema.

3066-Morbid growths.

3067-Polypus.

3068-Sarcoma.

3069-Cancer.

3070-Colloid cancer.

3071-Villous.

3072-Fibroid thickening.

3073-Other changes.

INJURIES AND DISEASES OF THE INTESTINES, PERITONEUM, OMENTUM AND MESENTERY.

3074-Abnormalities.

3075-Diverticulum.

3075.5. Ileocecal valve - appendix - normal.

3076-Injuries of the various structures.

3077-Operations.

3078-Effects of poisons.

3079-Foreign bodies.

3080-Faecal and recto-vesical fistulae.

3081-Abscesses opening into the intestine.

3082-Prolapsus ani.

3083-Diseases of the intestines.

3084-Dilatation.

3085-Hypertrophy of muscular coats.

3086-Hypertrophy of glands.

3087-Abnormal condition of mucous membrane.

3088-Changes in scarlet fever.

3089-Changes in typhoid fever.

3090-Cholera.

3091-Rinderpest.

3092-Ulceration of the intestine.

3093-Follicular and simple.

3094-Perforating ulcers.

3095-Perfortaing hernia.

3096-Ulceration following burns and scalds.

3097-Ulceration from faecal accumulation.

3098-Dysentery.

3099-Typhoid fever.

3100-Syphilitic ulceration.

3101-Tubercular ulceration.

3102-Diphtheritic.

3103-Simple stricture.

3104-Morbid growths.

3105-Cancer.

3106-Colloid.

3107-Polypus.

3108- Villous Tumor

3109-Hemorrhoids.

3110-Intestinal obstruction.

3111-From congenital malformations.

3112-From internal strangulation.Various causes.

3113-See Hernia.

3114-Intussusception.

3115-Volvulus.

3116-Constriction.

3117-Morbid growths.

3118-Compression.

3119-Impaction of foreign bodies or concretions.

3120-Affections of the appendix vermiformis.

3121-Substances discharged per anum.

3130 Gangrene of the vermiform appendix.

3131 appendicitis.

3132 - 3142 "

3200-Diseases of the peritoneum,omentum,and mesentery.

3201-Peritonitis and its results.

3202-Tubercle.

3203-Morbid growths.

3204-Fatty.

3205-Melanosis.

3206-Cancer.

3207-Sarcoma.

3208-Etc.

3225-Enlarged glands.
3250-Entozoa.

3300- Hernia in general. (10)

3301-Anatomy. (Actual preparations.)

3310-Hernia special.

3311-Inguinal.

3312-The sac and its coverings.

3313-Oblique inguinal.

3314-Direct inguinal.

3315-Unusual conditions associated with inguinal hernia.

3316-Hernia into vaginal process of peritoneum.

3317-Congenital hernia.

3318-Femoral hernia.

3319-Sac and its coverings.

3320-Unusual relations of the obturator artery.

3321-Umbilical hernia.

3322-Ventral hernia and mesenteric.

3323-Obturator hernia.

3324-Diaphragmatic hernia.

3325-Internal strangulations.

3326-Intussusception.

3327-Small intestine alone.

3328-Ileum into caecum.

3329-Ileum and caecum into colon.

3330-Of large intestine.

3331-Separation of antussuscepted intestine by sloughing.

3332-Volvulus.

3400-Injuries and diseases of the liver, gall-bladder and biliary ducts.

3401-Congenital additional lobe.

3402-Malformations.

3403-Injuries of (1) (2) (3)

3404-Rupture of gall-bladder.

3405-Operations on gall-bladder.

3406-Diseases of

3407-Thickening of capsule.

3408-Syphilitic gummata.

3409-Syphilitic cirrhosis.

3410-Cirrhosis.

3411-Hypertrophic cirrhosis.

3412-Acute yellow atrophy.

3413-Chronic atrophy.

3414-Fatty degeneration.

3415-Lardaceous degeneration.

3416-Abscess.

3417-Thrombosis of portal vein.

3418-Infarctus.

3419-Tumors of 1- 20

3420-Myxoma.

3421-Sarcoma.

3422-Melanotic tumors.

3423-Cancer.

3424-Naevus (Angioma).

3425-Entozoa hydatids.

3426-Other parasites.

3427-Other tumors.

3450-Diseases of the gall-bladder and biliary duct. (6)

3475-Tumors of the gall-bladder and biliary duct.

3500-Diseases of the pancreas.

3550-Salivary glands. (25)

3575-Submaxillary glands.

3600-Injuries and diseases of the spleen. (25)

3601-Anomalies.

3602-Injuries.

3603-Rupture.

3604-Diseases. Thickening.

3605-Hypertrophy.

3606-Atrophy.

3607-Changes in ague.

3608-Changes in typhoid.

3609-Lardaceous degeneration.

3610-Tubercle.

3611-Syphilis.

3612-Infarct.

3613-Abscess.

3614-Morbid growths.

3615-Lymphadenoma.

3616-Cancer.

3650-Entozoa.

3700-Injuries and diseases of the lymphatic glands and vessels.

3800-Supra-renal bodies.

3900-Injuries and diseases of the thymus and thyroid glands.

GENITO-URINARY SYSTEM.

4000-Injuries and diseases of the urethra, penis and scrotum.

4001-Malformations; spurious hermaphroditism.

4002-

4003-

INJURIES.

4010-Stricture of the urethra.

4011-Linear and annular strictures.

4012-Stricture by thickening and contraction of a

4013-considerable portion of the canal.

4014-Bridle stricture.

4015-Consequences of stricture.

4016-Dilatation of urethra.

4017-Dilatation of urethral abscess or fistula.

4020-Hypertrophy of the bladder.

4021-Dilatation of ureters and pelvis of kidney.

4025-Effects of the treatment of stricture.

4026-False passages.

4030- Diseases of the penis.

4031-Phimosis and paraphimosis.

4032-Simple and syphilitic ulceration.

4033-Morbid growths.

4040-Diseases of the scrotum.

4041-Hypertrophy and elephantiasis.

4050-Tumors.

4051-Fibro-cellular.

GENITO-URINARY SYSTEM.

4000-Injuries and diseases of the urethra,penis 1 vol 11
and scrotum,

4001-Malformations;spurious hermaphroditism.

4002-

4003-

INJURIES.

4010-Stricture of the urethra,

4011-Linear and anular strictures,

4012-Stricture by thickening and contraction
of a

4013-considerable portion of the canal.

4014-Bridle stricture,

4015-Consequences of stricture. 1 vol. 11

4016-Dilatation of urethra.

4017-Dilatation of urethral abscess of fistula. 5 vol 11

4020-Hypertrophy of the bladder. 9 vol 11

4021-Dilatation of ureters and pelvis of kidney. 5 vol 11

4025-Effects of the treatment of stricture.

4026-False passages. 13 vol 11

4030- Diseases of the penis.

4031-Phimosis and paraphimosis,

4032-Simple and syphilitic ulceration,

4033-Morbid growths, 17 vol 11

4040-Diseases of the scrotum,

4041-Hypertrophy and elephantiasis,

4050-Tumors,

4051-Fibro-cellular.

4052-Horny growths.

4053-Epithelioma.

4100-Diseases of the Prostate Gland,

4110-Hypertrophy. 17 vol II

4115-Abscess.

4120-Tubercular disease,

4125-Morbid growths.

4130-Calculi in the prostate,

4200-Injuries and Diseases of the Bladder.

4200-Malformations. 25 vol II

4205-Injuries and operations on the bladder,

4206-Rupture.

4207-Cystotomy.

4208-Lithotomy.

4209-Tapping of bladder.

4210-Diseases of the bladder.

4211-Hypertrophy.

4212-Partial dilatation or sacculation.

EFFECTS OF INFLAMMATION.

4215-Cystitis.

4216-Exudation.

4217-Abscess.

4218-Ulceration.

4219-Sloughing.

4220-Tubercular ulceration.

4221-Papilloma. Tumors of the bladder.

4222-Villous growths.

4223-Fibrous tumor.

4224-Villous sarcoma.

4225-Epithelial and medullary cancer.

4226-Calculi and other foreign bodies in bladder.

4227-Calculous deposits in the mucous membrane.

4228-Foreign bodies removed from the bladder

INJURIES AND DISEASES OF THE KIDNEYS,

THEIR PELVES AND THE URETERS.

4300-Malformations.

4301- Kidney of Infant

4302-Lobulated.

4303-Injuries and operations upon the kidneys.

4306-Rupture.

4307-Nephrorrhaphy.

4308-Nephrotomy.

4309-Nephrectomy.

4310-Nephrotithotomy.

4311-Aspiration

4312-

4313-

4314-

4315-Diseases of the kidneys and their pelves.

4316-Hypertrophy.

4317-Atrophy.

4318-Lardaceous degeneration.

4320-Inflammation and its results.

4321-Acute parenchymatous nephritis.

4322-Chronic interstitial nephritis.

4324-Suppurative nephritis and pyelitis.

4325-Scrofulous kidney.

4326-Tubercular nephritis.

4327-Tubercular disease of the ureters.

4328-Granular degeneration and perinephritis.

4329-Fatty kidney.

4330-Renal calculi and their effects.

4331-Calculi removed by operation during life.

INJURIES AND DISEASES OF THE KIDNEYS, THEIR PELVES AND THE URETERS.

1093 changed to 4300

4300-Malformations.

4301 Kidney of Infant

4302-Lobulated.

4305 Injuries and operations upon the kidneys.

4306-Rupture.

4307-Nephrorrhaphy.

4308-Nephrotomy.

4309-Nephrectomy.

4310-Nephrotithotomy.

4311-Absorbtion

4312-

4313-

4314-

4315-Diseases of the kidneys and their pelves.

4316-Hypertrophy.

4317-Atrophy.

4318-Lardaceous degeneration.

4320-Inflammation and its results.

4321-Acute parenchymatous nephritis.

4322-Chronic interstitial nephritis.

4324-Suppurative nephritis and pyelitis.

4325-Scrofulous kidney.

4326-Tubercular nephritis.

4327-Tubercular disease of the ureters.

4328-Granular degeneration and perinephritis.

4329-Fatty kidney.

4330-Renal calculi and their effects.

4331-Calculi removed by operation during life.

4332-Calculi in the kidney.

4333-Calculi impacted in the ureter.

4334-Hydronephrosis. Changes in the kidneys and ureters secondary to obstruction of the urinary passages.

4335-Pyonephrosis.

4336-Simple cysts of the kidney.

4337-Cysts in the ureter.

4338-Interstitial nephritis with cysts.

4339-Cystic degeneration.

4340-Embolic infarctus.

4341-Morbid growths.

4342-Entozoa.

4345-Distension of pelvis.

4346 " " ureter

INJURIES AND DISEASES OF THE TESTICLE AND ITS COVERINGS OF THE SPERMATIC CORD, VESICULAE SEMINALES AND VASA DEFERENTIA.

4400-Malformations.

4405-Injuries and effects of operations.

4410-Diseases of the tunica vaginalis.

4411-Hydrocele.

4412-Haematocele.

4413-

4414-

4415-Effects of inflammation.

4416-Loose bodies in the tunica vaginalis.

4417-Diseases of the testicle and epididymis.

4418-Atrophy.

4419-

4420-Effects of inflammation.

4425-Syphilitic disease.

4435-Tumors.

4436-Enchondroma.

4437-Fibrous and fibro-cystic tumors.

4438-Sarcomata.

4439-Cancers.

4440- Glioma

4441- Gumma

4442- Tubercle

4443-

4444-

4445-

4446-Cysts connected with the testicle and epididymis.

4447-Encysted hydrocele.

4448-Pedunculated bodies attached to epididymis.

4453-Diseases of the spermatic cord.

4454-Cysts.

4455-Haematocele.

4456-Hydrocele.

4457-Varicocele.

4460-Tumors.

4470-Diseases of the vesiculae seminales and vasa deferentia.

DISEASES OF THE VAGINA AND EXTERNAL ORGANS OF GENERATION IN THE FEMALE.

4500-Malformations.

4505-Hypertrophy of the clitoris and nymphae.

Tumors of the Labia and Vagina.

4510-Papilloma.

4511-Fibrous and fibro-cellular tumors.

4512-Cancer.

4513-Cysts.

4514-Urethral tumor.

4516-Polypi of the vagina.

4517-Tumors of uncertain nature.

4518-Blood-clot from the vagina.

4530-Recto-vaginal fistula.

4540-Unclassified.

DISEASES OF THE UTERUS AND ITS APPENDAGES.

4600-Laceration of cervix
4601 Hysterectomy
4602-Malformations.

4605-Displacements.

4605-Anteflexion.

4606-Retroflexion.

4607-Anteversion.

4608-Retroversion.

4609-Prolapse.

4610-Inversion.

4611-Adhesion of the uterus to the surrounding structures.

4612-Results of inflammation.

4613-Dysmenorrhoeal membrane.

4614-Pyometra,

4615-Ulceration of os and cervix.

4616-Atresia of cervix.

4617-Hypertrophy.

4618-Cysts in the cervix uteri.

4619-Chronic metritis and endometritis.

4625-Tumors and allied morbid growths.

4625-mucous polypi.

4626-Fibrous polypi.

4627-Uterine fibromyomata.

4628-Sarcomatous degeneration of fibroid.

4629-Calcareous degeneration of fibroid.

4630-Diffuse hypertrophy.

4631-Tubercle.

4632-Sarcoma.

4633-Cysto sarcoma,

4634-Cancer of cervix and body,

4635-Excision of uterus.

4650-Diseases of appendages.

4652-Cysts connected with the Fallopian tubes,

4654-Dropsy of Fallopian tubes.

4656-Hydrosalpinx.

4658-Distension.

4659-Pyosalpinx.

4660-Tubercle of Fallopian tubes.

4661-Tumors of the Fallopian tubes.

4662-Abscess in broad ligament.

4664-Fibrous tumors connected with the broad ligament.

4666-Cysts connected with the broad ligament.
4680 Ovariotomy

4700-Diseases of the ovaries.

4705-Abnormalities.

4710-Displacements.

4715-Atrophy and fibrous degeneration.

4720-Hypertrophy.

4725-Cystic tumors.

4730-Dermoid cysts.

4735-Parovarian cysts.

4740-Entozoa.

4745-Solid tumors.

4746 Sarcoma of the Ovary-
47

DISEASES OF THE OVUM AND ITS MEMBRANES.

INJURIES AND DISEASES INCIDENTAL TO GESTATION AND PARTURITION.

4800-Myxomatous disease of the chorion.

4805-Disease of the placenta.

4810-Detachment of the placenta.

2815-Abortion.

4820-Diseases of the membranes.

4825-Diseases and displacements of the umbilical cord.

4830-Missed abortion.

4835-Extra-uterine foetation.

4840-Foetation in an undeveloped uterine horn.

4845-Cancerous and other tumors complicating pregnancy.

MORBID PARTURITION.

4850-Laceration of the vagina and cervix uteri.

4855-Laceration of the perineum.

4860-Sloughing of the vagina and uterus.

4865-Vesico-vaginal fistula.

4866-Recto-vaginal fistula.

4870-Tumors obstructing or complicating.

4875-Rupture of the uterus.

4880-Inversion of the uterus.

4885-Retained and adherent placenta.

4890-Caesarian section.

4892-Craniotomy.

4895-Puerperal metritis.

4897-Abnormal presentation.

4900- Diseases of the Mammary Glands,

Abnormalities.

4910-Tumors and allied morbid growths.

4911-Simple cysts,

4912-Proliferous cysts.

4913-Sero-cystic disease (Sarcoma).

4914-Fibro adenoma.

4915-Fibro-cellular tumor.

4916-Myxoma. sarcoma. Adeno-sarcoma.

4917-Epithelioma.

4918-Scirrhous cancer.

4919-Medullary cancer.

4920-Colloid cancer.

4921-Melanotic tumor.

4922-Fibrous tumors of the nipple.

4923-Tumors of the breast of uncertain nature.

4924-Entozoa.

NERVOUS SYSTEM.

5000-Injuries and Diseases of the Brain and its Membranes,

5001-Congenital abnormalities.

5002-Brains of idiots.

5003-Brains of epileptics

5004-Brains of

5014-Brains of the insane.

5050-Brains of criminals.

5100-Injuries of the brain and their conseq-
quences.

5101-Laceration and contusion.

5102-Gunshot injuries.

5103-Hernia cerebri.

5110-Injuries of the cerebral membranes.

5111-Injuries by violence.

5112-Effusion of blood.

5113-Formation of blood cysts and false mem-
branes.

5120-Sub-dural abscess.

DISEASES OF THE CEREBRAL MEMBRANES.

5121-Effects of inflammation (Meningitis).

5122-Effusion of lymph and thickening.

5123-Tubercle.

5150-Tumors and allied morbid growths.

5151-Osseous growths.

5152-Fibrous and fibro fatty tumors.

5153-Cancer.

5154-Sarcoma.

5155-Angioma.

5156-Other tumors.

5157-Uncertain nature.

5160-Aneurism.

5175-Diseases of the Brain.

5176-Atrophy.

5177-Effusion of blood.

5178-Thrombosis.

5100-Injuries of the brain and their conse-
quences.

5101-Laceration and contusion.

5102-Gunshot injuries,

5103-Hernia cerebri.

5110-Injuries of the cerebral membranes.

5111-Injuries by violence.

5112-Effusion of blood.

5113-Formation of blood cysts and false mem-
branes,

5120-Sub-dural abscess.

DISEASES OF THE CEREBRAL MEMBRANES.

5121-Effects of inflammation (Meningitis).

5122-Effusion of lymph and thickening.

5123-Tubercle,

5150-Tumors and allied morbid growths.

5151-Osseous growths.

5152-Fibrous and fibro fatty tumors,

5153-Cancer,

5154-Sarcoma,

5155-Anglioma,

5156-Other tumors.

5157-Uncertain nature.

5160-Aneurism.

5175-Diseases of the Brain.

5176-Atrophy.

5177-Effusion of blood,

5178- Thrombosis

5179-

5180-

5181-

5182-Effects of inflammation (Cerebritis).

5183-Abscess,

5184-Softening.

5185-Tumors and allied morbid growths.

5186-Tubercular deposits.

5187-Calcareous formations,

5188-Corpora amylacea.

5189-Fibrous tumors.

5190-Fatty.

5191-Sarcoma.

5192-Cancers.

5193-Cysts,

5194-Vascular growths.

5195-Papillomata.

5196-Angeioma.

5197-Tumors of uncertain nature.

5198-Other tumors.

5199-Entozoa.

5200-Diseases of the Ventricles of the Brain and Choroid Plexus.

5201-Hydrocephalus.

5202-Injuries and diseases of the spinal cord.

5203-Audits membranes.

5204-Abnormalities of the membrane and cord.

5205-Injuries and diseases of the membranes.

5206-Effusion of blood.

5207-Effects of inflammation.

5208- (Spinal meningitis).

5209-Effusion of lymph.
5210-Tumors and allied morbid growths.

5211-Cartilagenous or bone-like plates.

5212-Fibrous tumors.

5213-Tubercle.

5214-Cancer.

5215-Sarcoma.

5216-Psammoma.

5217-Other tumors.

5300-Injuries and Diseases of the Spinal Cord.

5301-Laceration and effusion of blood.

5302-Softening.

5303-Dilatation of the central canal.

5304-Effects of pressure.

5305-Effects of inflammation.

5306-Tumors and allied morbid growths.

5300-Injuries and Diseases of the Spinal Cord.

5301-Laceration and effusion of blood.

5302-Softening.

5303-Dilatation of the central canal.

5304-Effects of pressure.

5305-Effects of inflammation.

5306-Tumors and allied morbid growths.

5400- Injuries and Diseases of the Nerves.

5401-Abnormalities of nerves.

5402-Injuries.

5403-Bulbous enlargement of the injuries.

5404-Repair of the injuries.

5405-Diseases of nerves.

5406-Atrophy.

5407-Hypertrophy.

5408-Neuritis.

5409-Tumors and allied morbid growths.

5410-Fibrous.

5411-Sarcoma.

5412-Cancer.

5400- Injuries and Diseases of the Nerves,

5401-Abnormalities of nerves.

5402-Injuries,

5403-Bulbous enlargement of the injuries,

5404-Repair of the injuries.

5405-Diseases of nerves,

5406-Atrophy,

5407-Hypertrophy.

5408-Neuritis.

5409-Tumors and allied morbid growths.

5410-Fibrous.

5411-Sarcoma.

5412-Cancer.

5500-Arthropathy.

6000- GENERAL PATHOLOGY.

6001-Hypertrophy.

6002-Hypertrophy of epithelium.

6003-Hypertrophy of epithelium toenails.

6005-Hyperastesia.

6010-Atrophy.

6020-Fatty degenuration.

6030-Calcareous degeneration.

6031-Repair of wounds.

6032-Experimental surgery of the intestine and stomach.

6040-Repair and reproduction of injured and lost parts.

6045-Wounds.

6050-Cicatrices.

6055-

6060-Effect of the continued presence of foreign bodies.

6070-Process and effects of inflammation.

6080-Increased vascularity.

6000- GENERAL PATHOLOGY.

6001-Hypertrophy.

6002-Hypertrophy of epithelium.

6003-Hypertrophy of epithelium toenails.

6005-Hyperostosis.

6010-Atrophy.

6020-Fatty degeneration.

6030-Calcareous degeneration.

6031-Rapair of wounds.

6032-Experimental surgery of the intestine and stomach.

6040-Repair and reproduction of injured and lost parts.

6045-Wounds.

6050-Cicatrices.

6055-

6060-Effect of the continued presence of foreign bodies.

6070-Process and effects of inflammation.

6080-Increased vascularity.

6090-Recent effusion of lymph.

6095-Cellulitis.

6100-Completely organized effusions of lymph.

6110-Adhesions and false membranes.

6115-Arthritis.

6120-Induration and sclerosis frominflammation.

6130-Suppuration.

6140-Ulceration.

6150-Sloughing.

6155-caries.

6160- Moist Gangrene

DEATH OF PARTS OF THE BODY.

GANGRENE AND NECROSIS.

6161-Dry gangrene.

6170-Sequestra.

6175-Process of formation of sequestra.

6210-Rheumatism affecting.

6220-Syphilis affecting.

6230-Glanders affecting.

6240-Dysentery affecting.

6250-Typhoid fever affecting.

6260-Scarlet fever affecting.

6270-Diphtheria affecting.

6280-Variola affecting.

6290-Tubercle.

TUMORS AND OTHER ALLIED MORBID GROWTHS.

6300-Lymphoma.

6310-Sarcoma.

6315-Melanotic sarcoma.

6320-Glioma.

6325 Lepra

6330-Gumma.

6340-Tubercle. ~~6340.10 Tubercular bodies lung~~

6350-Fibroma.

6355-Erectile fibroma.

6360-Keloid.

6370-Lipoma.

6380-Myxoma.

6390-Chondroma.

6400-Osteoma.

6410-Rhabdomyoma.

6420- Myoma

6430-Liomyoma.

6440-Neuroma.

6450-Papilloma (wart).

6460-Odenoma.

6470-Carcinoma.

6475-Encephaloid cancer.

6476-Medullary cancer.

6480-Epithelioma.

6490-

6500-

6510-Melanotic.

6520-Angeioma.

6530-Cysts.

6531-Cystic tumor of the neck.

6532-Cysts of the nates.

6533-Cysts of the thyroid body.

6534-Cysts of the scalp.

6535-Cysts of the ovary.

6538-Dermoid cysts.

6539-Contents of dermoid cysts.

6540-Hydatids.

6550-Hypertrophy of thyroid. Bronchocele.

6560 Tumors unspecified

7000-Teratology.

135

8000-Plaster casts and wax casts.

137

9000-Skin diseases;models.

9200-Eye diseases; models.

9200-Eye diseases; models.

141

9300-Venereal diseases;models.

10000-Corrosional preparations.

11000-Microscopic preparations,

12000-Parasites, entozoa, etc.

13000-Miscellaneous.

151

14000-Calculi.

14000-Photographs,drawings,plates,etc.

153

15000-Photographs,drawings,plates,etc.

155

16000-Materia medica.

17000-Mat. Surgery.

17000-Mat. Surgery.

18000-Books.

K3

SKELETONS.

SKULLS, ETC.

1000

1045

1635

165

169

1000.75 Foetal skeleton
Prepared and mounted by Dr. Joseph Leidy while a medical student
Presented by Dr. Joseph Leidy

Missing — 378 Sec 14 Shelf 1 Missing

379 Sec 14 Shelf 1

380 " " "
381 " " "
382 " " "
383 " " "
384 " " "
385 " " "
386 " " "
387 " " "
388 " " "

1002.05 Skeleton.
Presented by Prof. George McClellan.

1002.10 Skeleton.
Presented by Prof George McClellan 389 Sec 10 Shelf 3

1002.15 Skeleton.
Presented by Prof. George McClellan, 390 " " " "
391 " " " "

1002.20 Skeleton.
Presented by Prof. George McClellan 392 Sec 9 Shelf 3
393 " " " "
394 "

~~1005.01 A thorax~~ # 1090.59 ~~Presented by Prof George M C~~
See page 381

1000.76 - Human Foetus. History unknown. Formerly the property of Mr. Tom J. Oelbermann whose heirs asked to give the specimen to the Museum. The foetus is approx. 3 mo.
Presented by Dr. J. E. Cottrell.

417
Sec 11
Shelf 6

Skeleton - disarticulated, ~~Sac~~ Scapulae, clavicles
Humeri - ulnae & radii - ilium, ribs - axis, atlas
1st cervical vertebrae - lower maxilla - sternum.

1005.05 Portion of skeleton of man age 23 yrs in which the Epiphyses are not united
The Femur - tibia phalanges & (vertebrae) are exhibited
This specimen divided into 4 parts
950 Femur (R) showing non union of epiphyses - also epiphyses of L femur & tibia
951 Tibia (R) " " " " " " " & tibia
952 Epiphyses of two humeri - styloid process of ~~radius~~ ulna - head of radius & head of ulna
953 Phalanges showing non union of epiphyses Missing

1000.45 Foetal skeleton
1000.50 " "
1000.55 " "
1000.60 " "
1000.65 " "

Presented by Prof. George McClellan Lebanon
" " " " " " 173
" " " " " " Sebastian
" " " " " " 4 skeletons need repair

DEVELOPMENTAL SKELETONS.

1000.40.1-10 acc# 1883.R1 gm 10/21/24

1000-40 Foetal Foetal Skeletons from the second month of gestation to that of the child post partum. These skeletons are articulated by the natural ligaments.
10 specimens
Purchased. from T. V. Rohan in 1883

1001.25 (6) Foetal skeletons from the third month to the end of gestation. Disarticulated. These skeletons afford excellent opportunity for studying the epiphyses of the foetal skeleton.

1002 Articulated skeleton Purchased.
1004 Skeleton articulated by its ligaments Presented by Prof. George McClellan " " " "

FRAGMENTARY SKELETONS.

Place with skeletons

1003 on specimen same as 1005 A thorax,
Evidently re-numbered as 1005 does not appear.
old number # 353 Sec 9 Shelf 2

1005.05 Portion of the skeleton of a man age 23 years in which the epiphyses are not united. The femur, tibia, phalanges and vertebrae are exhibited.
Note
of ulna, styloid process and head of radius
952 Head of two humeri, styloid process
New No. Femur 950 Sect 11 Shelf 4
Tibia 951 " " "
~~Phalanges 952~~
Vertebrae 953 Missing

1005.10 Portion of the skeleton of a young woman, showing epiphyses.
Missing

Presented by
Dr. J. Ewing Mears.

1005.15 Missing Fragments of Indian bones found in a mound near Luray, Va.
Section 18
266 Shelf 6
Presented by Dr. Jno. B. Roberts

1005.16 Right femur, tibia and fibula; articulated.
250-0
Sec 8
Shelf 6
See Page 455

1005.17 (258) old num " " " "

175

HYRTL COLLECTION

of

SKULLS.

001- 141 1006.136 and

1006. 1006.

&

NORMAL OSTEOLOGY.

ETHMOLOGICAL SERIES.

1

1234567890

88888 1234567890

88888 1234567890

88888 1234567890

88888

88888

139 deaths

49 to 195 inclusive 177

1006.001 Praga.(Suicide).

(1) Draschtan Gottlieb,age 19,ob jure suspectarn puellae

amatac fidelltatem cyanurets lixivial mortem quaesivit.
Bohemia - Austria Hungary. He sought death by means of cyanide of Potash, because of suspicion regarding the faithfulness of his mistress.

AUSTRIA.

1006.002 Vienna (Suicide).

(2) Theodor Picher. Muhler.Kathal,age 29,by Cyanide of Potassium. A painter - Catholic.

1006.003 Jew (criminal).

(3) age 41,Died Medullark der Leber.
Died of medullary cancer of the liver

1006.004 Czech.

(4) Wenzeslaus Kral age 15. Schuster. ~~Died~~ gestorben wien allgem.

Krankenkaus. Variola.
A Bohemian. Shoemaker. Died in the General Hospital of Vienna. Small-pox.

1006.005 Moravia (suicide).

(5) Anton Mikschif,age 17. Sutrinae trio of furtum dedectum.

Laquae Mortem Sibi adscivit.
A shoemaker's apprentice. He hung himself because of a discovered theft.

SWITZERLAND.

1006.006 Cretin (Schweiz.) Great Rarity.

(6) Canton Wallis,Martigny. Von Dr.Mastalier.Siou.

1006.007 Cretin (Schweiz.) Great Rarity.

7 Canton Graubündten,Desentis.

1006.008 Svizzera Canton di Lefsino) Ariolo.

8 Soligo Domenico Muratore age 48.

Nosocono Vienn.Diphtheritis 1872 v Dr.Zucker

HOLLAND.

1006.009 Amsterdam (Suicide).

9 Mann v Dr.Zuckerk.

1006.010 Amsterdam (Suicide.)

10 defsen Frau v Dr.Zuckerk.

Persistent frontal suture. Dutch woman

1006.011 HUNGARIA et partes adnexac.

Magyar. Sziklos.(Murderer executed.)

11 Ladislaus Pop. ans Harom szek.

Transylvania.Reform. Guerilla in Deserewr.

Standrechtlick. Gehenkt in Arad.Dr.Don.Dengull.

1006.012 Marmarosch. (Suicide)

Gera Virmengi.Hirt age 80. Reformist (Szigeth). Septua-

12 ges aetatis anno vulmere jugulo inflicto mortem quoesi-

vit vulnus,ob laryngeao ossifacitam non lethale erat.

Superftite fistula laryngea ad 80 usque annum vixit,ab-

sque,Melancholia, Herdsman. In the seventieth year of age, he attempted a suicide by cutting his throat, the wound was not fatal because of an ossified larynx. A laryngeal fistula remained. He lived right on to his 80th year without melancholia.

1006.013 Magyar (Kaschaw).

13 Tosko Sollésk. Ho ed aess Kaschaw,age 28. Reformist,

Died Pneumonia.

1006.014 Zips (Suicide). Süde abhangden Beskiden.

14 Tulius Fárkás age 34. Soldat,Protestant aus Kásmark

nord-Ungarn.

Selbstmörder, ans Lebensüberdruss Schuysdwrchs Herz.
Hungaria Southern slope of the Beskids. Soldier-Protestant. From Kaschmark north Hungary. Shot himself in heart while despondent.

1006.015 Haiduk, aus Borog in Ungarn soldat.

15 From Hajuk - a soldier 21 years old. Committed suicide

1006.016 Slavonien. 64 Slavonia-Austria-Hungary

16 Tlia Dimitrovies age 34.
Ilia Dimitronics - 34 years of age

Führer ino I Baranter-Grenyregiment ans Glina. Died
Leader in the 1st Banat Frontier Regiment from Glina (Croatia-Austria-Hungary)

Fract complic im Josephinum.
Died of complicated fractures in the Josephinum.

1006.017 Croatia (Agram). 65

17 Paul S age 24.

Mixed race Mutter Dentsch and Vater Croak.
Mother-German. Father Croat

BUKOUINA.

1006.018 Zigeuner (Gipsy). 66

18 George Kretzu age 24, ans Kapu-Kimpolong inder Bokowina.

v Prof. Rektorizik in Lemberg.
A Gipsy, George Kretzu, 24 years of age. From Kimpolung, Bukowina, Austria-Hungary.

RUTHENIA.

1006.019 Ruthene. (Anomalia dentitionis). 67

19 Dormarsk Fedko age 12. Prof. Rektorizik.
A Ruthenian. Anomaly of dentition, Dormarsk Fedko, 12 years of age.

1006.020 Ruthene. (Suicide) 68

20 Mandsink Takob, age 62.

There is a fissure in the temporal side of the frontal process of the molar bone.

POLONIA.

1006.021 Lithauren. 69

21 Maria Lipinska, age 17.

Died in Witepsk. Variola. Dr. Szaszinski.

1006.022 Gallizia (Suicide.) 70

22 Waszkiswicz Adolf, age 26. Soldat.

1006.023 Polonus, (Suicide). 71

23 Adalbert Czaptieonez, age 51. cath "Lapol in Gallicia"

ob. summam revum penuviam jugulum. Sibi proecidit.

Prof. Rektorzki.

Cuts his throat because of extreme poverty.

1006.024 Gallizia (Sambor).

24 Muszyknwier Ferdinand, age 42.

Died Tuberkulose pulmonalis. Schulfe. Height 5'3"4'''

1006.025 Gallizia (Lepolis).

25 Rakity Martin, age 30.

Died Apoplexia cerebri.

TURKIA.

1006.026 Serbe. Chokaze. Murderer (executed.)

26 Milan Toanovitz. Festungssträfling in Belgrad v Dr. Ulasies.

Catholic - age 30 - Robber

1006.027 Rumäne.

27 Vasili Draganu, age 23. Soldat ans Giurgevo. Gviech-

orient.conf. Died Bukwrest Typhus. v Dr.Davila.

A Rouman, Vasili Draganu. Giurgevo (A town in Roumania) Greek-oriental creed (Orthodox - Eastern Church) Soldier, 23 years of age. Died in Bucharest (Roumania) Typhus. From Director Davilia.

1006.028 Baschi Bozuk. Kurdistan. Great Rarity.

24 Died Silistria (Bulgaria) from wounds 1856. v Dr.Castro, Philippopolis. Kurde

1006.029 Montenegro. Cernagora. Great Rarity.

29 Davilo Miladovie, ans Trebinje--

Died Antivari, Schuyswunde. v Dr.Matcovich, Budua.

Died from gunshot wounds

1006.030 Maronite Libanon. Great rarity.

30 Abou Ebu.Djeb. Kawasse ans Öst consulat in Beyrut

Syrien. v.Dr.Villasecca, Symria.

1006.031 Zigeuner. (Moldan) Gipsy

31 Tóu Bargaunŭ Tassy, age 31 v.Dr.L.Russ. a Gipsy

RUSSIA.

1006.032 Finnland.

32 Agapit Loren ans Nystad Matrose. v.Dr.Wittolf.Abo. a sailor

1006.033 Ural. (Mountainous region of Siberia)

Tedor Pratinuff Soldat, age 35.

33 Relig-groeco-orient, ans ekaterinburg. West Siberien, v.Dr.Uwaroff.

1006.034 Krimea. Great Rarity.

Olug Kara Dagh, ans Teni-Kali.

34 v.Dr.Dombruski. Teodosia.

Complete synostoses with corination.

1006.035 Scopzi. Russia Great Rarity.

35 Andryew Sokoloff. Neschnei-Novgood, V.Dr.Peters.Archiatria. Self mutilation, extirptestum.

1006.036 VOLHYNIA.Shitomyr, (Murderer executed). Russia

36 Kusimir Ostrowosezynski, age 30, Miles tegionis Fsmailoff. ob grave insubordinationis delictum erudelifsimae flagellorum roenal succubnit v.Dr.Peters.Potoeki.

1006.037 Podolia ans Mohelew. (Suicide)

37 Moderately microcephalic. Teophil Lamorski Soldat, age25.
From Mohilev, Podolia (Russia)
Teophil Laworski, a soldier - 25 years of age. a Suicide.

KAWKASUS.

1006.038 Kabardine (Moslin). Great Rarity,

v.Dr. Olonieff in Tiflis.

38 Deformity due to premature disappearance of coronal suture.

SIAM.

1006.039 Pirate (Murderer executed). Great Rarity.

Rai- Tao- Si. Siamensis, criminum atrocia famosus cum

39 deecm socus a Batavis captus,et in castello Samarang

laqueo suspensus.

v.Prof. Lugdunesi. Van der Hoever.
A famous Siamese criminal, guilty of many atrocious crimes. Captured with ten of his band at Batavia. Hung in the Castle of Samarang.

AEGYPTEN.

1006.040 Aus den King-tombs. Great Rarity.

v. Sakkareth,Count Chambord with hand and foot.

40

ITALIA.

1006.041 Aquileja.

41 Domenico Vanello,operaje,age 50.

Died Venezia. Ascites v.D.Vignola.
Austria Aquileja (a town at the head of the Adriatic) Died in Venice Ascites.

1006.042 Lusin grande. Isola deb Guarnero.

42 Marianna Corti Catho,age 23.

Died Tiume Telno puerperolis v.Dr.Tiraboschi 1869.
Lusin-Grande-Guarnero-Island (Adriatic Sea) Marianna Coti, Catholic, 23 years of age - maid-servant Died at Fiume, Puerperal Fever.

1006.043 Bergamo. (Northern Italy)

43 Andrea Dolabella. Eisenbahn-Arbeiter. Catho,age 32.

Died Spitale der Barmherzigen Wien,Pyaemia.
Andrea Dolabella - railway labourer, Catholic - 32 years old. Died in Charity Hospital, Vienna - Septic infection and complicated fracture.

1006.044 Piemonte.

44 Alfonso Vallese,age 23,aus Avsta cathol,Bersagl'ere.

Died Alexandria 1860 Schutswande. v.Dr.Luchesini,

Alexandria.
Alfonso Vallese from Aosta (Northern Italy): Catholic; sharpshooter; Died at Alexandria 1860. gunshotwound.

1006.045 Albenga, Riviera di Ponente Sardegna.Great Rarity.

45 Antonio Mazzarei Marinajo cath. 93 SRC 3 55

Died Nello Spedale di Genoa. Dysenteria v.Dr.Roncati.
Albenga, West Coast of Sardinia, Antonio Mazzarei: seaman, Catholic; Died in Genoa Hospital; Dysentery

1006.046 Terracina (Murderer executed). Great Rarity.

46 Guilo Tombolain,Brigante,age 28. 94 SRC 3 55

Died nello prigioni di Gaëta.v.Dr. Bomba.
Terracina (in the Province of Rome, Italy)
Guilo Tombalini: a brigand. 28 years of age. Died in the prison of Gaeta (in the Province of Caserta, Italy) Executed for murder.

1006.047 Ragusa.

47 Gianbattesta Marzoni Marinjo,age 37. 95 SRC 3 55

Spedale di Sau Spir,Vew.v.Dr. Posarelli.
Ragusa (difficult to say whether Ragusa, Sicily or Ragusa, Dalmatia is meant) Gianbattista Marzoni - a seaman of 37 years of age. Hospital of the Holy Spirit, Venice.

1006.048 Calabria (Murdered executed). 96 SRC 3 55

48 Alessandro Zuccarella,Banditto. v.Dr.Bomba,1864.
A bandit. A publisecuritatis custodibus armatis, in aprutiis glande plumbea mactus.

CHINA.

1006.049 Hong-Kong. (Murderer executed). Great Rarity.

49 v.Dr. Scherzer. 97 SRC 3 55

JAPAN.

1006.050 Teddo (Tokio). 98 SRC 3 55

50 v.Dr. Bandonin.

GRAECIA.

1006.051 Isola Brazza.(Colonia graeca).

51 v.Dr. Cafutovich. Spalato. 99 SRC 1 56
Brazza Island (in Adriatic Sea, forming part of Dalmatia, Austria-Hungary) Greek Colony. Gift of Dr. Castulovich, Spalato, Dalmatia.

1006.052 Zakyanthos. Great Rarity.

52 Athanas Zalmis,Mozzo,age 24. 100 SRC 1 56

Microceph,Died Porte-Re,Phthisis.

Abscess cavity in left side of hand palati,communicating with a retained cleutal root.

1006.053 Cephalonia. Great Rarity.

53 Ettore Malinpieris,Marinjo.

Died Zara. Fract. Column. Vertebr.v.Dr.Cantana,1869.
A seaman from Cephalonia (largest of the Ionian Islands, Greece) Died in Zara (Capital of Dalmatia, Austria-Hungary) Fracture of the Vertebral column.

1006.054 Candia. (Most populous city of the Island of Crete) Great Rarity.

Spiridion Parikakis Matrose.

54 Died Venedig-Typhus,1868.

1006.055 Morea. (Murderer executed).

55 Dionys Kalergis. Armyro in Griechenland. v.Dr.Aphanidis, Athens.
Highwayman shot by gendarmes.

1006.056 Hydriot. Great Rarity.

56 Sosthenes Timarchis. Matrose aus Hydra. Died Triest Cholera. A sailor.

1006.057 Corfu.

57 Timothi Castriotis. Sepercargo.

Pugnalato in Scutari v.Dr. Matcovich.
Died of a dagger thrust in Scutari (principal city of Abania European Turkey)

ARMENIA.

1006.058 Armenisches. Mädchen.

58 Mirka Maguran age 8.

Bukowina,Sereth v.Dr. Deakonowuz.
Armenian maiden

1006.059 Vienna (famosa).

59 Francisca Seycora,age 19.

Died nosocomio generali. Meningitis.

1006.060- Vienna (mas).

60 Carl Spanner, age 16, a Viennese

Died nosocomis generali, Tuberculosis.

1006.063- Vienna (Suicide).
1006.063

Schwerger Toh, age 16.

wegan eines entdeckt. Diebstahli. Donan.
John Schweiger. 16 years of age. A suicide because of a discovered theft. Danube.

1006.061- Austria (inferior). Suicide.
1006.061

62 Brawn Franz, age 13. Unter-Gänscerndorf. dwich erhängen,

eines eutdeckten. Diebstahli wegan.
Lower Austria. Franz Braun: 13 years of age. Unter-Ganserndorf (in the Duchy of Lower Austria) A suicide by hanging himself because of discovered theft.

1006.062- Austria (superior). Suicide.
1006.062

63 Füher Simon, age 19, aus Linz. Schnieder.

Erkenkt, aus unglückt. Liebe.
Upper Austria, Füher Simon: 19 years of age. From Linz (Capital of the Duchy of Upper Austria). A tailor. Suicide. Hung himself because of an unhappy love affair.

1006.064- Cretin.

64 Kirchberg aus Wechsel, angeblich, age 17.

Synostosis praecox suturoe coronarioe.
A Cretin. Kirchberg in the Wechsel (the Wechsel is a group of mountains forming part of the Styrian Nieder Alpen in the Duchy of Styria, Austria) Nominally 17 years of age (it is claimed that he is 17 years old. Premature ossification of the coronal suture.

1006.065- Saltzburg.

65 Heinz Mich. Müller, age 37.

Twengin im Lungaw. Herzogthum. Died Tuberkulose.
Twengin im Lungau (a district) Duchy of Salzburg (Austria) Heinz, Michael; a miller, 37 years of age. Died of Tuberculosis.

1006.066- Pinzgaw. (Zell am See).

66 Donat Joseph, age 30. Bräuer

Died Lungenödem.
Pinzgau (a district in the Duchy of Salzburg (Austria) Zell am See (a department in Salzburg (Austria) Donat, Joseph, 30 years of age. a brewer. Died of ~~Lodema~~ of the lungs.

1006.067- Tyrol. (ober Tunthal, Platten).

67 Maria Falkensteiner, age 26, mag.

Died meningitis. A woman servant.

195

1006.068 Silesia.

68 Tunscher Franz, age 40. 116 Sec 3 56

Deutsch Kowitz-eisenbah-Arbeiter.

Died Barmherz Spital Iramma.
Railroad laborer. Died in the Charity Hospital. Iraumna

1006.069 Magyar, (murderer executed). 117 Sec 3 56

69 Geysa Fekete de Galantha, age 40.

Hussar. Deserteur. Guerilla aus Nagy-Banya.

Died Munkaeo, durch den Strang.
Hungarian Geysa Fekete de Galancha, a Hussar, deserter, insurgent 40 years of age. From Nagy-Banya (Hungary) Calvanistic Religion. Died at Munkacs (Berg County Hungary) by means of the halter.

1006.070 Magyar, (murderer executed). 118 Sec 3 56

70 Ladislaus Czaky, age 23 Räuber.

Standrechtlich gehenkt in Arad.

Persistent frontal suture.

1006.071 Kumania. 119 Sec 1 57

71 Vilmos Szabó, age 35. Tisza Füred Hussar. Died Militär sp al Wien.
Hussar. Died in the Military Hospital of Vienna.

1006.072 Tazyge. 120 Sec 1 57

72 Koloman Ergetty aus Tasz-apaty, age 21 Hussar.

Died Typhus.

1006.073 Slowak. (Suicide) 121 Sec 1 57

73 Grego Kubin, age 38, ausBobiov in der Arva. Testunys-Sträfäng. Erhenkt. Donum Dom. Praschil Doctoris Comaromiense Calvinist. Committed suicide by hanging.

1006.074 Arva, (Sudabhang der Karpathen.) 122 Sec 1 57

74 Gregor, Bipnik, age 15. Topfsbricker aus Nameszto in Arvaer, comitat.

Died Wien, bei den Bramherzign, Tuberculosis.
Arva (Southern portion of the Carpathians)

1006.074 Wallache. (Transylvania). 123 Grc 1 57

75 Triffo Mirko, age 50. Segetvar.

1006.075 Saxvio, (Transylvania). 124 Grc 1 57

76 Siebenbürger Sachse aus Stolzenburg, age 36.

Taglöhner. Died Delirium Tremens.
Day laborer

1006.076 Croat. 125 Grc 1 57

77 Drajio Paul, age 24, aus Oriovaez.

Persistent frontal suture.

1006.078 Bukowina (Murderer executed.) 126 Grc 1 57

78 Morja Aslan, age 18, crimin.

1006.079 Czech. 127 Grc 2 57

79 Wenzel Přichoda, age 25.

Rakowitz, Schuster. Died Hernia, incarcerata.

1006.080 Czech (Madhouse.) 128 Grc 2 57

80 Dostal Tohan, auschrudim, age 17.

Blödsinn. Hydrocephalus.

1006.081 Gallizia. 129 Grc 2 57

81 Kostial Isidor, age 46 aus Tarnelinon.

Died Phlebitis Fract. Compound femories.

1006.082 Krakuse, (Murderer executed.) 130 Grc 2 57

82 Roman Tasinski, age 26 ausMyslenice Hängegendarm. Gehenkt

in Kamienseo Geschenk Von Reg dezt Dr. Stroganofski.
from the regimental surgeon.

1006.083 Gorale. 131 Grc 2 57 Great Rarity.

83 Stanislaus stara, age 43 aus Lopuezna in der Tatra

Trainsoldat. Died Schufswunde.
Died of gunshot wounds.

1006.084- Hanak. Sec 3 57

84 Toh. Samek, age 25. Adischan. 132

Died Typhus.

1006.085- Wende, Unter Steier.

Magdal Pagrae, age 23. Magi

85 Died Kindbettfieber alle em Krankenhan. 133 Sec 2 57

Large palatal hyperostosis.
Died of puerperal sepsis.

1006.086- Krain.

86 Maria Pogatschnik, age 48, aus Dobege. 134 Sec 3 57

v.Dr.Schrolt Sabaeensis. Spital der Barmherzigkeit in Wien.

1006.087- Carniolia (Gottschee.)

87 George Prasnig, age 19. Died Variola. 135 Sec 3 57
Spital der Barmherzigkeit in Wien

1006.088- Dalmatia (Morlacca.)

88 Catharina Dunich, age 19. 136 Sec 3 57

District Sebenico Skardona.

v.Dr.Castulovis.

1006.089- Isola Brazza, (Colonia Greča). 137 Sec 3 57

89 Don Tozzo, age 29. Marinajo. v.Dr.Usarevoch.
a sailor

FOREIGN SKULLS.

1006.090- Serbe (Murderer executed). 138 Sec 3 57

Constantin Tacie, age 24. R. ü M. aus Moravieza.

90 Standrechtlich Jehenkt. Robber + Murderer

1006.091- Bosnia, (~~Murderer executed~~). Sec 3 57

91 v.Dr. Georgevies Dalmat. 139

Stender Assim, A Mohammedan Robber. Killed in battle with the Austrian sharpshooters at Jaiza.

1006.092 Uskoke. Great Rarity.

Esim Kowo-Kowonaez aus Banjaluka. 140 Sec 1 58

92 Turkisch Bosnia v.Dr. Georgevies 1867.

Right half of corona disappeared; also Right quamoso-sphenoidal: small Spar. tubera.

1006.093 Dobrudscha, (Babadagh). Sec 1 58

93 Cyril Vranija, age 13. Schiffsjunge. Died Hospital Braila, Cholera. 141 Cabin boy. From Philippesco, a medical student.

1006.094 Bulgaria. Sec 1 58

94 Wolumir Dragan Schiffknecht. 142

Died Cholera Varna v.Dr. Breuner.

1006.095- Wallachia,

95 Constantin Anesku, age 32 Soldat aus Giurgews, Died Bukarest. Schuswunde. v.Drs. Davila, 1859. 143 Sec 1 58

Died of gunshot wounds.

1006.096 Rumania.

Demeter Prunkul, age 25. 144 Sec 1 58

96 Syrmouest in der Moldaw. v.Drs. Kozel.

Very heavy hypensh of m at palate were forward tempridges very high.

1006.097 Albania (Chipetar. Delwina.) 145 Sec 1 58 Great Rarity.

97 Von Dr. Agutti reus Consulates-Dolmetsch in Janina.

1006.098 Gipsy, (Moldwia). 146 Sec 1 58 Great Rarity.

98 Vasilie Buzdugan, age 37.

1006.099- Armenia (Exzeroum.) Great Rarity.

Ohanes Amos Stullian,Lextor,age 29.

Died in nosocomio austriaco Constantinopolitano Phthisis.

A.Prof. Claris. Riegler,ExScola Medica Galata Serai.

Armenier

1006.100- Rusniak. Russia

Fejka Tisany,Greuzjoeger,age 52. Griech,unvit aus

Unghvar.

A grenadier with the Greek unit from Ungvar

1006.101- Kosak,(Donischer). Russia

Alexis Bugimeloff aus Nowo-Tfcherkask,

v.Dr. Pertfef in Kiew.

1006.102- Kasan. Russia

Alexandra,Konopelkina,age 20.

v.A.Clarip Prof. Sefshaft.

1006.103- Ruthene.

Romanov. Prasezak,age 21. Pultawa.

Died Charkow Cholera,v.Dr. Parisi,

1006.Q104- Tscheremisseu-Grabe. Great Rarity,

Aus cinem alt-heidnischen,

Kostroma Russland.

v.Prof. Retzini.

1006.105- Tschnisafchen-Grabe. Great Rarity.

Aus cinem in Alatyr,Gonvernement,

Simbrisk.

Von.Prof. Retyines.

1006.106- Tablunka.

Gregor Kostial,age 22. Protest Soldat.

Saipusch. Nörde abhang der Karpathen.

Died Josephinum. Typhus.

1006.107- Boechedi Cattaro. 155 Sec 3 S 8

Tremendously long styloid process.

167

1006.108- Parma. 156 Sec 3 S 8

168 Marcantonio Marinelli, age, 14, Vetturino.

Died Veruno, post-amputat femoris of fracturam complicatum.

v.Dr. Brunelli.

1006.109- Tudicaria. 157 Sec 3 S 8

Maria Bertoloni, age 18. Mas° aus Stenico Kreis Roveredo.

169 Died Alle Laste, Trento. Metritis puerpseralis.

v.Dr. Brunelli.

1006.110- Sicilia. 158 Sec 3 S 8

110 Bartolomeo Pizzacane. Barcariolo, age 18.

Died nello Spedale di Palermo. Tumor, abbai.

v.Prof. Manfredi.

Large parietal foramina.

1006.111- Roma. 159 Sec 3 S 8

111 Angelo Gioppi, Facchino, age 60.

Died Hydrothorax Spedale di Sto Spireto.

v.Dr. Fiorelli Bologna. Scaphocephalus

1006.112- Napoli. 160 Sec 1 S 9

112 Gennaro Trompelta, age 13.

1006.113- Genua. 161 Sec 1 S 9

113 Männlich, age 15-17.

v.Verani in Nizza.

1006.114- Elba,(Porto-Ferrajo). 162 Sec 1 59

Gianbattista Tozzi. Sbirro,age 24.

114

Died Forienzo coltellata v.Dr.Brunelli.

Skull Heavy,very high pal.aest.

Elba (Island off the west coast of Italy belonging to province of Leghorn) Porto-Ferrajo - (Capital of Elba)
Gianbattista Tozzi, policeman, 24 years of age. Died at Florence (Italy) Stab wound

1006.115- Cavalese,(Lateiner). 163 Sec 1 59

Vincenzo Toniotti,age 15.

115

Died in hospital of tuberculosis.

Railroad laborer,

1006.116- Ravenna. 164 Sec 1 59

Marietta Grinaldi,age 20.

116

Ricamatrice in Seta.

Died in Arco. Phthisis.V.Dr.Brunelli.

Ravenna (capital of Ravenna province, Italy) Marietta Grinaldi embroderer in silk, 20 years of age. Died in Arco (arco is a town in Spain, but Arcola, a village 16 miles South east of Verona, is probably here intended.

1006.117- Malta. 165 Sec 1 59

Ercole Pisani Sarto,age 42.

117

Died Dysenteria.V.Dr. Senjna La. Valetta. (the capital of the Island of Malta)

Persistent frontal suture.

1006.118- Friule. A district at the head of the Adriatic Sea, divided between Italy and Austria, the Italian portion being in the province of Udine and the district of Grado. Gruaro and the Austrian Comprising the province of Gorz + Gradeska + the socalled Idrian district.

118 Sudovico Lesana,age 30 aus Grado.

Died hospital Barnherzigen in Wien Pneumonia.

1006.119- Lombardo,(Varese). 167 Sec 2 59

119 Petrian Francesco,age 21. Maurer St.Martina Superiore.

1006.120- Istria,(Trieste). Istria (margraviate & crownland of Austria Trieste (is not in Istria but forms with its adjoining territory of 36 sq. miles, a separate Austrian crownland

120 Girolamo Zini. Funambolo,age 20.
Rope - walker

V.Dr. Alimonda.

Luxation of atlas

1006.121 Valsugana,(Sud-Tyrol). 169 Sec 2 59

121 Andra Daverio aus Borgo di Valsugna,age 24.

Died Pyaemia. Southern Tyrol (Austria)
Valsugana is a valley east of Trent, the capital of southern Tyrol
Stone mason.

1006.122 Libanon(Druse)Murderer executed. Great Rarity.

122 Tzzet Metheno Fakhr. Libanon Gekopft in Deit et Kamar

V.Dr. Kotschy. 170 Sec 2 59
The Druses are a religious sect inhabiting mid-Syria. They are a mixture of refugee stocks in which the Arab largely predominates.
A robber. Beheaded in Deirel Kamar (a town in Lebanon)

1006.123 Arnaut,(Ianica). Great Rarity.

123 Abdulla Kiri Aga. Albanien. 171 Sec 2 59

V.Dr. Krissakis,Dwrazzo.
Abdulla Kiri Aga.
Arnaut (a Turkish word meaning Albanian)
Albania (European Turkey)
Durazzo (a sea port town of Albania.

1006.124 Kaukasus,(Tfchetschenze). 172 Sec 2 59

124 Koumo Naib Abrek,aus Unézapnaia-Kriepost.

V.Dr. Kubrinski.

1006.125 Kaukasus,(Daghestan).

125 Ismage Kowra Atzin aus Salté in Daghestan. 173 Sec 2 59

V.Dr. Kubinski.

1006.126 Zagrebin. 174 Sec 3 59

126 Eva Radié,age 21.Mago,cathol. servant

1006.127 Türk. (Grab in Semendria) 175 Sec 3 59 Great Rarity.

127 V.Dr. Joanoviz.
From a grave in Semendria, capital of Smedorevo Department Servia.

1006.128 Aegyptan.(Mumie) Thebes. 176 Sec 3 59

128

1006.129 Aus den Catacomben. 177 Sec 3 59

129 v.St.Stephan.

"Stolen by myself. Skull of a Canonicus."

1006.130- Zigeuner. 178 Sec 3 59

130 Peter Lukács, age 24.
a Gipsy

1006.131 Scharka (Böhmen) Suicide.

131 Wenzel Franta, age 25. 179 Sec 3 59

1006.132 Ragusa, (Dalm) (Austria-Hungary) Sec 1 59

132 Guiseppe Zadro, age 28.

1006.133 Lissa (~~Idiot~~, The Island of Lissa, forming part of Dalmatia (Austria is probably referred to, but there is also a town in Bohemia called Lissa. 181 59

133 Orazio Trani, age 39. Idiot

1006.134 Croatien, (Agram) Sec 1

134 Iovan Dragie, age 21. 182 59

Persistent frontal suture.

1006.135 Meseritsch. Mähren. Sec 1

135 Barbara Andrasck, age 20. 183 59

1006.136 Salzburg. (Unken) ("Murderer executed")

136 Veronica Huber, age 18. 184 Sec 1
Executed for the murder of her illegitimate child. 9

1006.137 Belgrad. (Festungsträfling).

137 Step Milanovič, age 24. 185 Sec 1
Culprit confined in a fortress. Died there. 59

1006.138 Gaming Steierm. 186 Sec 1

138 Toh, Pfab, age 48. 59

1006.139- Galizien, Kolomea. Galicia (Austria Hungary) Sec 2 59

139 Iwan Antoniewiez, age 26.

1006.140- Chinese. Sacramento - California Sec 2 May 1872

140 Presented by Dr. T. M. Logan. 59

1006.141 Indian, (Flat Head). 189 Sec 2 59

141 Presented by Dr. J. Ewing Mears.

1006.142 Skull of a Peruvian. 190 Sec 2 59

142 Presented by Dr.J.Ewing Mears.

1006.143 Skull of a native of the Sandwich Islands.

143 191 Sec 2 59

Presented by Dr.J.Ewing Mears.

1006.144 Normal Caucasian skull. 192 Sec 2 59

144 Presented by Dr.J.Ewing Mears.

1006.145 Normal Caucasian skull. 193 Sec 2 59

145 Presented by Dr.J.Ewing Mears.

1006.146 Negro skull. 194 Sec 3 59

146 Skull of a negro woman about twenty years old. Woman small and full-blooded.

Purchased.

1006.147 Irish skull;adult male. 195 Sec 3 59

no 438 Sec 3 147 shelf 9.

Purchased.

1006.15 Crow Indian Skull
Found at the Old Crow Agency, Crow Reservation, Montana.
Presented by Prof. George McClellan

1006.50 Neanderthal Skull (Plastercast) see filing card

1006.51 Neanderthal Skull Facsimile cast " "

1006.52 Interior of the brain cavity of the Neanderthal Skull see filing card see history with specimen

For 1006.53 see Page 216

1006.72 Skull without mandible or calvarium - No identification

1006.73 Skull, no inferior maxilla No identification

1006.74 Skull of a German killed by a buck in Baltimore in a riot in 1839. Fracture.

1006.75 Skull No Calvarium or inferior maxilla.

1006.76 Skull. Extensive fracture.

1006.77 Rebel skull - killed in the 1st Battle of Bull Run, from Dr. J. P. Richarson, 82nd P.V.

1006.78 Skull; no inferior maxilla.

1006.79 Skull - " " " "

1006.80 Skull - no inferior maxilla.

1006.81 Skull - no inferior maxilla.

1006.82 Skull - no inferior maxilla (fracture?)

1006.83 Skull - " " " "

1006.84 Skull of a child

1006.85 Skull of a child

1006.86 Skull of a child

1006.87 Skull of a child

1006.88 Foetal skull - 6th or 7th month.
No further identification for the specimens listed on this page.

1006.248 Skull - ~~No identification~~ "Sioux, Indian Prisoner. Died at Rock Island." written on squamous portion of temporal bone.
#39

1006.249 Skull - no identification.
#40 -

48 skulls. 1 to 47 inclusive

1006.200 to 1006.247 incl.

* Indian Skulls from Burial Mounds in Illinois near St.Louis, Missouri and Geneva Lake, Wisconsin.

Sixty Indian skulls from these localities have recently been presented by Dr.S.Weir Mitchell to the Museum. They were given to Dr.Mitchell by Dr.George J. Engelmann, who, together with Dr. Adolphus Wislizenus, brought them to light. Nearly all the skulls are from cysts near French Village, Illinois, eight miles southeast of St. Louis. They were from single graves, almost invariably located on small spurs or prominent points at the very edge of the bluff facing St.Louis and about seven miles from the river bank. The bones were evidently placed in the cyst at a depth of two or three feet after decay of the flesh, for the skulls bear marks of the teeth of rodents. Some of these cysts were lined with flat pieces of lime-stone.

Seven of the skulls were from the Big Mound in St.Louis (after which the City was named, the "Mound City".) This mound is now completely leveled. The bones were found as isolated burials scattered through this great mound without any regularity, some of them far beneath the surface.

1006.53 Cast of skull and femur of Pithecanthropus Erectus (Trinil man). Scientifically accurate cast of the most ancient known human remains, found by Du Bois on the banks of the Solo River in Central Java in 1891. Though neither their age has been definitely ascertained (having been found in river gravel) nor their human nature admitted by all, it is generally accepted that they represent a human variety of lower Pleistocene age. It is interesting that the femur shows bony exostosis which may be neoplastic and are certainly pathological.

Committee on College Collections.

This is a possession of the College. Presented by Dr. E. B. Krumbhaar, Dec. 6, 1933

See College Collections Misc. No. 995

1006.54 Casts of skull and mandible fragments and tooth of Eoanthropus (Piltdown man) Six pieces. These were found in the Piltdown (Sussex) gravels in 1912 by Charles Dawson. Their dark color is due to impregnation with mineral salts. The geologic surroundings, the angle of the chin, the estimated brain capacity (slightly larger than Pithecanthropus) and the tooth structure, indicate that these are also of lower Pleistocene period and one of the earliest of human remains. Professor Osborn thinks that they are related to the Cromer flints and of Pliocene antiquity.

Committee on College Collections.

These are possessions of the College. Presented by Dr. E. B. Krumbhaar, Dec. 6, 1933.

See College Collections Misc. No - 996

1006.55 Plaster models prepared by R. F. Damon, of the South Kensington Museums, London, of the complete brain case of the Sinanthropus pekinensis (#553) and of the left lower molar (#510) on which the genus was founded in 1927.

Committee on College Collections.

These were colored by hand by Dr. Schenck, Curator of the Mütter Museum, and presented to the College Collections as companion pieces of the Pithecanthropus erectus skull cap and femur and of the Piltdown skull bones, mandible and canine tooth.

These are possessions of the College. Presented by Dr. E. B. Krumbhaar, 1935

See College Collections Misc. No. 997

These three exhibits were given Mütter Museum numbers as they are displayed in the Museum - but they are College Collections + are also numbered College Collections file.

One skull is from New Madrid County, in the extreme southeastern corner of Missouri from one of the burial mounds, full of burials, in one of the fortified villages of that typical mound-builder region.

One skull is from a small mound on the banks of Geneva Lake in southeastern Wisconsin. It was a single burial, of late date; a few arrow heads were found in the mound beside the crumbling bones.

Most of the skulls are deformed. They present, to a more or less extent, the flattened occiput and, in addition, in some instances, the flattened frontal bone. As is well known, the flattened occiput is produced by strapping the papoose to a board in order that the child may be readily carried by the mother or hung up in some convenient place. The band which binds the head to the board produces the frontal flattening. These two deformities are not, strictly speaking, intentional deformities, but according to Dr. Rudolph Virchow, there are at least six others which have recently carefully catalogued in his Crania Ethnica Americana and which are artificial and deliberate.

This excessively brachycephalic skull is a deformity, originating in childhood when the cranial bones are easily compressed; it is characteristic of the indian tribes of the southwest, e.g. the Choctaws, Chickasaws, Natchez and, to some extent, the tribes north of them.

One might naturally suppose that flattening, which is extreme in some cases, might make a difference in the cubical capacity of the skull. Virchow's measurements, however, show that this is not materially disturbed. There does not seem to be any reason to believe that the intellectual capacity is altered by this deformity.

With reference to heredity and whether these deformities, which have been continued from generation to generation, have been able to have any influence in transmitting to succeeding generations a peculiar form of skull there has been much discussion. Dr. D.G. Brinton has stated his belief and the opinion prevails that "there is no tendency whatever to the transmission of these deformed skulls, no matter for how many generations the practice has been continued."

Comparative studies of American and European crania have shown that the general character of the American cranium is uniformly high and that " we do not find among them skulls presenting any anthropoid ~~orteramorphic~~ or theramorphic * characters as in the oldest skulls of Europe", consequently the conclusion is reached that the American race appeared first in America at a time when man was developed much higher in Europe than at the oldest time that we can trace him there.

It is found that the old North American or South American skulls are not deformed; the conclusion is that indian mothers did not adopt the method of carrying children which brings about the unintentional craniae deformities until after the American race had lived upon this continent for a long time.

theramorphic = mammal-like-structure
theriomorphic = lower mammal-like-structure
R.F.A.M.

Ashley Montagu

1007.	Skull	Presented by Prof. George McClellan.
1007.01	"	" " " " "
1007.02	" not in cm)	" " " " "
1007.03	" not in cm)	" " " " "
1007.04	"	" " " " "
1007.05	"	" " " " "
1007.06	Skull with outside cortical tissue removed from calvarium.	Presented by Prof. George McClellan
1007.07	Skull Persistent frontal suture.	" " " " "
1007.08	"	" " " " "
1007.09	"	" " " " "
1007.10	"	" " " " "
1007.11	"	" " " " "
1007.12	"	" " " " "
1007.13	"	" " " " "
1007.14 (A)	Vertical section of skull	Presented by Prof. George McClellan.
1007.14 (B)	" " " "	" " " " "
1007.15	Normal skull with perforations to estimate the average thickness of various portions of the cranium.	

nm)
e
m.

s into

1008.45 Skull with right maxillary dental cyst.

1008.46 Skull with maleruption of right maxillary canine. Hypoplasia.

1008.47 Skull of a typical mouth breather with narrow pyriform sinus and narrow and deep vault of the palate. Extremely obtuse at the base of the mandible. Hypoplasia of the teeth.

1008.48 Skull: Frontal suture.

1008.49 Anterior and lateral view of upper and lower jaws, with the external cortical portion of bone covering removed, exposing the cancellated tissue, the roots, and the cribriform tube (mandible canal). Fig. 31-32-110. Cryer's Internal Anatomy of the Face. Page 33-34 2nd Ed. Reverse & Enlarge

1008.50 A skull with a complete or true unilateral ankylosis of the Jaw. Fig. 358-359. Cryer's Internal Anatomy of the Face. Page 335-336

1008.51 Skull
1008.52 Skull-frontal suture.
1008.53 Section of skull.
1008.54 Skull showing forward occlusion of mandibular teeth. It will be noticed that the mandibular articulation is allowing but little play in the joint. The anterior wall of the external acoustic meatus is defective, its resorption may have been caused by the pressure of the condyle, or the wall may never have been formed.
Fig. 70. Cryer's Internal Anatomy of the Face.

1008.55 Skull of no particular interest except extreme thinness of cranial bones.

1008.57 Skull.
1008.58 A skull. The occlusion of the six molars and the two premolars is fairly good, but the rest of the teeth are not in proper alignment or occlusion and there is an open bite.
The distance from the cutting edge of the incisor teeth to the free border of the hard palate is 54 mm. from the hard palate to the anterior border of the foramen magnum, 38 mm.; from the basion to the vertical plane of the back of the skull, 105mm,; total length of the skull, 197 mm. It is evident that in this skull the principal cause of anterior occlusion is the short distance (only 92mm) from the cutting edge of the incisor teeth to the hard palate and the foramen magnum, this is 10 mm. shorter than ~~the~~ typical and its pharyngeal come is high. It will be noticed that two of the premolars are out of line, caused also by the smallness and shortness of the whole upper jaw. An additional cause of the anterior occlusion is that the angle of the mandible is unusually obtuse, measuring 135 degrees. If correction were made by slowly forcing the upper premolars into

1008.21 Skull - vertical section Presented by Dr. John H. Brinton.
1008.22 Skull and neck - vertical section " " " " "
1008.25 Skull - vertical section showing internal membranes Presented by Dr. John H. Brinton
1008.26 Portion of skull - vertical section showing internal membranes Presented by Dr. John H. Brinton
1008.28 Portion of skull. Presented by Dr. John H. Brinton
1008.30 Calvarium. This calvarium was evidently saved to show the deep Pacchionian Depressions
1012.50 Temporal bone:-
This specimen is the original one upon which Dr. Bridgett made the discovery, while working in the mastoid cavity, that the point where the digastric ridge of crista joins with the premastoid lamina maps out the location of the stylo-mastoid foramen and a line run from this point to the inner wall of the antrum maps out the line of the decending portion of the Aqueductus Fallopii.
The part marked (B) has a piece broken off at the bottom.
This specimen shows a simple mastoid operation.
Photograph found in Dr. Bridgett's article on the "Mastoid Operation," found in the Laryngoscope, May 1923. Presented by Dr. Frank Bridgett.
1009 occiput bone
1009.05 " " Presented by Prof. George McClellan
1009.10 " " " " " " "
1009.15 " " " " " " "
1009.20 " " " " " " "
1009.25 Occiput bone " " Dr. John H. Brinton.
1010. Parietal bone
1010.05 " " Presented by Prof. George McClellan
1010.10 " " " " " " "
1010.15 " " " " " " "
1010.20 " " " " " " "
1010.25 " " " " " " "
1010.30 " " " " " " "
1010.35 " " " " " " "
1010.40 " " " " " " "
~~1010.45~~
1011 Frontal bone
1011.05 " " Presented by Prof. George McClellan
1011.10 " " " " " " "
1011.15 " " " " " " "
1012 (1012) Temporal bones
1012.05 " " Presented by Prof. George McClellan
1012.10 " " " " " " "
1012.15 " " " " " " "
1012.20 " " " " " " "
1012.25 " " " " " " "
1012.51 Temporal bone, showing a simple mastoid operation.
Photograph of specimen found in Dr. Bridgett's article on the "Mastoid Operation," found in the Laryngoscope, May 1923.
1012.52 Temporal bone, showing a radical mastoid operation. Presented by Dr. Frank Bridgett.
Photograph of this specimen found in Dr. Bridgett's article on the "Mastoid Operation" found in the Laryngoscope, May 1923. Presented by Dr. Frank Bridgett.
1013 Sphenoid bones Presented by Prof. George McClellan
1013.05 Portion of the Sphenoid bones " " " " "
1013.10 " " " " " " " " " "
1012.17 Portion of temporal bone - Presented by Prof. Geo. McClellan
015. Superior Maxilla
015.05 " " Presented by Prof. George McClellan
015.10 " " " " " " "
015.15 " " " " " " "
015.20 " " " " " " "
015.25 " " " " " " "
015.30 " " " " " " "
015.35 Superior Maxilla
1008.35 Skull - Supposed to be from Rapa-nui - Easter Island. Cannibal. Dead not buried. Placed around the bases of the colossal images found on that island. Presented by Mrs. J. H. Lloyd.
~~1020. Malar bone~~ ~~Presented by Prof. George McClellan~~
1008.40 Unusual skull. Origin unknown. Apparently cosmetically flattened. Presented by Dr. C. B. Farr.
1008.41 Skull of a Baby. No identification.
1008.42 Skull. No identification. Persistent frontal suture. Remains of suture of the maxillary bone

position, it should lengthen the arch, which would assist in improving the position of the anterior teeth. The fault of the lower jaw is at the angle.
Fig. 82-96 & mandible in Fig. 10 Cryer's Internal Anatomy of the Face. Pages 30-87-93

1008.59 An impacted first incisor, with the crown partly in the incisive foramen.
The tooth lies diagonally across the alveolar process, with the apex of the root near the outside of the anterior nares. The crown passes across the incisive foramen. Impaction of this kind would more than likely interfere with the true function of the nerves and vessels passing through this foramen.
Fig. 151. Cryer's Internal Anatomy of the Face.

1008.60 A heavy skull. Unusually large, strong jaws and heavy teeth, which are in fairly good occlusion, except that the left second incisors are a little out of place. The extraordinary size of the jaws and teeth produces a general appearance of prognathism, but the position of the teeth and their processes does not carry out the idea.
Fig.80 mandible in Fig. 8 . Cryer's Internal Anatomy of the Face. Fig-9t- Pgs-86-92-28

1008.61 Skull belonging to a person of mixed races. In this instance the two jaws are abnormally forward of the typical position. The cranial portion in itself is not of a prognathous character, although the basilar process of the occipital bone is longer than in typical skulls.
Fig. 79 mandible in Fig.7. Cryer's Internal Anatomy of the Face. Pages - 85 - 28

1008.62 Typical skull. Fig. 75-76-77 mandible 2. Cryer's Internal Anatomy of the Face. Side view of a typical mandible at maturity.
Pages - 82-83-87

1008.63 A Chinese skull. General roundness. On the left side there is an impacted lower third molar: in the upper jaw of the same side there is no evidence that the third molar ever developed. Measuring from the cutting edge of the incisor teeth to the free margin of the hard palate 60mm. from the hard palate to the foramen magnum, 40 mm. from the basion to the posterior part of the skull 197 mm.
Fig. 81-95 & mandible in Feg. 11. Cryer's Internal Anatomy of the Face.

1008.64 A skull showing the condyloid process of the left side, articulating on the squamous portion of the temporal bone and partly on the great wing of the sphenoid instead of the mandibular fossa.
The remarkable characteristic is the abnormally small ramus, and portion of the body of the bone. There seems to be two ways in which this deformity of the articulation of the condyloid process could occur. One is by the lack of growth in the ramus and body of the bone; the other theory is that the bone grew to its normal size (as there is evidence of its having articulated in the mandibular fossa)

when an atrophied condition may have occurred which reduced the size of the remus and part of the body; in order to keep up occlusion of the teeth, the condyloid process moved forward first articulating on the articular tubercle, and as the atrophy progressed, moving still forward to keep the occlusion, until the condyloid process reached the position shown in the specimen.
Fig 363-364-365. mandible in Fig.9 Cryer's Internal Anatomy of the Face.

1008.65 Skull showing very marked right sided attrition of the denture with corresponding over division of the zygomatic arch.

1008.66 German skull. Depressed fracture of the frontal bone.
1008.67 Skull.
1008.68 Skull. Massive division of facial bones.

1008.69 A mandible, showing the left condyle in an abnormal position. Fairly typical of a fractured neck fo the condyle. The action of the pterygoideus externus carried the head of the condyle forward in which position the osseous union of the parts occured. The relations between the head of the condyle and the mandibular foramen would more than likely interfere with the mandibular nerve and vessel. This illustration also shows that there had been another fracture extending from between the second incisor and canine teeth downward through the body of the bone.
Fig.55 mandible to Fig. 57 Cryer's Internal Anatomy of the face.
Side view of this skull shows fractures neck of the condyle. The head of the condyle is bent inward and forward until it nearly forms a right angle with the ramus.
Fig.57 mandible 55. Cryer's Internal Anatomy of the face.

1008.70 Mandible, showing reunited fracture of the neck of the condyle in an abnormal position. Skull is that of old age.
Fig. 56. Cryer's Internal Anatomy of the Face.

1008.71 Impaction of right maxillary canine, pointing with crown in palatal direction.

1008.72 Skull
1008.73 Skull; Maxilla shows: left- aggregation of salivary calculus. No wear of the occusal surfaces.
Right: No aggregation of salivary calculus. Marked attrition.

Pages 78-80 - Fig. 71-72

1008.74 Skull; Extra enlarge middle turbinated bones. Considerable absorption of the alveolar process. Remnants of a frontal suture.

1008.745 Skull without calvarium or mandible.
1008.75 Skull: No calvarium.

1008.755 Skull: Almost total absence of alveolar process. Impaction of right maxillary 3rd molar.

1088.76 Skull: Atrophy of right maxillary bone. Erosion of teeth.

1008.765 Dentition of skull shows extremely large number of development groves without there being any caries connected with this condition.

1008.77 Skull- Malposition of teeth.
1008.775 Skull
1008.78 Skull
1008.785 Skull

1008.79 Skull- Flattened palate. Partial absorption of the entire alveolar process of the maxilla. Extremely large foramina magnum.

1008.795 Section of a skull.

1008.80 Skull-Impaction of 3rd molar.

1008.805 Skull- Both cut to show extremely large frontal and maxillary sinuses.

1008.81 Skull
1008.815 Anterior view showing two frontal sinuses, the right one very large extending well over to the left side.
There appear to be three sinuses in the specimen but the septum on the right is incomplete, making but one sinus on that side, which is very large extending from the right zygomatic process transversely well over to the left side, and measuring 65 mm. Its depth from the top to the outlet is 45 mm., and it extends well back over the orbit 40 mm.; the left sinus passes outward and backward to about one-half the distance of that on the right side.
Fig. 248. Cryer's Internal Anatomy of the Face.

1008.82 A Philippine skull, showing impacted third molars Fig.154-155. Cryer's Internal Anatomy of the Face.
1008.825 Skull
1008.826 A typical skull
1008.83 Skull of a child of about five and a half years of age, showing the roof of the mouth with the deciduous teeth in position and the various sutures. Also non-union of the two premaxilla in the median line.
Fig.71-72. Cryer's Internal Anatomy of the Face.

1008.835 The skull of a child.
1008.84 Child skull with more than the usual seven sutures, radiatin from the media suture toward the interspace between the teeth.
Fig. 73 mandible fig.1, Cryer's Internal Anatomy of the Face. Page 80
1008.845 Skull of a child.
1008.846 Skull of a child.
1008.85 Skull of a fully developed embryo cut vertically through the first deciduous premolars.

DISARTICULATE SKELETONS.

1008- Skull;Disarticulated and mounted secundumartern.

197 Sec 9 Shelf 2 148

The bones are separated from each other at their sutures but are mounted on a metallic framework so as to preserve the form of the skull and proper relative position of the bones. By a mechanical arrangement, the several bones may be made to approach or recede from each other.

The structure of the maxillary bones and their vascular and nervous supply are well shown.

1008.02 Right half of normal skull without calvarium

1008.03 Skull Purchased

1008.04 Skull – showing the separate bones making up the skull Presented by Dr John H. Brinton.

see 1069. vol I p.308 number ~~dat lester~~. 1008.05 magnum

~~1008.05~~- Skull;vascular and nervous distribution.

195 Sec 9 Shelf 2 149

The vessels have been injected and are well seen upon the right side;the nervous supply is seen on the left. A portion of the outer table has been removed showing the diploe and the course of its veins.

~~1008.06 Skull, left half showing nerves and arteries~~ Purchased ~~Presented by Prof. George McClellan~~

1008.10 Skull;disarticulated ~~and sawn~~ mounted, showing especially the cancellous tissue and deeper anatomy.

199 Sec. 9 Shelf 2

From Dr. Forbes - Jefferson.

Purchased.

1008.15- Skull;disarticulated and sawn; showing the sinuses and deeper anatomy.

1008.20 Horizontal + Vertical section of Skull Purchased Missing Presented by Prof. George McClellan

200 Sec 5 Shelf 3

1021 Inferior Maxilla. Old Age.

The alveolar border has almost disappeared. The sockets of a few incisor teeth remain. The angle of the rami with the body is almost 180°. The chin is prominent.

Presented by Dr. Mutter.

1021.05 Inf ... of old age ... by Dr. Means.
244

1021.45 Inferior maxilla of old age — Presented by Prof George McClellan.
1021.50 Inferior Maxilla of a child — Presented by Prof George McClellan
1021.55 " " " " " " " " " " "
1021.60 Inferior Maxilla " " " " " " "
1021.65 " " " " " " " " " "
1021.70 " " " " " " " " " "
1021.75 " " " " " " " " " "
1021.80 Inferior maxilla with the external cortical portion of the bone removed. Presented by Prof. George McClellan.
1021.61 Inferior Maxilla " " " " " " " " " Presented by Dr. John H. Brinton
1021.62 " " " " " " " " " " " " " " "
1021.63 " " " " " " " " " " " " " " "
1021.64 " " " " " " " " " " " " " " "
1021.66 " " " " " " " " " " " " " " "
1021.67 " " " " " " " " " " " " " " "
1021.81 Inferior Maxilla vertical section Presented by Dr. John H. Brinton
1021.82 " " " " " " " " " " " " " " "
1021.83 " " " " " " " " " " " " " " "
1021.86 Portion of Inferior Maxilla Presented by Dr John H Brinton
1021.87 " " " " " " " " " " " " " " "

1021.68 #341 Inferior Maxilla.
1021.69 #24 " "
~~1021.70~~ " "
1021.71

1021.871 Portion of inferior Maxilla
1021.872 " " " " " " " " " "
1021.873 Inferior maxilla.

1021.10 Inferior Maxilla of Old Age.
201 Of the body only the basilar portion remains. The
Sec 8 specimen lacks the right ramus.
Shelf 3
Presented by Dr.W.S.Halsey.

1021.15 Inferior maxilla of old age
Presented by Dr John H Brinton
1021.20 Inferior Maxilla of old age.
202 The Alveolar portion is wholly absorbed excepting at
Sec 8 the location of the incisor teeth. The angle of the
Shelf 3 ramus with the body is 135°.
Presented by Dr.W.S.Halsey.
1021.25 Inferior maxilla of old age
Presented by Dr John H.Brinton
1021.30 Inferior Maxilla of old age.
203
Sec 8
Purchased.
Shelf 3
1021.35 Inferior Maxilla of old age
Presented by Dr John H. Brinton
1021.40 Inferior Maxilla of old age.
204
Sec 8
Purchased.
Shelf 3

1022 Hyoid Bone. Presented by Dr Means
Missing
~~#250~~ Sec 8 Shelf 4

1023 calverium — Presented by Prof. George McClellan
1023.05 " " " " " " " " "
1023.10 " " " " " " " " "
1023.15 " " " " " " Dr John H. Brinton
1023.20 Calvarium. Region of right parietal (separated from the other half.)
1023.21 Portion of a skull.
1023.22 Inferior maxilla
1023.23 Inferior maxilla.

MATTHEW H. CRYER ANATOMICAL COLLECTION.
FACE SECTIONS AND HEAD.

1023.30 Impacted mandibular third molar.

1023.301 A common form of impacted lower third molars. They often give great trouble by irritating the inferior alveolar nerve. They may also cause an inflammatory condition in this region, and the cellulitis may extend to the mandibular articulation and the base of the tongue.
Fig. 158. Cryer's Internal Anatomy of the Face.

1023.302 Jaw having a true unilateral ankylosed mandibular articulation.
The condyloid process is completely changed. It is broadened out, and is sharply serrated on the articulating surface. The articulating surface of the mandibular fossa is also changed to correspond to that of the condyle with which it was interlocked. The angle of the jaw on this side is much more changed than on the right side, causing a deep depression in the region of the facial notch. The lower jaw, beneath the mental process, is fuller and more roughened and the mental process more concave than on the opposite side.
Fig.356-357. Cryer's Internal Anatomy of the Face.

1023.303 Misplaced mandibular third molar. The molar tooth is in the ramus of the mandible. Teeth in this position in the living subject often give considerable trouble and their existence is very difficult to diagnose without the use of x-ray.
Fig. 157. Cryer's Internal Anatomy of the Face.

1023.304A
1023.304B Mandibles showing variations in distance between the two condyles and from the condyles to the incisor teeth.
Fig. 61-62 Cryer's Internal Anatomy of the Face.

1023.3041 View from above of mandible from which all the teeth have been removed, showing the cribriform character of the septa of the sockets of the teeth;
Fig. 34. Cryer's Internal Anatomy of the Face.

1023.305 Horizontal impaction of mandibular third molar.

1023.306 Four mandibles ranging from birth to 18 months.
A - at birth B - at three months
C - at six months D - at eighteen months.
At birth the angle is very obtuse, but as the teeth develope and erupt, it becomes less and less obtuse.
Fig. 1 & B mandible Fig. 68. Cryer's Internal Anatomy of the Face.

1023.307 Mandible
1023.308 Mandible ofaan aged person showing the mental foramina in the top of the body of the jaw. Fig. 4. Cryer's Internal Anatomy of the Face.

1023.309 Plaster cast, showing six premolar teeth. Fig. 342. Cryer's Internal Anatomy of the Face.
1023.309A Plaster cast of lower jaw from a clinical patient about 24 years of age showing four premolars on each side. C-345.

1023.310 Horizontal section made at the necks of sixteen mandibular teeth.
Showing the shape and relation of the teeth. It also shows the investing membranes of the teeth and the linings of the sockets.
Fig. 115. Cryer's Internal Anatomy of the Face.

1023.311 Horizontal section made at the necks of fourteen mandible teeth. Showing the shape of the teeth in cross-section and the size of the pulp chambers in a matured skull.
Fig. 114. Cryer's Internal Anatomy of the Face.

1023.312 Chinese mandible with impacted mandibular molars.

1023.313 Specimenshowing two abnormal openings into the antrum. Sphemoid ostium rather high.
1023.314 Invasion of antrum by roots of molar tooth.

1023.315 Two opening from the antrum to the nasal chamber. The middle turbinate is rudimentary.

1023.316 Antrum extending into the zygmona.

1023.317 Bony septa in both antra.

1023.318 Two openings from the antrum to the nasal chamber.
1023.319 Small maxillary sinus extending barely over third molar.
1023.320 Maxillary sinus with two openings.
1023.321 Maxillary sinuses with many accessory pockets
1023.322 The inferior turbinate extends above an opening into the antrum which measures about 1.25 cm.

1023.323 Large antra, with irregular architecture favoring the retention of secretima during irrigation.

1023.324 Membranous septum in upper anterior angle of maxillary sinus.
1023.325 Antrum with two openings into the nasal chamber.
1023.326 Small maxillary sinus with thick floor.
1023.327 Unusually large opening into antrum.

1023.328 Large symmetrical maxillary sinuses extending slightly below the level of the floor of the nose.
1023.329 Maxillary sinus almost globular in shape.

1023.330 Face section. Openings into antrum are very high, making drainage almost impossible.

1023.331 Face section. Partial bony vertical septum in maxillary sinus. Infraorbital canal across upper angle.

1023.332 Face section. Antrum showing an unusually thin anterior wall.

1023.333 Face section.
The antrum possesses two opeinings placed side by side. The on leads to the nasal chamber; the other passes upward and inward and forward leading into the anterior ethmoidal cells.

1023.334 Face section. An accessory cell in the wall between the antrum and the nasal chamber.

1023.335 Face section. Maxillary sinus with many pockets one of which extends into the zygoma. The ethmoid cell section is separated from the antrum by a thin bony wall.

1023.336 Maxillary sinus with small bony septum and two openings into the nasal chamber.

1023.337 Small maxillary sinus. Frintal sinuses extending under the orbit. Fig. 105 Cryer's Internal Anatomy of the Face.

1023.338 Horizontal section, showing abscess from second premolar opening through the floor of the right maxillary sinus.

1023.339 Horizontal section, showing partial bony septum in the right maxillary sinus. Dr. Cryer never found a complete bony division.

1023.340

1023.340 A Anterposterior division of the maxilla, showing opening of a dental abscess within the maxillary sinus and an infra-orbital sinus.
The first molar is decayed and the pulp-chamber of the tooth open. The root-canal has been infected and the infection has been carried into the sinus. In this case there is evidence of a productive periostitis upon the floor of the sinus, which has caused a thickening of bone over apex of the root. At a later period supperative inflammation has occurred and perforated the floor.
Fig. 223-224. Cryer's Internal Anatomy of the Face.

1023.342 Horizontal sections through the maxillary sinus. In the latter there is an exostosis over the position of an infected root of the first molar tooth. In the former the cap of bone covering the root has been removed, exposing the end of th the root and a fistula extending downward, opening into the roof of the mouth.
The pulp of the first molar was devitalized. In the latter an enlargment of the infected root is seen. An examination of the hard palate shows that the discharge of the abscess was made into the mouth, which the writer believes is the usual outlet for apical abscesses in the upper

jaw. Of course recognizing that they occasionally open into the sinus.
Fig. 227-228. Cryer's Internal Anatomy of the Face.

1023.343 Anterposterior division through the center of the orbit, maxillary sinus, and molar teeth, showing a large maxillary sinus and a large sphenoidal sinus.
Cryer's "Anatomy of the Face." Fig. 216

1023.344 A horizontal section cut just above the floor of the nasal cavity, which is very wide. On the right, there is no maxillary sinus and on the left the sinus is very small.
Cryer's "Anatomy of the Face." Fig.194

1023.345 Large posterior ethmoidal cells. The ostia of the sphenoidal sinuses are of different levels.

1023.346 Both antra communicate directly with the naterior ethmoidal cells.

1023.347 The left sphenoidal sinus possesses an accessory cell.

1023.348 Direct communication of each antrum with its appropriate group of ethmoidal cells.

1023.349 Cribriform tube (mandibular canal) of the lower jaw isolated.
Shows that the cribriform tube is an independent structure not merely a canal through the bone.
Fig. 33 Cryer's Internal anatomy of the Face.

1023.350 Large Sphenoidal sinus.

1023.351A Posterior section from the preceding specimen.
1023.351 Fig. 104 Cryer's Internal Anatomy of the Face.

1023.352 Narrow arch and wide floor of nose. The dental
1023.352A arch measures 35 mm. The floor of the nose, which should be 27.5 mm., is 35 mm.

1023.353 Unusually large maxillary sinuses. A vertical transverse section of a skull just in front of the first molar teeth, looking forward. The arch is of good width, though narrow at the top, the mrasurement over the premolars being 55 mm. The floor of the nose measures about 20 mm. and the widest portion of the nose is 32 mm. There are unusually large maxillary sinuses, with a correspondinglynarrow nasal cavity. Before the sinuses were cut, each held one fluid ounce and a quarter (about 35 c.c. or together 70 c.c.) At the point of the section two antra are but 19 mm. apart, as they virtually pass under the nasal cavity. In the region of the first premolar teeth the distance between the two antra is about 13 mm.
Fig. 103 Cryer's Internal Anatomy of the Face.

1023.354 Very narrow arch and wide nose.
The width across the outside of the second premolars is but 44 mm., while the floor of the nose measures 35 mm.
Fig. 102. Cryer's Internal Anatomy of the Face.

1023.355 Wide arch, narrow nose. The arch is 70 mm. in width, while the floor of the nose is only 26 mm. wide.
Fig. 99. Cryer's Internal Anatomy of the Face.

1023.356 The roof of the mouth and occluding surfaces of the teeth from an ordinary sized upper jaw, showing two rudimentary fourth molars.
Fig. 349. Cryer's Internal Anatomy of the Face.

1023.357 Two prehistoric mandibles, showing impacted mandibular third molars. These two bones were found near Tuckerton, N.J. and are supposed to have belonged to a race of people inhabiting this region before the North American Indians.
Fig. 334-335. Cryer's Internal Anatomy of the Face.

1023.358 A vertical transverse section near the first molar teeth, showing maxillary sinuses which are nearly cuboidal in shape and which extend downward below the floor of the nasal cavity. The nasal cavity is narrow and the walls dividing it from the sinuses are concavoconvex in their vertical direction. The arch is wide. Anterior view showing four frontal sinuses.
The measurement of the arch is 66mm. The nose should be 35 mm., but is only 20mm. It will be noticed that the maxillary sinuses are very large, which is usually the case where the nose is narrow. The four frontal sinuses have four independent outlets and three complete septa. The maxillary sinuses extend inward and toward the medial line, outward into the zygomatic bones, and upward into the ethmoidal cells. The inner walls are not straight. Starting at the floor of the sinus, almost over the centre of the dome of the mouth, the inner wall, as it extends upward, curves outwardly, then inwardly to the point at which the inferior concha projects into the nasal cavity.
Fig. 101-245-297 Cryer's Internal Anatomy of the Face.

1023.359 Two illustrations from different subjects,
1023.359 A showing great variation as to depth and size in the external wall of the nasal cavities. One specimen shows four meatuses. Fig. 285-286. Cryer's Internal Anatomy of the Face.

1023.360 Alveolar process.
Fig. 229. Cryer's Internal Anatomy of the Face.

1023.361 Anterposterior division through the maxillary sinus and the teeth, showing an infra-orbital sinus above the canal.
Cryer's Anatomy of the Face. Fig. 230

1023.362 The frontal sinuses are unusually large in depth and extend unusually low.

1023.362 A Three pieces of bone with molar teeth
1023.362 B that have been accidentally broken away
1023.362 C with part of the floor of the maxillary sinus in an extraction, A & B with ordinary forceps, C with an old fashioned turnkey. Cryer's Internal Anatomy of the Face. Fig. 231-232-233.

1023.363 A molar tooth extending well into the antrum. The right frontal sinus extends into the cribriform plate.

1023.364 Large frontal sinus extending well under the orbit.

1023.365 Left frontal, left ethmoidal, and left sphenoidal sinuses exposed. Course of Infundibulum may be readily followed.

1023.366 Vertical section made in the region of the molar teeth. Posterior view shows small sinuses and large nasal cavity and narrow dental arch.
The septum of the nose is deflected and a "spur" reaches over to the middle concha. The frontal sinuses extend down below the middle of the orbit. Between them there is an interfrontal cell extending backward into the crista galli. A wire passed downward from the right frontal sinus is again seen in the maxillary sinus. The wire is seen passing downward from the right frontal sinus through the infundibulum and hiatus semilunaris and entering the maxillary sinus through the ostium maxillare. The frontal sinuses extend in an outward direction over the orbits.
Fig. 281-268-292-293. Cryer's Internal Anatomy of the Face.

1021.054

1023.368

#368

1023.367 A skull with frontal sinuses extending from within the great wing of the sphenoid bone forward to the frontal bone then backward to the left sphenoid bone.

"This specimen has the largest pneumatic
examined, not only
the supera-
llary sinuses."
mences in the
oint near the
bone with the
It extends for-
o the opposite
rd, terminating
the sphenoid.
the great space is
ents, three of
et, while the
of the others by
laced low down in

right frontal
in the temporal
forward and in-
measuring 55 mm.
nus commences in
the right wing of
ses upward and in-
outlet is in the
n of the right
s in length 55 mm.
her sinuses or cells
of the orbits with

s commences in the
asses upward, for-
the wall forming
sinus. It measures
ded into two com-
ing at an angle of
zontal. At the lower
is a small foramen
partments to commun-
tlet into the nasal

nternal Anatomy of

, the crown in the
reater portion of
y sinus.
s made, the root
lamina of bone.
often found, involving
th, but also the third
other teeth, which
sitions for years
ble until after
tural resorption

V. 1 p. 232-74

15 models of
Plaster Casts
of the Ear?

Funds

1023.367 X

A skull with frontal sinuses extending from within the great wing of the sphenoid bone backward

umatic
d, not only
supera-
sinuses."
in the
ear the
with the
tends for-
opposite
minating
phenoid.
at space is
hree of
le the
others by
ow down in

rontal
temporal
rd and in-
ring 55 mm.
mmences in
ght wing of
ard and in-
is in the
e right
ngth 55 mm.
uses or cells
orbits with

nces in the
pward, for-
ll forming
t measures
two com-
n angle of
At the lower
nall foramen
s to commun-
o the nasal

Anatomy of

rown in the
portion of
.
the root
f bone.
und, involving
also the third
eeth, which
for years
l after
sorption

232-7

V. 1 p. 232-7a

p. 232-7a

The Mütter Museum of the
College of Physicians.

The attention of the Fellows of the College is directed to the interesting osteological collections in the Mütter Museum, among which are the following;

Hyrtl Collection of Crania	These skulls, of all races, brought together by Professor Hyrtl of Vienna, hold much of interest. They now occupy shelves in cases 1, 2, 3 and 4 at the entrance to the museum.
The Krumbhaar	A collection consisting of World ...es, is displayed

1023.367 A skull with frontal sinuses extending from within the great wing of the sphenoid bone forward to the frontal bone then backward to the left sphenoid bone.
"This specimen has the largest pneumatic spaces of any head I have examined, not only of the frontal sinus, but of the supera-orbital, sphenoid, and maxillary sinuses."
The right frontal sinus commences in the right temporal fossa at a point near the articulation of the frontal bone with the great wing of the sphenoid. It extends forward and across the skull to the opposite side, then a little backward, terminating near the left great wing of the sphenoid.
The frontal portion of the great space is divided into four compartments, three of which have a separate outlet, while the fourth is connected to one of the others by a small foramen which is placed low down in the sinus.
As already stated the right frontal sinus commences at a point in the temporal fossae and extends upward, forward and inward almost to the nasion, measuring 55 mm. The right supra-orbital sinus commences in the zygomatic fossa or in the right wing of the sphenoid bone; it passes upward and inward over the orbits. Its outlet is in the anterior and lower portion of the right frontal sinus. It measures in length 55 mm. There are also several other sinuses or cells over the anterior portion of the orbits with independent outlets.
The left frontal sinus commences in the temporal fossa. It then passes upward, forward and to the right, to the wall forming an intermediate frontal sinus. It measures 48 mm. The sinus is divided into two compartments by a septum lying at an angle of 35 degrees from the horizontal. At the lower end of this septum there is a small foramen which allows the two compartments to communicate with one common outlet into the nasal cavity.
Fig. 259-260. Cryer's Internal Anatomy of the Face.

1023.369 An impacted canine tooth, the crown in the roof of the mouth, the greater portion of the root in the maxillary sinus.
Before the dissection was made, the root was covered witha thin lamina of bone.
Similar conditions are often found, involving not only the canine tooth, but also the third molar, and occasionally other teeth, which often remain in such positions for years without giving any trouble until after middle life, when by natural resorption

of the bone, the crown and root become exposed within the maxillary sinus or nasal cavity at which time they may cause some disturbance.

1023.370 Frontal sinus with extremely thin anterior wall, readily fractured by the trauma.

1023.371 An impacted supernumerary tooth. There was no enlargement of the external plates of the incisive fossa, the floor of the nose, or the roof of the mouth. The tooth was accidently discovered when cutting the bone transversely. Fig. 152. Cryer's Internal Anatomy of the Face.

1023.372 The maxillary sinus and nasal cavity. Fig. 280. Cryer's Internal Anatomy of the Face.

1023.373 Posterior views of two vertical transverse section made from different skulls in about the same anatomical region, showing great variations as to the depth of face, and size and shape of nasal cavities and maxillary sinuses. B also shows the lower inner corners of the maxillary sinuses passing partly under the nasal cavity.
Cryer's Anatomy of the Face. Fig. 284-261

1023.374 Posterior view, showing two incomplete septa. The incompleteness of the latter is more than likely due to pathological conditions.
Fig. 252. Cryer's Internal Anatomy of the Face.

1023.375 Anterior view, showing five frontal sinuses and four complete septa. Four of the sinuses extend well upward to about the same height.
Fig. 246. Cryer's Internal Anatomy of the Face.

1023.376 Horizontal section above the orbit. A transverse section of a large left frontal sinus, measuring 67 mm. from the left zygomatic process, to a position over the centre of the right infra-orbital foramen without a septum. The right frontal sinus, measuring 40 mm. has several small incomplete, nearly horizontal septa, making a number of horizontal pockets.
Fig. 249. Cryer's Internal Anatomy of the Face.

1023.377 The roof of the maxillary sinus and upper portion of the nasal cavity. In this case the commencement of the ostium maxillare is within the roof. It passes backward and inward to the hiatus semi-lunaris. A probe placed in the left ostium maxillare indicates its position. Immediately to the left of the probe is a section of the masolacrimal duct. On the opposite side, the lower wall of the right ostium has been removed.
Fig. 279. Cryer's Internal Anatomy of the Face.

1023.378 Anterior view of the skull showing three complete frontal sinuses with three individual outlets and two complete septa. The two lateral sinuses pass backward well over the orbits. The posterior view shows two large maxillary sinuses. The right forming a common cavity with ethmoid cell and maxillary sinuses. The right hiatus semilunaris in this subject communicates with the maxillary sinus without a true ostium maxillare.

The septum is reflected toward the left side the right maxillary sinus extends upward and inward, terminating in a large opening into the hiatus semilunaris without a true line of demarcation. The left maxillary sinus extends forward into the infra-orbital ridge, forming an infra-orbital sinus. The numerous pockets in the anterior portion of the maxillary sinus would render it difficult to treat would it become diseased. Fig. 2440247-295 Cryer's Internal Anatomy of the Face.

1023.379 Small frontal sinuses in an extremely thick frontal bone. Transillumination is such instances proves misleading but a roentgenogram usually reveals the true cause of the failure to transmit light.

1023.380 An impacted canine tooth with the apex of the root within the nasal cavity. The external bone has been cut away, exposing the tooth and its root. The tooth is a little below the place of developement. The apex is curved forward and inward, the inward portion passing just into the nasal cavity. A little external to the apex of the root is an opening into the maxillary sinus. Fig. 144-145. Cryer's Interna Anatomy of the Face.

1023.381 Extremely large frontal sinuses with a moderately thick anterior wall.

1023.382
1023.382 A Section through the maxillozygomatic articulation, showing that occasionally the maxillary sinus passes into the zygoma. Fig. 271. Cryer's Internal Anatomy of the Face.

1023.383 An odontoma and an impacted first incisor. Fig.140. Cryer's Internal Anatomy of the Face.

1023.384 Horizontal section of the mandible cut in the region of the points of the roots of the teeth. Fig. 44. Cryer's Internal Anatomy of the Face.

1023.385 Vertical section made through the left ear, giving a posterior view of the external acoustic meatus, the tympanic membrane and cavity, the auditory tube, and a section of the condyle. A most important point is the relation of the condyle to the temporal bone and its surrounding tissue; the attachment of the

pterygoideus externus is well shown. Fig. 64 Cryer's internal Anatomy of the Face.

1023.386 Maxilla showing an unerupted third molar tooth.

1023.387 Sequestra from tubercular necrosis.
Necrotic seauestra and four teeth, which had been removed from a tubercular patient. The bone around the roots of the teeth was so fragile that it crumbled in pieces, leaving only a little band of soft connective tissue holding the teeth together, the condyloid and coronoid processes were left in position. On removing the sequestra new bone could be felt at the bottom of the space which eventually became entirely filled with osseous tissue. The patient was of course edentulous, but had a new half of a mandible well covered with gum tissue and in good union with the other half. There was no ankylosis.
Fig. 46. Cryer's Internal Anatomy of the Face.

1023.388 Both frontal sinuses drain into the left infundibulum.

1023.389
1023.389 A Two impacted canine teeth, Their malposition caused the loss of the left first and the second premolars, also the loss of the right first premolars.
They were entirely coverd with bone, and were exposed by a surgical bur. The end of the root of the right canine is somewhat curved. There is only a slight layer of bone between it and the floor of the sinus. The layer of bone is perforated by three small openings.
Fig. 146. Cryer's Internal Anatomy of the Face.

1023.390 Two anterposterior sections made by divinding the orbit and maxillary sinus vertically, showing conical elevations over the roots of the various teeth. The root of the second premolar curves forward. It More commonly curves backward. Fig. 202-203. Cryer's Internal Anatomy of the Face.

1023.391 Vertical transverse division of the upper jaw. In one specimen the roof of the maxillary sinus is almost horizontal, which is a very unusual condition. What is apparently a division of the sinus into two, the smaller or outer division forming an infra-orbital sinus. This condition is caused by a bony septum passing down from the centre of the floor of the orbit, cutting off a portion of the sinus, and forming an extra chamber, which of course is continuous with the true sinus. In the centre of the septum-like wall is a tube or canal conveying the infra-orbital nerves and vessels. Above this and at the junction of the septum with the floor of the orbit is an adjunct infra-orbital canal and nerve. At the upper inner corner of one specimen is the normal

opening of the maxillary sinus, the ostium maxillare, communicating with the hiatus semilunaris. This section beautifully illustrates how the hiatus semilunaris is bounded on the inner side, and above by the bulla ethmoidalis, containing the middle ethmoidal cells. Should the bulla become enlarged, or the mucous membrane of this region be swollen, the hiatus would be closed and fluids could not pass directly into the the middle meatus but would be thrown into the maxillary sinus.
Fig. 276-277. Cryer's Internal Anatomy of the Face.

1023.392 X
1023.393 X
Two views of the sides of a metal cast of the open spaces in the body of the mandible. Fig.41-42. Cryer's Internal Anatomy of the Face.

1023.394 X
1023.394(A)
Longitudinal division of a mandible, exposing the cancellated tissues in the body of the jaw and between the sockets of the teeth.
The left side of a lower jaw cut lengthwise nearly through its centre, exposing the cancellated tissue, the sockets of the teeth, and the cribriform tube of mandibular canal, with its branches to the alveoli. As the tissue is very frail, a considerable quantity of the trabeculae was lost in the cutting. The outer section shows the direction of the recurrent tube for the accomodation of the mental nerve and vessels. Fig. 40. Cryer's Internal Anatomy of the Face.

1023.395 X
Sequestrum from diseased mandible. Fig.52 Cryer's Internal Anatomy of the Face.

1023.396 X
1023.396(A) X
Two specimens, showing large frontal sinuses. One section is a sagittal section cut near the centre of the orbit, showing in the anterior portion a lateral view of the frontal sinus divided into five pockets, all of which have one common outlet. The sixth, or posterior cell communicates with the upper meatus of the nose. The other specimen is also a sagittal section cut to the median line of the os planum of the ethmoid bone. It shows a frontal sinus extending backward nearly to the optic nerve which is seen in position in the optic foramen. Fig. 253 Cryer's Internal Anatomy of the Face.

1023.397 X
1023.397(A) X
Anterposterior division through the centre of the orbit, maxillary sinus and teeth, showing an enlarged cell of the orbital process of the palate bone, and a correspondingly small Maxillary sinus.
It may be on account of the extremely small maxillary sinus that the cell was abnormally enlarged to increase the air space of this region, or that the palatal process has en-

croached upon the space usually occupied by the maxillary bone. The bony septum of this specimen might very easily be mistaken as divinding the sinus into two, but the writer would not thus classify it, as this posterior sinus opens into the superior meatus, as do the other palatal cells just described.
Fig. 213-214. Cryer's Internal Anatomy of the Face.

1023.398 Anteroposterior division through the centre of the orbit, maxillary sinus, and molar teeth, showing a triangular cell at the upper posterior corner of the maxillary sinus.
This specimen was taken from a negro's skull. This triangular cell opens into the superior meatus of the nose and belongs to the palate bone. Fig. 209. Cryer's Internal Anatomy of the Face.

1023.399
1023.399(A) Anteroposterior section, cut apart through the frontal sinus, the hiatus semilunaris, the bulla ethmoidalis, and the posterior ethmoidal cells. One section shows a divided bulla ethmoidalis, the other two ostia maxillaria. The anterior opening is the normal ostium maxillare, the posterior one is pathological. One specimen shows the lateral wall of the nasal cavity with a greater portion of the conchae removed. The other, the septum of the nose. The two together give a very clear idea of the character of the hiatus semilunaris and the bulla ethmoidalis. In this case the bulla is very large and extends downward and forward, closing the hiatus. The specimen is dried, showing an incomplete closure, which in the recent state must have been complete. This would have caused the fluids from the frontal sinus and the ethmoidal cells anterior to the closure to be directed into the maxillary sinus, as the ostium maxillare is also anterior to the bulla ethmoidalis. The maxillary sinus would become engorged with these fluids, which would naturally make their way through the walls in the direction of the least resistance; in this case at the abnormal opening shown. These sections also illustrate a condition some times met with, when the hard palate is unusually flat. In such cases the floor of the nose, instead of being horizontal, is depressed about the middle, giving a concavity which affords a lodgment for inspissated mucus. The same condition may also occur in the floor of the nose, when the inferior meatus is occluded, and is also found in other spaces in and about the nasal cavity. Collections of the character often produce irritation of the mucous membrane interfereing with the nourishment of the bone beneath, and at time causing a necrotic condition.
Fig.185-186-187-188. Cryer's Internal Anatomy of the Face.

1023.400 Horizontal section above the right floor of the nasal cavity and maxillary sinus, showing the opening of a dental abscess on the floor. In the middle of the sinus there is a conical elevation with an opening in the centre exposing the apex of a tooth. In this case, new bone has been formed over the diseased root, but at some subsequent time the bone has been broken down and the sinus has become infected. Fig. 225. Cryer's Internal Anatomy of the Face.

1023.401 Anteroposterior division through the centre of the orbit, maxillary sinus, and molar teeth, showing a large maxillary sinus and a large sphenoidal sinus.
Posterior to the maxillary sinus we find another sinus of a different character, which from superficial examination, might be thought to be related to it or to be an enlarged cell belonging to the palate bone, a probe passed into it leads to the supreme of the fourth meatus of the nose, indicating that it may be related to or connected with the sphenoidal sinus. In fact, it is a very large sphenoidal sinus extending out laterally in a line almost to the outer part of the maxillary bone.
Fig.215-216. Cryer's Internal Anatomy of the Face.

1023.402 Vertical transverse section of the right side of the face. Section cut vertically or longitudinally through the nasolacrimal duct, showing its posterior portion as it passes from the orbit downward within the wall, separating the nasal cavity from the maxillary sinus, the duct terminating in the upper portion of the inferior meatus. On the upper right corner is the frontal sinus. To the left of this is the orbit. In the centre of the wall between the orbit and the maxillary sinus, which in this case is very large. In the upper portion of the nasal cavity is seen the middle nasal concha, below which a cord has been passed from the middle meatus through the ostium maxillare into the maxillary sinus.
Fig. 175. Cryer's Internal Anatomy of the Face.

1023.403 Anteroposterior division through the centre of the orbit, maxillary sinus, and molar teeth, showing a crescent-shaped cell at the upper posterior corner of the maxillary sinus.
What at first sight might be considered to be a bony division of the maxillary sinus; but close investigation reveals that the crescent-shaped cavity situated on the upper posterior corner of the sinus is the cell of the orbital process of the palate bone cut in two.
Fig.207. Cryer's Internal Anatomy of the Face/

1023.404 X
1023.404(A) X Anteroposterior division through the orbit, frontal sinus, maxillary sinus, and molar teeth, showing a similar condition as the previous one. An abscess has burrowed under the mucous membrane near the roots of the first molar tooth.
Fig. 221-222. Cryer's Interral Anatomy of the Face.

1023.405 X Dento-alveolar abscess perforating the floor of the nose.

1023.406 X The left side of the medial wall, showing a pathological opening opposite the bulla ethmoidalis, also an abnormal opening into the maxillary sinus.
An opening in the septum exposes to view the bulla ethmoidalis and the ethmoidal cells. This opening resulted from resorption caused by pressure due to the deflection of the septum and the enlargement of the bulla downward near the unciform process. We have here illustrated an example showing how enlargement of this structure may be an important factor in causing various diseases of this region, including those of the maxillary and frontal sinuses. Of the two openings into the maxillary sinus as seen in this specimen, the anterior one is normal, the posterior is pathological. This abnormal opening and the loss of the greater portion of the middle concha were caused by resorption due to the pressure of the bulla ethmoidalis before referred to.
Fig. 181-182. Cryer's Internal Anatomy of the Face.

1023.407 X Mandible (left side) with the corticle portion of the bone removed together with the cancellated tissue, exposing the nerves and vessels within the cribriform tubes as they pass to the roots of the teeth.
Showing the smaller tubes passing to the roots of the teeth, with their contents, proving that these tubes do act as conduets for the nerves and blood vessels.
Fig.35. Cryer's Internal Anatomy of the Face.

1023.408 X Horizontal section showing the under surface of the inferior concha and the outlet of the nasolacrimal duct.
Fig. 179. Cryer's Internal Anatomy of the Face.

1023.409 X Specimen showing the greater portion of the upper jaw. Sounds passed down the nasolacrimal ducts, showing that they do not pass at the same angle. The illustration also shows an impacted canine tooth.
Horizontal section, shows the under surfaces of the inferior concha and the outlet of the nasolacrimal duct.

232-15

The upper boundry is on a level with middle of the orbits. The sounds indicate that the ducts pass outwardly as they descend into the upper part of the inferior meatus. It will be observed that the right duct has a greater outward deflection than the left. The horizontal line above the roots of the teeth and below the zygoma makes a division of the section just above the floor of the nasal cavity. The upper surface of the upper portion affords a view of the surface of the inferior concha from below, with the lower orifices of the nasolacrimal duct. It also shows the lower edges of the middle and superior concha, and the roofs of the antra. Attached to the roof of the right maxillary sinus are two abnormal bony growths generally known as osteophytes.
Fig. 178-179. Cryer's Internal Anatomy of the Face.

1023.410 Lateral section showing the relation between the condyloid process of the mandible and the mandibular fossa, the external acoustic meatus and the parotid gland.
Fig. 63. Cryer's Internal Anatomy of the Face.

1023.411 Lateral wall of nasal cavity, with large sphenoidal sinus. Anteroposterior division through the centre of the orbit, maxillary sinus, and molar teeth, showing a large maxillary sinus and a large sphenoidal sinus.
The sphenoidal sinus extends laterally until it forms the cavity posterior to the maxillary sinus.
Posterior to the maxillary sinus we find another sinus of a different character, which, from superficial examination, might be thought to be related to it or to be an enlarged cell belonging to the palate bone, a probe passed into it leads to the supreme of fourth meatus of the nose, indicating that it may be related to or connected with the sphenoidal sinus. In Fact, it is a very large sphenoidal sinus extending out laterly in a line almost to the outer part of the maxillary bone.
Fig. 174-216. Cryer's Internal Anatomy of the Face.

1023.412
1023.412(A)
1023.412(B) Transverse division of a mandible at the lateral foramina. The left side is in an almost normal condition, while on the right side the corticle bone has thickened and become dense, and the cancellated tissue has become filled with secondary bone.
Fig. 45. Cryer's Internal Anatomy of the Face.

232-16

1023.413 Not identified.

1023.415
1023.415(A) Anteroposterior division through the orbit, frontal and maxillary sinuses, and molar teeth, showing an undeveloped molar which was causing irritation in the floor of the sinus.
Fig. 219-220. Cryer's Internal Anatomy of the Face.

1023.416 Ground section of the six anterior teeth and two left pre-molars.
The specimen was prepared by grinding away the labial and lingual surfaces of the bone and teeth until the pulp chambers and apical foramina were exposed on both sides of the teeth, leaving the tissues extending out of the foramina and through a portion of the bony cribriform tube below. In one tooth the lateral wall has been broken away, leaving the tissues uncovered by hard structures on the three sides. It will be seen that the nerve has been pushed slightly away from the wall. In this dissection and in many others it will be observed that the tissues passing into the teeth give off small branches from the nerves and vessels just below the apical foramen.
Fig. 36. Cryer's Internal Anatomy of the Face.

1023.417 Two anteroposterior sections made by dividing the orbit and maxillary sirus vertically, showing conical elevations over the roots of the various teeth. The root of the second premolar curves forward. It more commonly curves backward.

1023.418 Sequestra from a mandible produced by the use of hydrogen peroxide.
Produced by injecting hydrogen peroxide into a diseased mandible, the bone in each of these cases regenerated.
Fig. 39, Cryer's Internal Anatomy of the Face.

1023.419 A vertical anteroposterior division through the frontal sinus, orbit and maxillary sinus, showing a partial anteroposterior membraneous septum of the sinus. Situated on the membrane are a number of small osteophytes.
Fig.206. Cryer's Internal Anatomy of the Face.

1023.420 A common form of impacted lower third molars.
The external portion of the bone covering the tooth has been removed in one case, the internal portion of the other. In both cases it will be observed that the mandibular canal is encrouched upon. It is often

necessary to cut away a portion of the bone with the surgical engine before a tooth so situated can be removed. 232-17
Fig.159-160. Cryer's Internal Anatomy of the Face.

1023.421 Two halves of the same mandible, showing two
1023.421(A) impacted third molars. The left one is nearly horizontal, while the right one is badly "locked" under the posterior portion of the second molar. x-ray shows considerable thickening of the tissue around the roots.
Fig. 336-337-338. Cryer's Internal Anatomy of the Face.

1023.422 Mandible of aged person, showing a greater change from that of adult life.

1023.423 An impacted mandibular third molar, and a mandibular third molar with curved and thickened root, both belonging to the same jaw. The bone is much more compact than normal bone.
The impacted tooth is pushing directly against the tooth in front of it. The roots of this tooth have also become enlarged by deposits cementum, while the surrounding bone has thickened and grown more compact. This is the left half of the previous specimen.
Fig. 168. Cryer's Internal Anatomy of the Face.

1023.424 An impacted mandibular third molar, and a mandibular third molar with curved and thickened root, both belonging to the same jaw. The bone is much more compacted than normal bone. The roots of the third molar curved backward at almost a right angle, and enlarged by an abnormal deposit of cementum until the independent character of the roots is lost, the two being fused together.
Fig. 167. Cryer's Internal Anatomy of the Face.

1023.425 Lateral wall of a left nasal cavity, with the middle concha and portion of the cell walls turned up. This gives a general idea of the arrangement of the outer walls of the nasal cavity. The upper portion, or all of that which belongs to the ethmoid bone, is associated with olfaction. The ends of the nerves, usually called the terminals, have their origin over this region; they also are distributed over the upper portion of the septum and the roof of the nose. The fibers converge as they pass upward to form the filaments, and then through the various foramina in the cribriform plate of the ethmoid bone enter the olfactory bulb. The various meati have communications with the maxillary sinus and other air spaces which are formed in the bones of this region.

The ethmoid bone cut loose and turned up, affords a good idea of the normal anatomy of this region. The frontal sinuses are exposed. In the illuastration the right frontal sinus extends over the left side of the medial line; the open space immediately below this is the left frontal sinus. The partition between these sinuses in some places is thin. The lower portion of the left frontal sinus is funnel-shaped. This opens a passage leading into the middle meatus, the funnel-shaped portion and the passage being commonly called the infundibulum. This illustration also gives a good idea of the nasal surface of the partition between the maxillary sinus and the great extent of the mucous lined sinuses and cells that are so directly related with it. When these pneumatic spaces become diseased, it is almost impossible to keep the sinuses in hygienic condition, and when the infection reaches them, they are much more difficult to treat and drain than when the disturbance comes from the teeth or alveolar porcess. The reverse side, an anteroposterior section near the inner wall of the orbit, shows a maxillary sinus of about the average size for the age of the subject. A portion of the lumina papyracea or os planum is cut away to show the continuation of the outlet of the sinus. A partial bony septum arising from the floor and passing transversely across forms two deep pockets.
Fig. 172-180-204. Cryer's Internal Anatomy of the Face.

1023.426 X Anterior view of a skull with frontal sinuses extending f om within the great wing of the sphenoid bone forward to the frontal bone then backward to the left sphenoid bone.
Fig. 254-255-256. Cryer's Internal Anatomy of the Face.

1023.427 X Two specimens of an impacted lower third (molar). The first specimen shows tooth in position; the second shows the tooth removed from its socket. Part of the posterior root of the second molar has been resorbed, exposing the root-canal, more than likely causing the devitilization of the tooth and thus producing neuralgia, induced by the pressure of the impacted tooth.
The enamel of the second impacted tooth is somewhat lost by friction against the second molar. The roots of the impacted teeth have a slight curve inward at their points; the concavity fits immediately over the alveolar of the mandibular nerve, and has probably caused pain by pressure. The terminations of the roots are not fully formed, the apical opening being large; it will also be noticed that the roots of the teeth in the jaw are longer than usual, that of the canine, for example, passing

below the alveolar or mandible nerve.
Fig. 161-162. Cryer's Internal Anatomy of the Face.

1023.428 Common form of impacted mandibular third molar.

1023.429(A, B,C,D,E,F,G) Sections made at different points from a mandible which was not quite normal in its density. In some of the sections only one canal is seen, while in others several appear, necessitating close observation to decide into which the main nerves and vessels have passed.
Fig. 59. Cryer's Internal Anatomy of the Face.

1023.430 Part of the mandible, showing the roots of the third molar tooth passing through the inner wall into the sub maxillary fossa. A putrescent pulp in this tooth would have discharge its infective molar at once into the submaxillary triangle.
Fig.60. Cryer's Internal Anatomy of the Face.

1023.431 An impacted mandibular third molar. The molar is in the ramus of the jaw, just below the anterior portion of the mandibular notch, the tooth being inverted. In this case the capsule of the germ of the tooth became adherent to the walls of the jaw, and lost its position within the forming cancellated tissue, when the body of the jaw grew downward and forward.
Fig. 156. Cryer's Internal Anatomy of the Face

1023.432 A mandible showing an inverted lower third molar erupting into the right submaxillary.
Fig. 169. Cryer's Internal Anatomy.of the Face.

1023.433 Xray of the specimen shows impacted lower rudimentary fourth molar.
Fig. 339. Cryer's Internal Anatomy of the Face.

1023.434 An impacted mandibular third molar. The molar is situated on the inner side of the jaw and pointing slightly downward. The posterior root of the second molar is slightly resorbed. Upon covering the tooth and taking it from its crypt, it was found to be incased in a thin shell of bone, as though the dental capsule had ossified separately around the tooth. The inner portion of the shell is still in position, the nerve and its accompanying tissues are seen passing into the mandibular foramen and immediately under or against the shell. Here must have been an obscure case of neuralgia. Fig. 165-166 Cryer's Internal Anatomy of the Face.

1023.435 Dentigerous cyst of right mandible in the molar region.

1023.436 Anterior view, showing a large right frontal sinus, the left sinus is very small. Posterior view of a vertical transverse section in the region of the ostium maxillare. From the skull of an aged person. The floor of the nasal cavity, the alveolar process and the floor of the sinus are nearly on the same level. The left maxillary sinus extends upward through the region of the anyerior ethmoidal cell into the frontal sinus without a line of demarcation between them. The right sinus is extremely large, extending from the right zygmatic process over toward the left and measuring 67 mm., leaving but a single space for the left frontal sinus, which measures 15 mm. The septum between these sinuses had an inclination of about 45 degrees The right sinus also extends well back over the orbit and into the crista galli.
Fig. 250-296. Cryer's Internal Anatomy of the Face.

1023.437
1023.437(A) Body of a typical mandible. The occluding surfaces of the sixteen mandibular teeth are in good alignment; the outer surfaces of the buccal cusps have an outward inclination which allows the buccal cusps of the maxillary teeth to occlude over them.
Fig. 109-119. Cryer's Internal Anatomy of the Face.

1023.438 Horizontal section through the orbits, ethmoid cells and sphenoidal sinuses. The sphenoidal sinuses are large with a slightly curved septum between them. Cross sections of the cartoid canal may be seen posterior to the sinuses.
Fig. 258. Cryer's Internal Anatomy of the Face.

1023.439
1023.439(A) A vertical transverse bilateral section of a negro skull showing a deep alveolar process. The greater thickness of the floor of the maxillary sinus and the position of the roots of the teeth are note worthy. In the negro race the walls and floor are much thicker than in the white; therefore as a rule, the roots of the teeth do not pass up into the wall, or even near the floor of the sinus.
Fig.200. Cryer's Internal Anatomy of the Face.

1023.440 Anteroposterior division through the centre of the orbit, maxillary sinus, and molar teeth, showing a peculiarly shaped sinus. This specimen was taken from a negro's skull. The crescent shaped cell opens into the superior meatus.
Fig.212. Cryer's Internal Anatomy of the Face.

1023.441 A,B,C,D, Horizontal sections of the maxilla and mandible cut a little beyond the free margin of the alveolar process, showing the forms and positions of the roots of the various teeth.
The conditions here shown are so common as to warrant their classification as the normal type. Particular attention is drawn to the slight distance between the roots and the plates of the alveolar process.
Fig. 43. Cryer's Internal Anatomy of the Face.

1023.442 1023.442(A) Specimen showing the roof of the nasal cavity and the maxillary sinus, also the floor of the anterior fossa of the brain case and part of the frontal sinuses, to one of which there is no foramen of exit. A horizontal section was made by cutting through the middle of the orbits and the upper part of the nasal cavity. This division shows the diseased condition of the ethmoidal cells and the inner wall of the orbit. These specimens illustrated unilateral occlusion. The division exhibits the downward excavation which has occurred in the occluded sinus. In the lower surface the excavation extending in the direction of the nasal spine. There are marked irregularities in the ethmoidal cells of the two sides. The floor of the brain case shows a perforation at the point indicated by the thread passing through it. It is reasonable to suppose that the retained fluids have burrowed through the cribriform plate, causing the perforations. The crista galli in the specimen is bent downward until almost flat by what has evidently been a cyst or tumor within the brain-case in this region. Unfortunately, the writer was unable to obtain antemortem or postmortem notes of these cases. It might be supposed, however, that the patient presented cerebral symptoms, In confirmation of this idea, there was evidence in the condition of the skull that there had been a postmortem examination. The effects of the encrouchment of the inflammatory and necrotic condition are shown upon the internal wall of the orbit .
Fig. 189-190-191-192-193. Cryer's Internal Anatomy of the Face.

1023.443 Part of a mandible.

this valve, at the outlet of the lachrymal sac.

10002

No. 2.-Complete arterial system of a seventh month embryo

III. Corrosional Preparations. (Hyrtl)

In black frames, under glass.

Green, polygonal numbers.

"My book, which has just appeared: Die Corrosions-Anatomie, Vienna, 1873, 4°, with eighteen plates, in which the history technology and scientific results of corrosion are ~~tested~~ treated in full, allows me to give in few words an account of the series of preparations which lies before ~~me~~ us.

A third of the objects exhibited under this head include the originals of the plates in my book, just named; -the other preparations, whose pictorial representatives would have been too expensive for me, represent completely new discoveries in the department of angiology and the structure of glands.

10001.

No. 1. Preparations of spirals of the lachrymal duct and the spiral valve of the lachrymal sac. I have already, in the work just mentioned, pointed out the part which the spiral plays in the vascular and lymphatic systems. The preparations exhibited in No. 1. display also the significance of the spiral in the excretory lachrymal ducts. There are eight of them as follows: No. 1. spiral lachrymal duct, aet. 20. -No. 2. -aet. 40, female. -No. 3. -aet. 70. -No. 4. remarkable shortness of the lachrymal duct, with a spiral of three turns. -Nos. -5 & 6. -lachrymal duct of all old women. -No. 7. Valvula spiralis of the lachrymal sac. -No. 8. groove corresponding to this valve, at the outlet of the lachrymal sac.

10001.1 10001.2 10001.3 10001.4 10001.5 10001.6 10001.7 10001.8

10002.

No. 2. -Complete arterial system of a seventh month embryo

I find here ~~the~~ occasion to designate this preparation as the most difficult accomplishment in the art of corrosion.

10003. No. 3. Arterial and ~~rendus~~ venous rete mirabile of the digestive organs of sus scrofa (hog).

10004. No. 4. Spirals of the splenic artery of the camel.

10005. No. 5. The same, of the Auer Ox (Bison).

10006. No. 6. The same, of the Zebra and Boar.

10007. No. 7. Pathological conditions of the pelves of the kidneys.

100071. 100072 No. 1. and 2, dilatation of both pelves conditioned by retention of urine through pressure in scirrhus uteri. -No. 3. - 100073 left dilated kidney-pelvis of a woman on whom the Caesarian operation had been performed. -No. 4 100074 and 5, 100075 Pelves of a horse-shoe kidney. 100076 -No. 6. -Senile atrophy. 100077 -No. 7. -and 8, 100078 dilated pelves and ureter in nephrolithiasis in a boy, at 14.

10008. No. 8. Corrosional casts of mastoid cells of the temporal bone, as proof that so far as spongy substance is found in this bone, it is filled with air cells. -No. -1 and 2 are air cells of the squamous and temporal bone, injected from the tympanum and eustachian tube. -No. 3 the same, with the external auditory canal and the eustachian tube. No. 4. -air cells of a young temporal bone, with a natural labyrinth in situ, for judging its local relation to the cells. -Nos 5 and 6. - Tympana, injected from the Eustachain tube, with the air cell near it. -Nos. -7, 8, and 10. -casts of external auditory canals as representatives of unusual shortness and length of this canal. -No 9. -Cast of the tympanum, mastoid cells and eustachian tube, of a child at 12.

10009. No. 9. Proof for the natural divisibility of the kidneys. Dorsal and ventral halves of a human kidney, laid asunder, with the pelves of the kidney* in situ, and with the nutrient artery of the pelves; the last is wanting in a tuft, and so is

* Put in paragraph marked next page

distinguished from all other branches of the renal artery. 8

10010 No. 10. Left kidney of a Bos taurus. Artery and ureter.

10011 No. 11. Right kidney of the same animal. Artery, vein and ureter very considerable nutrient artery of the pelves.

10012 No. 12. Left kidney of the Auer Ox. Arterial injection, with numerous perforating branches for the adipose capsule.

* Hyrtl, das Nierenbecken der Langethiere and des Menschen, with VII. Plates. Vienna 1870, Where also are to be found more detailed statements concerning the exhibited preparations of kidneys.

10013 No. 13. Left kidney of a horse. Artery and ureter.

10014 No. 14. left kidney of the rhinoceros. Artery and spiral ureter.

10015 No. 15. Kidney of the Tajassu. The ventral half has been removed in order to show the position of the pelvis which has been many infundibula.

10016 No. 16. Kidney of the hedge-hog Artery and ureter. Dorsal and ventral halves of the kidney laid asunder.

10017 No. 17. Right kidney of Ovis strepsiceros. Artery and ureter.

10018 No. 18. Left kidney of Ovis Musimon. Course of the primary branch of the renal artery into the furrow between the leaf shaped infundibula of the pelvis channel of the kidney.

10019 No. 19. Kidney of Arctomys Empetra. Artery and vein. Oblique position of the left kidney.

10020 No. 20. Kidney of Felis Eyra. Artery and vein. Superficial nervous system of the same.

10021 No. 21. Natural divisibility of the kidney of the Lagomys. Artery and ureter.

10022 No. 22. Right kidney of a hyena. A retry and vein. Superficial system of veins as in the cat tribe.

10023 No. 23. Left kidney of the same animal. Artery and ureter. Dorsal half of the kidney removed, to give posterior view of the pelvis of the kidney having numerous leaves.

10024 No. 24. Ramifying ureter of the Seal (left kidney). # 74 Case

10025 Case 77 Sec. D. No. 25. Different forms of the human pelvis, of the kidney No. 1 of the Negro. -Nos. 2 and 3, of a pregnant woman. Nos. 4 and 5, Asymetry of the left and right pelvis of the kidney, from a man, act. 40. -No. 6. left kidney with double ureter and pelvis Nos. 7 and 8, pelvis of a kidney of a new-born child.

10026 Case 77 Sec. D. No. 26. Pelvis of a kidney of a horse, with both tufts of urinary canal of Bellini.

10027 No. 27. -Pelves of kidney of Anubis (Canis anubis (Egyptian dog)) (left) Lutra (otter) (right) Halicore (Dugong) (left) Giant Kangaroo (left) and Cebus (left) ~~Lutra~~ No 27-31 furnish proofs for the law that ~~not all~~ where kidneys of mammals are not lobular the ~~possess a~~ pelvis is laminated ~~with many leaves~~ (blätterreich) or in the form of leaf-like folds while lobed kidneys as nos. 10, 11, 24 possess ~~while a tree-shaped ramifying ureter~~ branch-like urineferous tubules with numerous terminal calices ~~calices belongs to the kidneys.~~

10028 Case 77-D. No. 28. Pelves of kidneys, of the Coypu (Myopotamus coypu, a S. American rodent.) (right) pangolin (right) (Scaly anteater) Ariranha (left) Llama (right) Macacus (monkey) (right) and blue fox (left).

10029 Case 73 No. 29. Pelves of kidneys of the wild goat (right) Boselphus (left) and Argali (Siberian wild sheep) (right): the last with the nutrient artery of the pelvis.

10030 Case 77 Sec. D. No. 30. Pelves of kidneys of the Tiger (right) ~~diomediiy~~ Dromedary (right and leopard (right).

10031 Case 77 Sec. D. No. 31. Pelves of kidneys of the gepard (cheetah (felis jubata)) (right) of the giraffe (left) and of the lion (left).

10032 No. 32. Left kidney of the gnu, naturally divided. Spiral twisting of the ureter ~~through~~ about the interial spermatic artery.

10033 No. 33. Spleen of the Mufflon. Spiral arteries.

10034 No. 34. Human Ductus Wirsungianus.

10035 No. 35. Liver of a child, Artery, Portal veins, hepatic veins. - The left hepatic artery is lacking, since it sprang from the mesenteric. Narrowing of the umbilical vein before its discharge into the left branch of the portal vein.

10036 No. 36. Portal vein system of a child of 10 months.

10037 No. 37. Human liver, Artery portal vein, cystic ducts.

10038 No. 38. Spiral of the cystic ducts of the horse(new ~~hom~~ born).

10039 No. 39. Liver of the ~~ownang~~ ourang-outang-ontang Artery. portal vein, and cystic ducts.

10040 No. 40. Biliary ducts of the swan. The hepato-cystic duct(A)is (as corrosion has shown generally in birds)a true continuation of the right branch of the hepatic duct. Median stricture of the gall bladder. Cystic duct (C)without winding.

10041 No. 41. Liver of a new-born Jaguar. Artery, hepatic veins, and biliary ducts. Pretty spiral of the cystic duct.

10042 No. 42. Arteries of the tongue. Without any reciprocal anastomosis.

10043 No. 43. Appendix pylorica from Acipenser ruthenus.

10044 No. 44. Arteries of the hand.

10045 No. 45. Arteries of the foot. ~~Surprising~~ Remarkable richness of the ends of the toes in short arterial spirals.

10046 No. 46. Plexus of arteri~~o-nervous~~venous spirals of the lumbar vertebral column of a child. Perforating arteries of the vertebral bodies.

10047 No. 47. Unrolled Vesicula ~~semuialis~~ seminalis, with the gland end of the Vas deferens (A)and an accessory seminal vesicle at the ejaculatory duct.

10048. No. 48. Pulmonary artery of the ~~Omonry ontary~~ ourang outang.

10049. No. 49. Pulmonary artery and bronchial artery of the right inferior lobe of a human ~~lung~~ lung. Net like surrounding of the bronchial artery around the pulmonary.

10050. No. 50. Pulmonary artery and bronchial artery of the laft lung. From Prosector Dr. Friedlowsky.

10051. No. 51. Lung of a new-born lion. Artery.

10052. No. 52. Ramification of the bronchus and the bronchial artery.

10053. No. 53. Lung of a mountain goat. Ramification of the bronchus and the pulmonary artery. From Dr. Friedlowsky.

10054. No. 54. For the angiology of fishes. Arterial system of the gill of the Esox. Roots of the ~~dorte~~ aorta and ~~pearl stringed formed~~ aorta of Tinca in the form of a string of pearls. Arteries of gills of the Eel. with only three arches. -Trunk of the bronchial artery of tinca turned spirally. ~~So~~ Also of an Alburnus white-fish. Bladder of Luciscus minnow with two horns.

10055. Nos. 55, 56, and 57 very fine specimens of corroded placenta.
10056.
10057. The last is that of a gypsy.

IV. Normal and abnomal Arrangement of the blood-vessels of the Human Placenta.

Uncovered, ~~Open~~, on black boards.

Yellow, rhombic numbers.

In the short time which has elapsed since the appearance of my work: "Die Blutgefasse der menschlichen Nachgeburt" Vienna, 1870 with twenty plates, my collection of Placentae has become ~~grone~~ richer by the addition by some beautiful specimens, which now confirm the anatomical statements in this book and now bring to completion and enlargement through new preparations the statements already made. In order to make known the latter they are added to my collection of exihibited specimens. Ihave selected only those cases, which though the rarity of their occurence, may lay claim to special value, and therefore must ~~much~~ interest in like degree both the practical obstetrician ~~instrtrician~~ and the anatomist.

Placentae of strange races of men, to become possesed of which is truly no easy task, are added as curiosities.

1090.750
1638
58

No. 1. Placenta of triplets. 2 ♂ ~~25~~; -1 The male sex is in this and all following placentae, shown by a golden, the female, by a silver mark. The placenta of both the male products of conception (A. B.) possesses a single chorion and amnion. Well marked anastomoses between the arteries of both umbilical cords, with three little bulbi. The placenta of the female foetus (C) shows a marginal insertion of the umbilical cord; the last with parallel arrangement of the blood vessels. Opposite the insertion of the unbilical cord, each unbilical artery makes a large single, twisted noose, Mother prim ~~puni~~para, Normal labor.

1090.7502
~~1639~~
50

No. 2. Triplets. 2♀; 1♂. The placenta of both the female foetuses possesses a single chorion and amnion. Multiplied anastomosis between the arteries of both umbilical cords. Insertion of the one umbilical cord is marginal. Spurious arterioso-venous knot on the same. Perceptible valve strictures* on the arteries. The female placenta has grown with the male(C) and is separated from it by a strong septum (orange 1-2) Second pregnancy of mother. Normal labor.

1090.7503
~~1640~~
50

No. 3. Placentae of twins, with double chorion and amnion. A, female, B, male. The Septum (orange 1-2) does not run between the two placentae, but off from the margin of that of the female which in this case is always found without vessels.

1090.7504
~~1641~~
50

No. 4. Placenta of twins of a negress. Foetuses, ♂♀. Single chorion with septum (orange 1-2) double amnion. ~~Untimely~~ Premature birth in the seventh month. Placenta together with the embryo received through Dr. Schwarz in Rio de Janeiro.

1090.7505
~~1642~~
50

No. 5. Placenta of twins, A single chorion, A. B. 2 amnion Foetuses ~~timely~~ full term, and male, Multiplied vascular anastomosis between the two umbilical cords, one of which (with marginal insertion) is twisted to the right. ~~Vesailar~~ Vascular anastomosis between both umbilical cords coexists always with likeness of sex in the twins. Both foetuses at full term. Breech-presentation of one of them. Fourth pregnancy.

1090.7506
~~1643~~
50

No. 6. Placenta of twins. Foetuses ~~timely~~ full term, ♂♀. Double chorion and amnion, grown together only in the breadth of an inch, A septum (yellow 1-2) goes away sharply from the place where they are grown together, Nodus pampiniformis on the unbilical cord of the female foetus, B. Labor normal. Mother in second pregnancy

*Hyrtl, above mentioned book, page 12.

Twins also in the first prenancy.

1090.7507 ~~1644~~ 50 No. 7. Placenta of twins. Of the two ovnms one, (B), caused, through Hydrammnios, the absorption of the other, from the fourth month on. The struggle for existence therefore began in the womb. The embryo of the obsolete ovum digested, so to speak, even to the bones, with several separations in the bones of the skull, in consequence of the compression? The second empryo, male and at full term, came living into the world. Clinic of Prof. Spath.

1090.7508 ~~1645~~ 50 No. 8. Placenta of twins with septum (1-2). Foetuses . The male empryo (B) at full term and living; -the female (A) of the fourth month, died, unly slightly macerated. Was held to be Superfoetation

1090.7509 ~~1646~~ 50 No. 9. very fine specimen of an Insertio velamentosa of the unbilical cord, whose vessels impinge in five different places on the placente, Unbilical cord wound around to the right. Placentula succenturiata obsoleta on the under side of the placenta. Instrumental birth. Mother primipara.

1090.7510 ~~1647~~ 50 No. 10. Double placenta of a single child. Velmentary insertion of the unbilical cord. This case of a complete division of the placenta is among the greatest rarities. It occured in Prof Braun's clinic.

1090.7511 ~~1648~~ 50 No. 11. An unbilical cord 1.62 meters (65 inches) long, with a single unbilical artery. A single and a double-tied time knot on the same. The unbilical cord had been wound round the neck five times, and twice around the left schoulder of the child Succesful untying of the same, Foetus male, living, at full term

1090.7512 ~~1649~~ 50 No. 12. Placents of a South Sea Islander, with a noose on both unbilical arteries, twisted six times. Received from my friend Dr Strangerwald of Hawaii. -Marginal insertion of the ~~funnculas~~ ~~funiculus~~ cord.

1090.7513 ~~1650~~ 50

No. 13. Placentitis with circular exudation wall (Annulus fibrosus Buschii) Mother in second pregnancy, syphilitic. The large ramifications of the umbilical vessels belong only to the placental surface which is surrounded by the annulus.

1090.7514 ~~1651~~ 50

No. 14. Placenta at full term with unbilical cord twisted to the right, and a very considerable Cor placentare. -Premature birth. Foetus female, dead.

Hyrtl. Bulbi der Placentar-Arterien, Vienna 1869

~~1652~~ 50 1090.7515

No. 15. Placenta at full term of a Maori woman (New Zealand) with parallel course of the umbilical vessels throughout. (This undeniable likeness to monkeys of the placenta surely does not coincide with the intelligence of the race of the Maori) I received this remarkable placenta from Port-Auckland through the kindness of Dr. Edw. Mac-Culloch.

1090.7516 Placenta unidentified

1090.7517 ~~1653~~ 50

No. 17. Heart-shaped placenta of a Hottentot woman. From Cape Town, received from Dr. Henry Nortwyk. Surely no resemblance to monkeys.

1090.7518 ~~1654~~ 50

No. 18. Placenta of a Malay woman (from Dr. Edgar Norris, from Samarang) Unbilical cord twisted to the right, with marginal insertion, and a long false arterial knot.

1090.7519 ~~1655~~ 50

No. 19. Placenta at full term, with a Cor placentare of especial size, -Breech presentation.

1090.7520 ~~1656~~ 50

No. 20. Crenated Placenta, with varices of the unbilical vein. Hemicephalus. Abortion.

1090.7521 ~~1657~~ 50

No. 21. Placenta with absence of one of the unbilical arteries. Male, foetus at full term, with club feet. Difficult labor. Version by the feet.

1090.7522 ~~1658~~ 50

No. 22. Large placenta in the form of the figure 8, with Decursus (twisted partly to the right, partly to the left) of the unbilical vessels. Strongly marked.

Hyrth, Bulbi der Placentar-Arterien, Vienna, 1869.

1090.7523
~~1659~~
50

No. 23. Planenta with absence of anastomosis of the umbilical arteries. Both unbilical arteries are injected with differently colored material. Abortive birth in the eighth month, Mother sick with small-pox.

1090.7524
~~1660~~
50

No. 24. Trunk of an abortion of six months, with umbilical cord and placenta.

25

2 579

2059

1024.06 Atlas
1024.07 Atlas and axis. → Presented by Dr. John H. Brinton

1024.11 cervical vertibra — Presented by Dr. John H. Brinton

1025.12 Vertebrae Column

1025.15 spinous process of cervical, dorsal and lumbar vertibrae — Presented by Dr. John H. Brinton

1025.20 Portion of vertibra — Presented by " " " "

1025.56 Dorsal vertibra — Presented by Dr. John H. Brinton
1025.57 " " — " " " " " "
1025.58 " " — " " " " " "

1025.61 Dorsal vertibrae vertical section — Presented by Dr. John H. Brinton
1025.62 " " " " — " " " " " "
1025.63 " " " " — " " " " " "
1025.64 " " " " — " " " " " "

1025.68 Horizontal & Vertical section of vertebra Mounted on one board
1026.31 " " (Page 263 - up where on page)

NORMAL ANATOMY.

1025

1024. cervical vertibrae — Presented by Prof. George McClellan
102405 Atlas — " " " " "
1024.10 cervical vertibra — " " " " "
1024.15 " " — " " " " "
1024.20 " " — " " " " "
1024.25 " " — " " " " "
1024.30 " " — " " " " "
1025.00 vertibrae column & ribs — Presented by Prof George McClellan
1025.05 vertibrae column — " " " " "
1025.10 " " — " " " " "
1025.25 two dorsal vertibrae — " " " " "
1025.30 dorsal vertibrae — " " " " "
1025.35 " " — " " " " "
1025.40 " " — " " " " "
1025.45 " " — " " " " "
1025.50 " " — " " " " "
1025.55 " " vertibrae — " " " " "
1025.60 " " — " " " " "
1026. Lumbar vertibrae — Presented by Prof. George McClellan
1026.05 Lumbar vertibra — " " " " "
1026.10 " " — " " " " "
1026.15 " " — " " " " "
1026.20 vertical section of lumbar vertibra — " " " " "
1026.25 Lumbar vertibra — " " " " "
1026.26 Lumbar vertibra — Presented by Dr John H. Brint
1026.27 " " — " " " " "
1026.28 " " — " " " " "
1026.29 " " — " " " " "
1026.23 " " — " " " " "

1030.01 Rib Presented by Prof. George McClellan
1030.02 " " " " "
1030.03 " " " " "
1030.04 " " " " "
1030.05 " " " " "
1030.06 " " " " "
1030.07 " " " " "
1030.08 " " " " "
1030.09 " " " " "
1030.10 " " " " "
1030.11 " " " " "
1030.12 " " " " "
1030.13 " " " " "
1030.14 " " " " "
1030.15 " " " " "
1030.16 " " " " "
1030.17 " " " " "

1030.18 Rib Presented by Prof. George McClellan
1030.19 " " " " "
1030.20 " " " " "
1030.21 " " " " "
1030.22 " " " " "
1030.23 " " " " "
1030.24 " " " " "
1030.25 " " " " "

following 204 = 564

1030.26 Rib Presented by Prof. John H. Brinton
1030.27 " " " " "
1030.28 " " " " "
1030.29 " " " " "
1030.30 " " " " "
1030.31 " " " " "
1030.32 " " " " "
1030.33 (A) " vertical sec. " " McClellan
1030.33 (B) " " " " "

1032.15 (A) horizontal section of clavicle Presented by Prof. George McClellan
(B) " " " " " " " " "
1032.20 Clavicle " " " " "
1032.25 " " " " "
1032.30 " " " " "
1032.35 " " " " "

1033. Scapula Presented by Prof. George McClellan
1033.05 " " " " "
1033.10 " " " " "
1033.15 " " " " "
1033.20 " " " " "

1034.25 (A) Vertical section of head of humerus Presented by Prof. George McClellan
(B) " " " " " " " " "
1034.30 (A) Vertical section of humerus " " " " "
(B) " " " " " " " " "
1034.35 Humerus " " " " "
1034.40 " " " " "
1034.45 " " " " "
1034.50 " " " " "
1034.55 Humerus " " " " "
1034.60 " " " " "
1034.65 Humerus. " " " " "
1037.10 (A) vertical section of radius Presented by Prof. George McClellan
(B) " " " " " " " " "
1037.15 Radius " " " " "
1037.20 " " " " "
1037.21 " transverse section of carpal end Presented by Dr. John H. Brinton
1037.22 " vertical " " " " " " " " "
1037.23 " " " " " " " " "
1037.24 " " " " " " " " "
1037.25 " " " " " " " " "
1037.26 " " " " " " " " "
1037.27 Radius and one dorsal and lumbar vertibrae Presented by Dr. John H. Brinton.
1033.315 Carpal portion of Rt. clavicle

~~1[illegible] Carpus & [illegible]~~

1044.26 Bones of the hand Presented by Dr. John H. Brinton.
1044.25 Bones of the hand articulated Presented by Prof. George McClellan
1044.50 " " " " disarticulated " " " " " " " " "
~~51 Hands showing nerves and arteries~~
vol. I. p. 308

564 Sec 9 Shelf 3

NORMAL OSTEOLOGY.

31
1025-1026- Horizontal and vertical sections of vertebrae.—

1027.05 (A) Vertical section of the sacrum. Presented by Prof. George McClellan
1027.05 (B) " " " " " " " " "
205 1027- Vertical section of the sacrum. Presented by Prof. George McClellan
Sec 9 Shelf 3 1029. Sternum " " " " " " " "
1029.05 " " " " " " " "
1029.10 " " " " " " " "

206 1032- Longtidunial sections of a clavicle.
207 1032.05- " " " " "
208 1032.10- " " " " "
Sec 9 Shelf 3

209 1034- Vertical section of the superior half of the humerus
210 1034.05 " " " " " " " " "
211 1034.10 " " " " " " " " "
Sec 9 Shelf 3

212 1034.15 Vertical section of the lower part of the humerus; lateral.
Sec 9 Shelf 3

213 1034.20 Vertical section of the condyles of the humerus; antero-posterior.
Sec 9 1034.70 Humerus.
Shelf 3

+ 280 Section 9 Shelf 4
214 1035- Bones of the shoulder-joint. Showing ligaments. ~~articulated by dried ligaments~~
Sec 8 Shelf 4
1035.05 Vertical section of the shoulder-joint.
281 1037- Vertical section of the extremities of the radius.
Sec 8 Shelf 3
1037.05 " " " " " " " "
Sec 8 Shelf 3 1038. " " " " " " " ulna.
1038.05 Ulna Presented by Prof. George McC[illegible]
216 1038.10 " " " "
Sec 9 Shelf 3

1039 Vertical sections of the humerus, radius, and ulna
217 See page 264
Sec 9 Shelf 3 1039.05 of a child. Radius and ulna articulated

218 1040 Section of the wrist-joint and hand.
Sec 9 1040.05 wrist-joint, - radius, ulna, carpals, metacarpals and first [illegible] Presented by Dr. Joh[illegible]
1040.10 Bones of the forearm and hand. " " "
1040.15 Vertical section of radius, carpal end.
1044 Bones of the hand.
1040.15 see vol I Page 454
1040.20 " " I in 454
Shelf 3

243 Sec 9 Shelf 3

Presented b[illegible]
Showing Hutchinson [illegible] with — [illegible]

1045.40 Ilium
1045.45 Ilium 267
1046.6 Femur - No donor

237 follows 220
238 (220 - 1)
(220 - 2)

1046.29 (A) vertical section of femur — Presented by Prof George McClellan
1046.29 (B) " " " " " "
1046.30 (a) vertical section of the femur — Presented by Prof George McClellan
1046.30 (B) " " " " " "
1046.35 Femur " " " " " "
1046.40 " " " " " "
1046.41 " " " " " "
1046.42 " " " " " "
1046.43 " " " " " "
1046.44 " " " " " "
1046.45 " " " " " "
1046.46 " " " " " "
1046.47 " " " " " "
1046.48 " " " " " "
1046.49 " " " " " "
1046.50 " " " " " "
1047.03 Left leg.

#1172 follows
(1172 - 1)

1049.16 (A) vertical section of the head of the tibia — Presented by Prof. George McClellan
1049.16 (B) vertical section of the tibia " " " " " "
1049.35 " " " " " "
1049.40 (A) vertical section of the tibia " " " " " "
1049.40 (B) " " " " " "
1049.40 See Index sheet " " " " " "
1049.45 Tibia " " " " " "
1049.50 " " " " " "
1049.55 " " " " " "
1049.60 missing
1050.00 (A) vertical section of fibula " " " " " "
1050.00 (B) " " " " " "
1050.05 Fibula " " " " " "
1050.10 " " " " " "
1050.15 " " " " " "

1039.01 Radius and ulna — Presented by Dr. John H. Brinton
1039.02 " " " transverse section at carpal end of ulna — Presented by Dr. John H. Brinton
1039.03 " " " " " " " " " " " "
1039.04 " " " " " " " " " " " "
1039.05 (348) " " " vertical section of carpal ends — Presented by Dr. John H. Brinton
1039.06 " " " transverse section " " " " " "
1039.07 " " " " " " of radius " " " " " "
1039.08 " " " " " " carpal end of radius — Presented by Dr. John H. Brinton
1039.09 " " " vertical section of carpal end of radius " " " " " "
1039.10 " " " " " " " " " " " "
1039.11 " " " " " " " " " " " "
1039.12 " " " " " " " " " " " "
1039.13 " " " " " " " " " " " "
1039.14 " " " " " " " " " " " "

56.25 Bones of the foot articulated — Presented by Prof. George McClellan
56.50 " " " " disarticulated " " " " " "
56.55 " " " " " " " " Dr. John H. Brinton.

1044.26 B
1044.25 Bolla — Presented by Prof. George McClellan
1044.50 " " " " " "
1057.25 Hands sh — " " Dr. John H. Brinton.
1057.25 vol. I. p. 308 " " " " " "
1057.30 " " " " " "
1057.35 Transverse section " " Dr Drysdale

1057.05
1057.10
1057.15
1057.20
1057.25
1057.30
1057.35

220 (205) (220) Dec 8 Shelf 4 — 1027-1045 — Vertical section of sacrum and ilium.

1045.20 (#237 = Sec 8 Shelf 4) — Vertical section of the ilium and head of the femur.
1045.30 " " " " " " " " " " " "
1045.35 (#238 Sec 8 Shelf 4) — see Page 266
~~1046 Head of the femur.~~

221 1046.02 Sec 8 Shelf 3 — Vertical section of the head of the femur.

222 1046.05 Sec 9 Shelf 4 — The same; showing the epiphyses.

223 1046.10 Sec 9 Shelf 4 — Vertical section of the head of the femur.
1046.11 1172 — " " " " " " " "
224 1046.15 — " " " " lower end of the femur.
Sec 8 Shelf 4
226 1046.20 — " " " " " " " "
Sec 8 Shelf 5
1046.25 — " " " " femur and tibia of a child.
226 1047 — hip joint — innominate (right) portion of vertibrae column and upper portion of femur. Presented by Dr. John H. Brinton
Sec 8 Shelf 4
1048 — knee joint — Presented by Prof George McClellan
1048.05 — knee joint — " " Dr John H. Brinton
227 1049 — Vertical section of the head of the tibia.
1048.10 see vol I Page 454 missing
Sec 8 Shelf 4 — " " " " " " " "
1049.05 — " " " " " " " "
228 Sec 9 Shelf 4
229 1049.10 Sec 8 Shelf 5 — " " " " " " " "
230 1049.15 — " " " " " " " "
231 1049.20 — " " " " lower end of the tibia.
232 1049.25 — " " " " " " " "
233 1049.30 — " " " " " " " "
Presented by Dr T. Hewson Bache
234 1049.35 Sec 8 Shelf 4 — " " " " calcaneum and astragalus.
1053 — Ascalcis and astragalus — Presented by Prof. George McClellan
1054 — Tibia and Fibula — Presented by Prof. John H. Brinton
1052 — Right foot tibia and fibula — Presented " " " " "
1051.10 — ~~Left leg and pelvis~~ (1048.10) missing
1051.15 — Tibia, Fibula and astragalus. Articulated.
236 1056 Sec 9 Shelf 4 — Bones of the foot. — 239 240 241 — 239 + 240 Presented by J Burns Mears
Presented by Dr. T. Hewson Bache.

~~1057~~ ~~Section of a patella.~~

1022 d 244 — 1050

1045.35 Portion of innominate bone Presented by Prof. George McClellan
1045.40 (a) " " " " " " " " "
1045.40 (B) " " " " " " " " "
1045.40 (c) " " " " " " " " "
1045.41 Innominate bone " " " " " " "
1045.42 " " " " " " " " "
1045.43 " " " " " " " " "
1045.44 " " " " " " " " "
1045.45 " " " " " " " " "
1045.46 " " " " " " " " "
1045.47 " " " " " " " " "

1045.50 Pelvis Presented by Prof. George McClellan
1045.75 Innominate and sacrum " " " " " " "
1045.80 " " " " " " " " "
1045.85 " " " " " " " " "

1045.36 Portion of right innominate bone Presented by Dr. John H. Brinton

1045.38 Innominate bone - right " " " " " " "
1045.39 " " left " " " " " " "

1045.48 Innominate bone - right Presented by Dr. John H. Brinton
1045.49 " " " " " " " " "

1048.06 Bones of the Knee joint - Epiphyseal separation caused by plate boiler iron falling against leg, causing simple separation. Later breaking down demanding amputation - Rec. Jan. 22, 1913.

269

1194.40

1194.40

11 50?

[1873 MAR.]

I

Professor Hyrtl's Anatomical Preparations at the World's Exposition in Vienna, 1873.

Preface.

When I learned of the determination to hold a World's Fair in Vienna, I made preparations to make a worthy representation at the same of my own special department of science.

The naming of Anatomy* "the art of dissection" shows the great importance of its technical field of work. The art of the anatomist procures and prepares the material into which the science has to breathe the breath of life.

The productions of anatomy are called "preparations". Without them there is no science of anatomy. The greater the expenditure of the technical skill which has made them, the greater is their sceintific value.

The anatomist stores away the fruits of his practical industry in his museums. These museums make his scientific world, of whose very existence, only professional men take knowledge. In the arrangement of them, he has, as a rule, less to do with the beauty than with the correctness and usefulness of the preparations.

But if it is required of him to place the worksof his hands before the eye and judgment of the public, then he must take care that it shows itself in its prettiest dress, in or-

*Lergiederungskunst.

der that the secret horror which as a rule creeps on the observer of anatomical objects, may be dissolved in acknowledgement and admiration of the beauty and skill of its preparation.

Among the preparations of my collection I have therefore chosen only those which are adapted to be represented in as perfect a form as possible. A correct judgment will acknowledge that apart from the scientific significance of my exhibit, its beauty is raised to unaccustomed magnificence and Anatomy ceases to be the sbarruta scienza of Dante when it appears before the view of the connisseur with such qualities as are here presented to view.

The value of these preparations is increased from the fact that in their use in public instruction, not only is respect inspired for a science which knows how to procure such means of instruction, but also to awaken love for itself; and the talents of many a young man are stirred up to become more intimately acquainted with a department of study which is acknowledged to afford the best and surest, because the eternally true foundation of all his medical studies.

The groups into which I have arranged my exhibition, have to do with:

I.

II. The organs of hearing.

III. Anatomical Corrosions.

IV. The normal and abnomal relation of the vessels of the human placenta.

V. Histology, to which No.

VI. is added, which, in order to assign to strict science

its place alongside of the art, is contained in my anatomical works which have appeared since the last Exposition at Paris.

Since there is contained in my exhibit a great deal that is new and has never before been seen, and which would be impossible to be recognized and understood even by professional men, I have thought the publication of this explanatory catalogue to be necessary.

Vienna, March, 1873.

Prof. Hyrtl.

II. Organs of Hearing.

It required fourteen years to bring together the material the elaboration of which with respect to the organs of hearing, makes up the contents of the two cases, Case 1 - Labyrinth of the ear of man - Mammals - Case 2 - Bones of Hearing - Man and Vertebrate Animals ~~before us.~~ They have already been exhibited in London and Paris, but have since then received some very rare enrichments (of which I will only specially mention the organ of hearing of the Gorilla, one of which is the) and appear therefore lately among the preparations of the my exhibitions.

I. Labrinths of the ear of man and all mammalian families

The first row belongs to man, at different periods of life. It begins with a five-month Embryo, whose outer semicircular canal appears still in the condition of a simple swelling of the vestibule. Its close is the labyrinth of a deaf and dumb girl which is exceeded curiositatis causa, by that of a Hottentot. It is at once Evident from ~~that~~ this row that the labyrinth has already reached its full growth in size and shape in the new born child, as it could not be otherwise with an organ of sense, which, through sounds, through words, as the expression of thought is to have such a very important influence on the spiritual development of man. - The second row contains the labyrinth of the ourang-outang, of the other quadrumana and of the flying dog from Madagascar (Pteropus Edwardsii) In the third and fourth row are found: Gymnura, Euplerest ~~Enplures~~ Latax, Trichecus, as also the prehistoric bear and hyena. The sea-lion which belong here, occupies, as a late addition, the right hand upper corner ~~of the picture.~~ In the fifth and sixth row, (Rodents) the labyrinths with cochlea wound five timesare especially striking. - The seventh row closes with four giant Pachydermata (Tapirus,

Rhinoceros, Hippopotamus, and Elephas) while, in the eighth, the Giraffe and the horse are distinguished for the size and thin ness of their semicircular canals. The three last labyrinths of the last row show the transition from the mammalian type to that of birds. The smallest development (in comparision with the size of the body) belongs to the labyrinth of the Whale and the Dolphin. In the right and lower corner the semicircular calals of a sperm Whale over 22 meters long, from the North Cape are not longer than those of a dog. For animals, which if we except the continued howling of the arctic storm, and the monotonous cry of the gull, have surely few sounds to hear, an undeveloped organ answers their small requirements. When there fore the myth ascribes to the dolphins of the silent sea great susceptibility to the tones of Arion's lyre, so that one of them even had the goodness to take on his shoulders one of the singers who had fallen into the water, and carry him to the shore, it is realy only poetic license with which science does not agree.

The contents of this case lay claim to morphological value alone. Whatever functional differences are conditioned by the changes in the form of the labyrinth, we cannot now even guess, and shall also not learn anything more concerning them to all eternity. -Since the labyrinth is buried in the hardest of all the bones of the skull (so hard, that in certain animals it gives a spark with steel), we cannot attain its representation by the usual means of preparation. The chisel and the file produce only deformities. I have therefore resorted to the corrosion of the canals of the labyrinth:[+] -with what success will be seen in this case of specimens. No other method procures such

[+] Handbuch der praktischen Zergliederungskunst. Vienna 1860, § 143.

a correct view of the capsule of the internel ear. If there were no such thing as corrosion, we would surely know absolutely ~~knew~~ nothing of the labyrinths of the whales, and the large pachydermata, of the edentata and of the prehistoric ~~inamnals~~ mammals. ~~Twelve new labyrinthine canals, of the rarest animals, are represented in Plate XVIII. of my work on Corrosional Anatomy.~~

Case II. chains of the ossicles of the ear, from all kinds of vertebrate animals (in 173 Groups of three and six each)

These chains constitute the organ which conducts the wave of sound from the tympanum or a to the labyrinth. Occasionally an Os tympanicum or a tympanum breaks the monotony of the view. The membrana tympani of the gorilla (in the middle of the lower side of the case) has been artificially restored. ~~I cannot go into a detailed description of these groups of bones, which deserve the careful notice of specialists, since they have never been collected in such neatness and perfection.~~ The tiny ear-bones of the small insectivora, rodents, marsupials and are fastened on green edged elevated blocks in order to bring them nearer the glass of the frame. Views of the human tympanum from within and from without, are placed in the upper corners of the case; tympana of the buffalo and of the embryo of the elephant in the lower.

The value of both cases represents a small fortune,* and whoever would endeaver to bring a simular collection into existence, must first of all fortify himself with patience,

* ~~I mention by~~ way of example the gorilla skull, considerably injured by a shot, was purchased for 1000 francs.

since these great rarities in the way of animal skulls only come by chance into trade, and can ~~also~~ not be ordered. My connection with all anatomists in foreign lands, placed me in a position to procure rare, and, for my purposes, indispensable exotic skulls, in exchange for injection preparations for the microscope. Gifts also have been wanting. It required then a hard resolution to shatter these animal skulls, and to offer them to an anatomical caprice, which took it into head that the organs of hearing of vertebrate animals should no longer remain the most imperfectly known of the organs of sense.

Among those who have aided my work through most valuable presents, Professor Ducrotay de Blainville occupies the place of honor. I am indebted to his liberality for the temporal bones of the Elephas, Rhinoceros, Hippopotamus, Otaria jubata, Physeter, Tiphius and Orca. There is a funny story connected with the petrous portion of the temporal bone of the hippopotamus which I will relate in closing. Since the time of the Roman emperors, no living hippopotamus had come to Europe. The anatomy of the internal organs of this animal remained therefore unknown. Between 1830 and 1840 the French Government sent M. Arnold d'Abbadie as embassador to the king of Seboa. The academy of Paris added to his instructions the request to transmit in a preserving fluid the body of a young hippopotamus. This undiplomatic duty was discharged by the embassador with great tact. The king was greatly afflicted with rheumatism of the joints and addressed the embassador the question whether he could not help him. In the Orient, all Franks are thought to be masters of the art of healing. M. d'Abbadie answered: "Certainly." -Procure the medicine. I'll give

my crown, if I shall become well again." "Not at all necessary: the medicine is found in your own land; it is the fat of a hippopotamus." "-Bring a hippopotamus." "Gently, you must not go so fast it must be the fat of a pregnant little female." Parties of hunters were immediately sent into the savannahs and one of them really brought a pregnant little female. l'Abbadie Smeared the limbs of the king with its fat, and he recovered from his pains: the foetus was however pickled and sent to the Jardin des Plantes, where Blainville allowed me to take out the petrous portion and replace it with a plaster cast. It was in this way that my case became possessed of the labyrinth of the embryo of a hippopotamus.

1059.001 - to - 1059.17

Bones of Hearing. (Ossicles of Ear)

Man and the Vertebrati Animals.

No. 1059.

Genus homo

1059.001 Embryo.

1059.002. Embryo

1059.003 Embryo

1059.004. New born infant; with the temporal bone; exterior.

1059.005 New born infant ; with the temporal bone; ~~en~~ interior.

1059.006 Youth.

1059.007. Old man.

1059.008. Hottentot-Youth.

1059.009. Egyptian mummy.

1059.010. Caries of the incus.

1059.011. Cyclops monster.

1059.012. Anencephalic monster.

1059.013. Bicorporeal Monster.

1059.014. Anomaly of the Stapes.

Dihadrumana.

1059.015. Simia Satyrus (Orang).

1059.016. Hylobates syndactylus (Gibbon) Long armed ape

1059.017. Cynocephalus hamadryas (Hamadryas) Baboon

~~1059.018. Colobus guereza (G~~

1059.019. Cercopithecus pygerethrus (Green monkey).

1059.018. Colobus guereza (Guereza). Black & white African monkey with bushy tail

1059.20 - Theropithecus Gelada - (Abyssinian baboon)

1059.021. (Innuus nemestrinus).

1059.022. (cebus fatuellus). (Cebus, temporal bone) Monkey from Ceylon

1059.023. Mycetes Seniculus (Howler). Monkey

1059.024. Lemur mongoz. (Lemur)

1059.025. Stenops gracilis. (Slender Loris)

1059.26. Tarsius Spectrum. (Tarsius, Spertre).

~~1059.026.~~ 1059.173 Gorilla. Membrana tympani restored (see page)

Chiroptera and Insectivora.

1059.027 Galeopithecus undatus (Flying monkey cat)

1059.028. Galeopithecus rufus; (Colugo) Flying lemur right and left

1059.029. Pteropus poliocephalus (Fruit-eating bat).

1059030. Pteropus edwardsii (Edwards roussette) Pussetfruit-bat.

1059.031 Chiromeles torquatus. (Collared bat of Borneo.

1059.032 Nycteris thebaica (Egyptian bat).

1059.033 Megaderma lyra (India vampire)

1059.034 Talpa europaca (European mole).

1059.035 Chrysochloris capensis (Golden Mole from the Cape of Good Hope).

1059.036 Pachyura indica et etrusca.

1059.037 Chladobates nicobaricus.

1059.038. Erinaceus Europacus. (Hedgehog)

Carnivora.

1059.039. Ursus spelaeus (An extinct bear)(Cave bear Extinct.)

1059.040. Ursus americanus (Black bear).

1059.041. Felis tigris (Bengal Tiger).

1059.042 Lynx canadensis (Canada, Lynx)

1059.043. Lynx vulgaris (Northern Lynx)

1059.044 Catus domesticus (cat)

1059.045. Hyaena crocuta (Spotted hyena)

1059.046. Canis lupus (Wolf)

1059.047 Canis lycaon (Hunting dog)

1059.048 Canis aureus (Jackal).

1059.049. Vulpes lagopus (Arctic fox).

1059.050. Canis familiaris (Dog).

Carnivora and Pinnipedia: (Few-footed aquatic carnivorous quadrupeds.

1059.051. Proteles lanandii (Otogon). and wolf or Earth wolf of So. America

1059.052 Megatotis zerda

1059.053. Lutra brasiliensis (otter Brasilian)

1059.054. Meles taxus (Badger).

1059.055. Ryzaena capensis (Civet or Genet family)

1059.056. Midaus meliceps (Stinking Badger).

1059.57. Thiosmus chilensis

1059.058. Rhabdogale mustelina. (weasel-like animal)

1059.~~059~~ 59 Calocephalus ~~cristatus~~. vitulinus. (Harbor seal)

1059.060. Stemmetopus cristatus. (Harbor seal)

1059.061. Latax stelleri. - (Northern sea-lion)

1059.062. Otaria jubata. (Eared seal).

Rodentia.

1059.063. Hydrochoerus capabara. (South American water-pig) (Capybara).

1059.064. Caelogenys paca. (One of the largest rodents of So. or Cent. America) (Paca). 2ft long 1ft high

1059.065. Dasyprocta aguti. Rodent from So. America (Agouti) Size of a rabbit)

1059.066. Cavia Cobaya (Guinea pig)

1059.067. Hystrix cristata (Porcupine)

1059.068. Erethizon dorsatum (American Porcupine)

1059.069 Castor fiber (Beaver)

1059.070. Myopotamus coypu (Coypu) So. American mammal resembling the beaver.

1059.071. Georhycus capensis (Cape sand mole of South Africa)

1059.072. Bathyergus maratimus (~~Strand~~ Genus of mole-rat) Sand mole from Cape of Good Hope

1059.073. Eriomys Chinchilla.

1059.074. Lepus timidus. (Hare)

1059.075. Haltomys aegypticus

1059.076. Meriones pyramidum (member of the rat family.)

1059.077. Arctomys emperta - wood chuck

1059.078. Sciurus vulgaris (Squirrel)

1059.079. Spermatophilus citillus (Ground squirrel)

1059.080. Sciuropterus volucella (Flying squirrel)

1059.81. Capromys fourneri (member of the rat family)

1059.082. Octodon cumingii (Rat-like So. American rodent)

1059.083. Mus decumanus (Brown rat)

1059.084. Mus musculus (~~Hous~~ mouse. Very minute)

1059.085. Lemmus norvegicus (Lemming A mouse found in high latitudes).

1059.086. Myoxus glis. (Dormouse)

Pachydermata.

1059.087. Sus scrofa (Hog).

1059.088. Monstrum scrofae cyclopicum (Hog).

1059.089. Porcus babyrussa (Babirursa). Wild Swine

1059.090. Dicotyles labiatus (Peccary)

1059.091. Dicotyles torquatus (Collared Peccary)

1059.092 Hyrax capensis(Rock rabbit of the Cape of Good Hope).

1059.093. Hyrax abasjinicus (Coney).

1059.094. Phacochoerus aeliani. (Wart hog)

1059.095. Tapirus malayanus (Malay tapir)

1059.096. Rhinoceros indicus (Indian Rhinoceros)

1059.097. Hippopotamus amphibius. (Hippopotamus)

1059.098. Elephas africanus (African Elephant

1059.099. Embryo elephantis.

Bisulca and Solidungula:

1059.100 Moschus moschiferus (Musk deer)

1059.101. Axis gangetica (Axis deer)

1059.102. Reduncina virginiana. virginia Deer.

1059.103. Cervus elaphus (Stag)

1059.104. Capreolus vulgaris

1059.105. Gazella sommerringii (Gazelle).

1059.106 Ovis musimon (Sheep).

1059.107. Hircus capra. (Goat)

1059.108. Bos taurus. (Ox)

1059.109. Camelus bactrianus (Camel)

1059.110. Camelo pardalis giraffa (Giraffe).

1059.111 Equus caballus. (Horse)

1059.112. Bos bubalus vitulus. (Buffalo)

Edentata: (Toothless)

1059.113. Chlamydophorus truncatus.

1059.114. Bradypus torquatus (collored Sloth

1059.115. Bradypus pallidus (Sloth)

1059.116. Choloepus didactylus (Two toed Sloth)

1059.117. Euphractus Setosus.

1059.118. Xenurus gynnurus (Kabassons)

1059.119. Chloniscus gigas (Long tailed Pangolin)

1059.120. Manis macroura (Scaly ant-eater)

1059.121. Phatages temminchii

1059.122. Myrmecophaga jubata. Ant-eater.

1059.123. Uroleptes bivittatus (African shrikes)

1059.124. Orycteropus aethiopicus. (Ethopian earth-hog

Marsupialia:

1059.125. Macropus giganteus embr. (Kangaroo.)

1059.126. Halmaturus parma. (Kangaroo)

1059.127. Halmaturus brunnii. (Kangaroo)

1059.128. Hypsiprymnus musimus. (Kangaroo rat)

1059.129. Phalangista cookii (Phalanger)

1059.130. Phanangista vulpina.

1059.131. Perameles nasutus (Indian rat) (Bandicoot.)

1059.132. Phascogale flavipes (Yellow footed ponched mouse)

1059.133. Phascolarctos cinercus (Australian bear).

1059.134. Thylacinus harrisii (Pouched dog)

1059.135. Phascolomys wombat. (Wombat)

1059.136. Didelphys quica et virginianus (Opossum)

Cetacea and Monotremata:

1059.137. Phocaena communis (Porpoise)

1059.138. Delphinus selphis (Dolphin.)

1059.139. Tarsio vulgaris. (Lemur)

1059.140. Chenodelphinus rostratus.

1059.141. Delphinapterus leucas (While whale)

1059.142. Monodon monoceros Pale whale with one horn. (Narwhal)

1059.143. Physeter macrocephalus (Sperm whale)

1059.144. Balaena mysticetus. (Green land whale)

1059.145. Halicore cetacea Tusked aquatic herbivorous mammal resembling the whale (Dugong)

1059.146. Manatus australis (Manatee, Largest in the collection).

1059.147. Ornithorhyncus fuscus (Duck-bill)

1059.148. Tachyglossus hystrix. (Echidna). ant-eater

Aves:-

1059.149. Spheniscus demersus. (Penguin.)

1059.150. Diomedea exulans. (Albatross)

1059.151. Balaeniceps rex. (Guillemot)

1059.152. Uria troile. (Slender billed bird of the auk family)

1059.153. Aquila imperialis. (Eagle)

1059.154. Gypogeranus serpentarius (Secretary)

1059.155. Gryphus condor. (Condor).

1059.156. Apteryx owenii. Wingless ratite bird (From New Zealand)

1059.157. Fratercula glacialis. (Puffin - a diving bird)

1059.158. Otis tarda. (Very large webb-footed bird) (Bustard)

1059.159. Chenopis atrata. (Black swan)

1059.160. Struthus camelus. (Ostrich)

Amphibia and Pisces.

1059.161. Bufo giganteus. (Toad)

1059.162. Ceratophrys dorsato. (Horned toad)

1059.163. Aspidonestes aegyptiacus. (Soft-shelled turtle)

1059.164. Trinyx granisus.

1059.165. Boa constrictor.

1059.166. Uromastix Spinipes. (Horned tail lizzard)

1059.167. Podinema teguixin. (Large So. American lizzard)

1059.168. Lophura amboinensis.

1059.169. Crocodilus biporcatus. (Crocodile).

1059.170. Lachesis rhombeata (Serpent of rattlesnake family)

1059.171. Cyprinus carpio. (Carp).

1059.172. Silurus glanis. (Cat-fish).

305

1194.40

See page 1181

1057.35 - Patella -
1687

Presented by Dr. Drijedale

1060. Ligamentous Preparation of foot. 11/8/01
Presented by Dr. James K. Young.

1077.10

~~No. 308.~~ Foetal Heart & Lungs. (old No 200.) Sec 8 Shelf 2.

~~107722~~

~~No 309 Foetal Liver~~ (old No 340) Sec 8 Shelf 2

1066 Heart of child

1066.05 Heart of a calf

1068.65 McClellan's Regional Artery. This specimen was removed from the body of a young man aged 27, who died from phthisis. There is no arch to the aorta, and the position of the heart, when discovered, was vertical within the thorax. There was only one auricle and one ventricle.

1068. Skull; left half showing nerves and veins. Presented by Prof. George McClellan.

1068.05 Hands showing nerves and veins. Presented by Prof. George McClellan.
changed from 1044.75 vol I. p. 262

1068.10 see vol I page 1697
1768 Hand showing arterial, venous + nervous distribution.

1069. Skull, vascular and nervous distribution. Purchased.
Old number 198
Also number 1008.05 vol I p. 229
Do not list again in new Catalogue as it is listed as 1008.05 the number on the specimen

309

#307 Sec 8 Shelf 2

1077 Thoracic viscera of a foetus; injected red.
307

Presented by Dr. Mütter.

1078- Larynx; normal.
1795
109
3

Presented by Dr. Mütter.

~~1078.10 Larynx. Presented by J. Solis Cohen. 1783 Vol. 1 Page 1706~~

1078-05 Larynx; animal unknown.
1796
109
3

1078.10 Larynx Vol. 1 Page 1706
1783
Presented by J. Solis Cohen.

1081- Lungs of an infant, age 8 days. Missing

Presented by Dr. Hinsdale.

1083- A Phantom Brain.

The model is constructed in colosal proportions and is intended to show the course of the fibres in the human brain and their relation to the several nuclei and the spinal cord.

This preparation was purchased for the Mütter Museum in 1884 and was constructed by Buechi, of Bern, Switzerland under the supervision of Prof. Aeby.
R. Buchi

The height is 125 cm; its width 70 cm. The cortex is dotted over with numerous corks 2 cm. long, which are distributed in systematic order. The basal nuclei, of a much larger size, are seen in their appropriate places. The spinal cord, made up of ganglia and columns of wires of different colors, is represented throughout a portion of the cervical region.

These columns of the cord of different colo[illegible]s with distinguish their function, lead to their appro[illegible] ganglia of corresponding color, or to the [illegible] cortex which are marked by similarly col[illegible]e spinal cord.

The anterior and lateral columns of the cord are painted red. They are the motor fibres and can be traced to the anterior and lower portion of the medulla, where they decussate, and through the pons to the internal capsule where, between the candate nucleus and optic thalamus they radiate to the cortex. They are seem to come chiefly from the convolutions about the fissue of Rolands. Wherever red balls are seen from that point a red fibre (motor) descends to the anterior or lateral columns. It will be noticed that the column of Türck or direct pyramidal tract is in relation with the posterior part of the lateral column of the opposite side.

Tracing the fibres of the posterior column (colored blue) we find them represented as wholly decussating in the medulla, forming the posterior third of the internal capsule and passing to the corpora quadri-gemina and optic thalami (which are colored blue).

The exterior portion of the lateral columns (colored green) are seen to lead to the cerebellum, decussating near its superior surface.

The yellow fibres place the basal nuclei in communication with the cortex; the white fibres are purely commissural ~~commisaral.~~

Reddish Brown. Segmental ventral ganglia of the spinal cord, with the accompanying fundamental bundle fibres in the anterior and lateral parts. Origin of the lll, lV, V, Vll, Xl, Xll cranial nerves.

Light Red. Striated and unstriated pyramidal tracts with accompanying gray cortical matter.

Dark Green. Segmental Dorsal Ganglia of the spinal cord. Origin of the V, Vlll, lX, X cranial nerves

Middle Green. Spinal shank (direct lateral column) of the cerebellum, with appertaining gray cortical matter in the vernius superior.

Light Green. Corona radiata of the cerebellum, with gray cortical matter.

Dark Blue. Fundamental bundle of the posterior column (funic, cuneatus, Burdach) with nucleus--Olivary body--Restiform body- Nucleus dentatus(corpus ciliare) and superior peduncle of the cerebellum- Thalamus opticus and Globus pallidus (belong to the nucleus lenti formi in the extended sense of the word.)

Light Blue. Finiculus gracilus of Goll with Lemniscus. Gorpora quadrigemina.

Orange. Middle peduncle (crus cerebelli ad pontem) of the cerebrum and cerebellum with lateral ganglia and gray cortical matter and cleus lentiformis in the narrower sense of the word (outer part of the nucleus lentiformis in the extended sense of the word) to the pallidus.

White. Corpus callosum and commisura ant.

It is to be borne in mind that, in determining the course of the cerebral fibres, e.g. the corona radiata, anatomy reveals nothing and that physiological experiment is the only means at our command.

As regards the exact localization of the sensory and motor tracts of the spinal cord there is still difference of opinion. The antero-lateral columns are usually regarded as the chief motor paths, but the recent and careful experiments of Ludwig and Woroschil[illegible]e[illegible]f

(1874(place the motor paths in the lateral columns only. The anterior columns (colored brown in the model) are regarded more as commissural connections between the motor nerves and adjacent segments and not, at least, the direct paths of motor impulses proceeding from the brain.

Purchased by Dr. S. Weir Mitchell for the Mütter Museum.

SECTIONS OF THE BRAIN.

In store room - Case # 3 - Shelf 1

The following series of thirty-five sections of the normal human barin were made for the Museum by Dr. Henry D. Schmidt of New Orleans.

They illustrate the anatomy of the brain as seen in horizontal and vertical cross sections and by means of a carbolized glycerine jelly they are preserved in large glass cells.

The sections have a thickness of 5 to 1 cm. The surrounding ring is made of rubber which is firmly cemented to the glass plate below and to the cover--glass.

These specimens admirably illustrate the descriptions given by Dr. John C. Dalton inhis work on "Sections of the Human Brain", the publication of which makes it unnecessary to give any detailed statement of the specimens in this museum.

1083.01- to 1083.06- Horizontal sections taken at six attitudes, showing both hemispheres.

1083.07 to 1083.11 Antero.posterior vertical sections in five planes.

1083.12 to 1083.35- Twenty-four lateral vertical sections of the cerebrum including sections of the cerebellum, medulla and spine.

1083.36-✓ Section of the cerebrum.

This section is 10cm. in length, but is of extreme thinness, suitable for microscopical study; it is stained with carmine. Med by Dr. Schmidt.

1083.37-✓ Section of the cerebellum.

This preparation is similar to the preceding and is 7cm. in length.

✓1084.✗ Dissection exposing the Cauda Equina.

#274 Sec 8 Shelf 1
1089 Uterus and appendages. Presented. by Dr A B Hirsch

1089.01 Generative Organs showing position of Ureters in relation to Cervix
275 Presented by Dr. A.B. Hirsh.
Sec 8
Shelf 1

1089.10 External organs of generation of a negress.
#276
Sec 8
Shelf 1

Presented by Dr.Corse.

1089.20 External organ of generation of a female.
277
Sec 8
Shelf 1

Presented by Dr.Corse.

1089.35 Generative organs of an infant of eight days.
278
Sec 8
Shelf 1

Presented by Dr. G. Hinsdale.

1089.50 Uterus of pregnancy about the fourth month.
279
Sec 8
Shelf 1

Missing

1089.65 Uterus and appendages with foetus in situ at term.

1089.70 Uterus, containing placenta in situ, and foetus.

5852
1194.40

325

685 a

1194.40

-b

3)

327

685 a
1194.40

EMBRYOLOGY.

Models showing the Development of the Chicken

and

Microscopic Transparencies.

329

585 a
1194.40

EMBRYOLOGY.

Models showing the Development of the Chicken

and

Microscopic Transparencies.

~~# 242 (Two slides) Human foetus prepared by method of O. Schultze by F M Paul~~
~~Sec 6 Donor F. M. Paul.~~
~~Shelf 2.~~

~~# 243. Foetus 2½ month.~~
~~Sec 8 Presented by Dr A. B. Hirsch~~
~~Shelf 2. (Two slides)~~

~~# 244~~
~~Sec 8 Uterus & Embryo - Embryo 1.5 CM Long~~
~~Shelf 2. (old No 1040)~~

~~# 296 Embryo -~~
~~Sec 8 old No 1040~~
~~Shelf 2.~~

HUMAN EMBRYOLOGY (Models).

~~1090-~~ Series

~~# 236~~
~~Sec 5~~
~~Shelf 3~~

Human Embryology foetuses.-

Embryology of the chicken.

Paper vesicle

✓1090.001✓ A case showing upon a magnified scale the female genital organs and ovulation from rupture of the graafian vesicle through twenty-one subsequent stages until about the second month of gestation. - Case 77

#298 Sec 201 Shelf 2

✓1090.002✓ Uterus and appendages at one month of gestation. #299 Sec 202 Shelf 2

✓1090.003✓ " " " " the second month. #300 Sec 202 Shelf 2

✓1090.004✓ " " " " " third month. #301 Sec 202 Shelf 2

✓1090.005✓ " " " " " fourth month. 302 Sec 202 Shelf 2

✓1090.006✓ " " " " " eighth month. - #303 Sec 201 Shelf 3

✓1090.007✓ " " " " " ninth month. #304 Sec 201 Shelf 3

✓1090.~~009~~ 008✓ Extra-uterine foetation. No 305 Sec 202 Shelf 3

✓1090.~~010~~ 009✓ Extra-uterine foetation. No 306 Sec 202 Shelf 3

298 to 306 are papier mache preparations

Chick to 1090.042

Transparencies (Microscopic), of the Earliest Development of the Chick.

These 8 plates 1090.011 to 1090.018 missing

The development of the chick in its egg, during the first five or six days is represented in the transparencies as the most interesting period in which appear the fundamental forms of the growing body, and the embryo's surroundings are adapted for its construction. For here, together with the exactness of the forms, their unusual tenderness, likewise the indistinct outlines of microscopic pictures are as demonstrable as in the pure plastic treatment which seems fitting in later periods, where the body has more consistency and the organs are more thoroughly formed. All the preparations of the development of a chick are made after nature. In this the excellent productions of Erdle, much earlier pursuing this line of research, gave a definite direction. Through Erdl's early death were, unfortunately many embryological researches, undertaken in a scientific and artistic spirit, interrupted, and not till some year after were circumstances favorable for again taking up and advancing these efforts.

1090.011- Plate 1.

The pressing of the Nutrient Juice to the Centram causes a wave-like disposition. Through this the germinal disk makes a second fold and there is formed by the primitive trace or nerve tube a second zone.

1090.012- Plate 11.

Microscopically developed Germinal Area of an egg incubated twenty-four hours. The embryo floats in the

translucent Area Germination. On its upper end appear three vesicles;the uppermost the brain,the two lateral eye vesicles. The Cephalic part is enclosed in a veil-like cap;the growing Amnion,of middle origin. The medullary tube ends above in a little knot,the medulla oblongata. The waving lines at both sides of the neck form depressions for the growing face-flaps. Beneath on both sides are seen the somites. The body ends in a long trunk.

1090.013-✓ Plate 111.

The eyes are separated from the brain vesicle. A definite line surrounds the head,the upper border of which forms the future upper jaw. On the medulla oblongata is placed a crescentic medullary line,the first branching of the white brain substance. The embryo is turned on the right side upon which appears a vesicle, the heart or rather the heart-tube;and beneath it showing its self as a branch,the right vitelline vein. The granular layer of the Area Vasculosa is divided into translucent furrow-like,and opaque portions. This is the separation of the membranous from the liquid parts preparatory to the differentiation of the vessel walls from the blood.

1090.014-✓ Plate 1V.

In the upper border-line of the embryo,giving it a wavy appearance are shallow depressions for the formation of the already developing upper jaw,and particularly of the nose and the upper alveolar border. The ophthalmic vesicle is developed in its membrane as Bulbus Oculi,surrounding the transparent nucle[illegible] he heart is a

a tube as in the former plate. On the upper end of the left somite one sees the auditory vesicle originating as a semicircular pit. The somites are invested in a delicate layer for the formation of the long parts. A circular furrow surrounds the vascular area, the preparative blood reservois of the bena Terminalis. The solid and liquid parts of the vascular area begin to be separated from each other. One sees already between the elevated lines red blood corpuscles.

1090.015- Plate V.

The upper half of the embryo's body is flexed. It existed heretofore in a horizontal disposition. During the flexing the lateral boundaries are bent toward each other and so form the sides of the face and head. The head is seen only in profile. The extreme upper end of this embryo bends downward in order, through a later even more positive incurvation, to secure the union of the upper half of the face with the deep lying parts. The magnetic attraction which draws the nutrient sap from plant leaves appears in the fine vessels which extend to the whole body. Like this is the formation of the flow of nutrient material in the vascular area. On the under helf of the Area Germinativa these little vessels are seen still in process of development. But the vessels are separated from the liquid parts definitely. On both sides of the vascular area are the two vitelline arteries forming a decided path for themselves. The heart tube, already filled with red blood, has a sigmoid twist, due in part to the bending of the upper part of the body and having for its object the formation of the heart; this to take place later.

1090.016- Plate Vl.

The embryo is still more flexed to prevent(?) the union of the face flaps. The vessels are more definite. The sinus venosus receives the blood,which,flowing from the embryos body is distributed in the vascular area,and discharges it through a mid vein extending downward into the upper lateral portion of the heart. Below,this union is not yet completed.

Plate VII

1090.017 The face-flaps,pressed closely together through the very decided flexion of the embryo are seen united. Both the large vitelline arteries ramify regularly in a tree-like manner in the vascular area,emptying into the vena terminalis,and above and below into a vein again returning to the embryo's heart.

1090.018- Plate Vlll.

The first regular circulation is represented. The blood-flow in the vessels running to and from the heart is observed in this preparation after nature as though it were before the eye. In the vascular area,all vessels empty no longer into the vena terminalis,but there are formed repeated branchings which receive the returning blood. The eye is colored. The aorta,now divided into two branches,descends along the provertebral column. The ridges,already perceptible in the former plate on the lateral margins of the body,are the first traces of the extremities.

The circulation is no longer made up of only the vessels of the area vascular,but also of the aorta passing to the lower end of the embryo and also into the Allantois,which has been formed in the meantime.

Since several venous stems are formed in the circulation this widely encircling vena terminalis is no longer required in such extension. It increases in circumference till it reaches half the yolk. After this, since it is constantly pressed forward, as the elongating vascular branches stretch out embracing the yolk, it must draw its circle smaller and smaller until it ends in a knot on the opposite yolk side. But the yolk is being constantly more absorbed by the growth of the embryo and when the vena terminalis has come to its opposite side, there is only a shallow yolk sack. This disappears, at the hatching period, into the abdominal cavity of the chick. The occluded vena terminalis, yet visible in the natural chick, is the closing point of the whole and forms the chicks navel. A most interesting metamorphosis especially if we compare this vessel inits widest expansion to its final adaptation.

685 a
1194.40

DEVELOPMENT OF THE CHICK.

1090.019- Start

No.1.

A non incubated impregnated chicken's egg.

On the sharp end of the egg the albumen leaves an empty space which is filled with air. The albumen is not a uniform mass, but is made up of three layers. The outer layer is thin, the next thicker, and the third, lying next to the yolk, is very viscid. This is easily demonstrated on a broken egg. The yolk being the most important part of the egg, is supported by two twisted chalazae affixed at both poles to the inner albumen layer. By this means it is kept in the mid albumen space and the early life of the incubated egg is protected from the shocks and jars which would otherwise act on it.

1090.020- No.2.

Egg six ~~months~~ hours after incubation.

Through the brooding warmth, the fructified spot is somewhat extended in the midst of the yolk and forms the germinal vesicle.

1090.021- No.3.

Egg incubated twelve hours.

The white germinal spot, which was clearly seen in the former egg, sinks somewhat, and over it there is a transparent humor.

1090.022- No.4.

Egg incubated eighteen hours.

The germinal spot has sunk still more. On the transparent surface appears a very light streak into which the deep lying germinal spot is also transformed, hence the latter seems not so large and definite since it

is absorbed in this abstraction process. This light streak is called the Primitive Trace. The transparent surrounding liquid is called Area Germinativa since here the foundation forms of the germ, or growing living being, appear.

1090.023-

No.5.

Egg twenty-four hours after incubation.

The Area Germinativa is oval; for the Primitive Trace becoming elongated and this being the living central mass of the Area Germinativa, the latter must conform to this change in shape. The compact yellow surrounding of the clear middle space is called the Area Vasculosa, because here, later, appear the nutrient blood vessels. And the third envelop of the Primitive Trace, appearing in the form of white circling medullary loops is called the Vitelline Area, here the most delicate nutrient material is metamorphosed for the formation of the growing creature.

1090.024-

No.6.

Egg incubated thirty-six hours.

The Primitive streak has a definite form. Above appears a rounded end of the embryo. In the primitive streak there is a groove only to be seen by the microscope. This groove represents the earliest formation of the spinal cord. The brain, with the spinal cord as the foundation of the nervous system, appear as the first positive disposition for the formation of a living being. Here begins the first life. Everything must be subordinate to the beginning nerve-life, and act in accordance with the orderings of this system. The Area Vas-

culosa is white spotted. This represents the separation of the membranes from the liquid parts for the extended formation of blood vessels. Since later, the nutrient juice is turned to blood, the vessels must in a measure be already prepared.

No.7. 42

1090.025- Egg incubated thirty-six hours.

The transformation of white nutrient substance into blood has taken place. A round blood-streak surrounds the face area in which the blood appears as red points surrounded by membrane. The growing Embryo is more definitely formed. The cephalic part is bent. There appears in the middle of the body line a red point, the heart, which is united to the blood vessels.

1090.026- No.8.

Egg incubated two days.

In the Area Vasculosa the principal blood channels of the circulation are disposed on each side in accordance to their union with the embryo heart.

1090.027- No.9.

Egg incubated two and one-half days.

The formation of vessels is further advanced. Downwards along the vertebral column extends the large Aorta. A dark point, the eye, is seen in the head of the embryo which now lies on its side.

1090.028- No.10.

Egg incubated three days.

The red points or blood areas in the Area Vasculosa are now, except a small part, changed into r[illegible]r vessels.

The embryobody has decidedly increased in size.

1090.029- No.11.

Egg incubated three and one-half days.

The embryo is very much flexed. This is necessary for the formation of the facial parts. The Cephalic portion is made up of transparent vesicles from which the brain develops. The first regular circulation is completely represented. On both sides of the embryo, the blood streams out from the heart in two principal currents. These branch even to the finest points in the Area Vasculosa, and empty into the Vena Terminalis. Above and below are seen in the Area Vasculosa two vascular stems which take the blood back again into the heart. They are in direct communication with the heart as are the vessels for the outflow of blood. In the middle of the eye is a white point, the Crystalline Lens.

1090.030- No.12.

Egg incubated four days.

The white points on either side of the spinal cord are somites. These are found much earlier but are then microscopic. On the embryobody are seen slight ridges representing the first appearance of feet and wings.

1090.031- No.13.

Egg incubated five days.

As in the earliest period of development, the embryo is covered with a fine membrane, the Amnion filled with Liquor Amnii. In the earlier embryo, it cannot be properly recognized by the naked eye. Now, of considerable extent and distended with ~~ammotic~~ amniotic fluid, it is raised above the embryo. In the face portion plainly appear

projecting flaps from which are further developed forehead,nose,beak,and throat. The wings and legs are more developed.

1090.032- No.14.

Egg of six days.

From the brooding the yolk grows larger. It consumes the albumen and has now reached its greatest size. From this time it becomes smaller,because it is gradually absorbed by the embryo which needs more nourishment. The Amnion is slit open to expose the embryo. Beneath there appears a second vesicle in which a second blood circulation is formed. The design of this vesicle is that it may,in the development ofthechick,bring fresh air to its blood,thus purifying it. This vesicle grows very quickly and surrounding the yolk extends itself on the shell membrane. But both the shell and its membrane are porous,that is,filled with fine openings allowing the entrance of fresh air,and here,there takes place between this membrane which is very rich in vessels and the shell membrane,the communication and interchange between the atmospheric air and the embryo-blood. In suckling animals and man,the embryo-blood receives the necessary air through its communication with the body of the mother who in turn breathes in fresh air through the lungs,and at the same time nourishes the embryo by her blood.

1090.033- No.15.

Egg of seven days.

Since the yolk increases in size,it accommodates itself to the shape of the shell. The vesicle described in the former egg has grown quickly and contains vessels.

As it is filled with a urine-like liquid, it is called Harnblase, or Allantois. It is seen that this vesicle forms the first organ for the carrying away and disposal of excreta. The arteries of the yolk are accompanied in this egg by yellow vessels. In the inner part of the yolk root-like fibres or villi are formed which absorbing the nutrient substance, empty in twig-like branchings into large vessels which in turn lead this nutrient substance into the body of the embryo, these little alimentary tubes being in connection with the blood vessels. This is the same plan as is found in plants where the root filaments absorb from the earth its nutrient substance that they may deliver it to the stem of the plants.

1090.034- No.16.

Egg incubated eight days.

The formation of the face flaps being further advanced, the parts of the face are clearly recognizable. The upper portion of the beak is pointed anteriorly; on both its sides appear two still enclosed surroundings the future nostrils. The opposed under-jaw flaps are not yet united in the middle line but are endeavoring to secure this union and thus form the under part of the beak. The head and especially the eye are at this time very large. The wings and feet project through the formation of the joints. The Allantois membrane, mentioned before has become very large. The yolk sack is slit open and the yolk withdrawn, thus allowing the rootlets or villous tufts which suck up the yolk juice to be clearly seen. This absorption is for the nourishment of the embryo.

355

1090.035 No.17.

Egg of nine days.

The yolk begins to be absorbed by the embryo. It has clearly diminished in size. The embryo body is closed. The viscera appear as heart, lungs, liver through the fine body covering. On the wings and feet are seen divisions for the toes and the wing joints.

1090.036 No.18.

Egg incubated ten days.

On opening the shell you will rarely succeed in getting out uninjured the yolk together with the Allantois, at this time so intimately connected with the shell membrane. The Allantois is here extended over the Amnion, the embryo and half the yolk. The germinal area described in the first egg is now simply the space near the embryo made vacant by consumption of the nutrient substance. Later it forms a groove in which the embryo is placed, as here, when it becomes larger. The head and the face portions together with the whole body are in the main formed, but the individual parts are as yet not symmetrically disposed in regard to each other.

1090.037 No.19.

Egg of eleven days.

On the very large eye-ball and white membranous margin can be seen, the under and upper eye-lids, which begin to be formed and enclose the eye. The ribs are seen shining through. The extremities are beautifully developed. On the back of the embryo appears a black streak, the first manifestation of feathers. The growth of the embryo absorbs more and more the constituent

parts of the yolk,its contents are,therefore,watery and the yolk becomes through this of glass-like transparency. The empty space,formerly the Area Germinativa,is soon extended over the whole yolk. The Vena Terminalis, which earlier formed the outermost boundary of the extended vascular area must contract and grow smaller,because the yolk blood-vessels,from their constant extension and elongation,must come together in a narrow circle on the yolk-side opposite their point of origin,and hence this vein,as the object of their terminal openings, must likewise narrow its circle and gradually become occluded. It requires great practice to get out the yolk uninjured in the later periods of development. From the above proceeding is naturally the Vena Terminalis,later no longer visible from which the opinion obtained that this vein disappears. It does not disappear,but is slowly occluded on the opposite yolk-side and ends in a knob which at birth,when the rest of the yolk sack presses into the chicks abdominal cavity forms its navel. The observation that this Vena Terminalis,at one time so widely extending,becaomes the navel of the bird,certainly presents a most interesting metamorphosis. In this egg is seen the gradual diminution of the Vena Terminalis.

1090.038-

No.20.

Egg of thirteen days.

The whole body of the Embryo is covered with feather papillae like a goose skin with the shoots of the sprouting feathers. Parts of the wings,back,and feet are already covered with feathers. The Allantois

membrane is cut open and spread aside, showing the embryo which as seen through the overlying amnion assumed a very much cramped position. On the top of the embryo beak grows a sharp little point. Later, when the chick becomes so large that it fills up the whole shell space, its movements cause this sharp point to tear or split the egg membrane and, as the shell space is too small for the ripe chick, to burst the shell itself.

1090.039- No.21.

Egg of fifteen days.

The eye-lids cover the eyeball as a fine membrane. The chick has more feathers. The Vena Terminalis, described in No.19, forms a still narrower ring in which are collected not only the terminations of the blood vessels, but also of the villi.

1090.040- No.22. Egg incubated seventeen days.

The chick is complete covered with feathers. The body assumes more pleasing proportions. On the toes the nails or claws show themselves. On the forehead appears the cockscomb. The eye-lids are almost closed and have crumpled margins. The lens is deeper placed, hence the pupil appears as a black point.

1090.041- No.23.

Egg of nineteen days.

The chick is completely developed and surrounded by the remainder of the yolk. The large blood-stems which extend around it are Allantois vessels, the find ramifications of which, are lost. This membrane lies so closely upon the whole that it is no longer recognizable

as such. The end of the yolk, surrounded by the quite small circle of the Vena Terminalis, forms a knob, soon to appear as navel.

1090.042- No.24.

The ripe chick of twenty-one days.

The chick is ripe. The sharp point on the top of the beak and the chick's movements have broken the shell. The eye is still closed. The yolk is nearly entirely absorbed and presses into the abdominal cavity during the first life period. The little knob, or closing point of the Vena Terminalis becomes presently the navel. The whole egg is completely metamorphosed. The chick leaves only an empty shell.

EMBRYOLOGY OF THE CHICKEN IN FOUR STAGES.

1090.043- The specimen consists of an enormous egg opening transversely and disclosing on a large scale the structures as they appear in four stages of incubation, a segment equal to one-fourth of the volume of the egg being given to each stage.

1090.

1090.049 — Membranes of a foetus. Third Month

Presented by Dr. Mütter.

1090.052 — Membranes of a foetus.

Excellent example of the shaggy chorion.

Presented by Dr. Corse.

1090.053 — Membranes of a foetus.

Presented by Dr. Corse.

1090.051 — Embryo. Third Month

Presented by Dr. Corse.

1090.05- — Embryo.

Presented by Dr. Corse.

1090.06- — Blighted ovum.

Presented by Dr. Moore.

1090.07- — Embryo. Third month

Presented by Dr. J.M. Corse.

1090.08- — Embryo and chorion. Six month

Length 1 cm. The embryo is attached by the omphalomesaic vessels to the chorion.

Presented by Dr. J.M. Corse.

1090.08-5-4 Embryo.

290 Sec 8 Shelf 2

Length, 12 mm.

Presented by Dr. J.M. Corse.

1090.09-4 Embryo and membranes.

291 Sec 8 Shelf 2

The embryo is 1.5 cm. long. The optic vesicle is distinct; the umbilical cord suspends the embryo in unbroken membranes, transparent and of the most delicate texture.

Presented: Dr. Corse.

1090.10-4 Embryo.

310 Sec 9 Shelf 1

Length 2 cm. The hands and even fingers and toes are distinct.

Presented by Dr. J.M. Corse.

1090.11-4 Embryo and membranes.

311 Sec 9 Shelf 1

length, 2.2 cm.

Presented by Dr. W.L. Atlee.

1090.12-4 Embryo. 2nd mo.

312 Sec 9 Shelf 1

Length 3 cm.

Presented by Dr. J.M. Corse.

(This specimen [illegible] as to be valueless [illegible] 5-10-01)

~~1090.121 Embryo; 6 weeks. Presented by Dr. Hirsh.~~

1090.123 Embryo - presented by Dr H.F. Hansell — NO-295 Sec 8 Shelf 2 Missing

1090.12-5 Embryo of six weeks.

carefully fixed

In Jan. 1885 Dr. Hansell eneucleated the eye of a boy aged 3 years. In September 1885, brought this specimen to the doctor. The left eye was staphylomatous and had developed much more rapidly than the right.

Presented by Dr. H.F. Hansell.

1090.12a Embryo of six weeks.

Presented by Dr. A. E. Hirsch.

1090.13 Embryo and membranes.

Length 3 cm.

Presented by Dr. J.M.Corse.

1090.14 Embryo and membranes.

The membranes are opaque and conceal the embryo.

Presented by Dr. J.M.Corse.

1090.15 Embryo and membranes.

Length 5 cm. The chorion is dense and shaggy.

Presented by Dr.J.M.Corse.

1090.16 Embryo.

Presented by Dr.Corse.

1090.17 Embryo.

Presented by Dr. Corse.

1090.18 Embryo.

Length 7 cm.

Presented by Dr.Corse.

1090.19 Embryo. Abortion;commencing amputation of the left thigh and probable death from compression of the cord. There is one turn of the umbilical cord around the left thigh 2 cm. above the knee so tightly constricting the limb as to have produced a deep groove in the soft tissues and to have cut off the circulation to the lower half

1090.126- Embryo of six weeks. Garnish find - Missing

Presented by Dr. A. B. Hirsch.

1090.13- Embryo and membranes. Third month.
313
Sec 9
Shelf 1
Length 3 cm.

Presented by Dr. J.M.Corse.

1090.14- Embryo and membranes. 4th month.
314
Sec 9
Shelf 1
The membranes are opaque and conceal the embryo.

Presented by Dr. J.M.Corse.

1090.15- Embryo and membranes. 3rd month
315
Sec 9
Shelf 1
Length 5 cm. The chorion is dense and shaggy.

Presented by Dr.J.M.Corse.

1090.16- Embryo. Third month
316
Sec 9
Shelf 1

Presented by Dr.Corse.

1090.17- Embryo. Third month
317
Sec 9
Shelf 1

Presented by Dr. Corse.

1090.18- Embryo. 2nd Month
318
Sec 9
Shelf 1
Length 7 cm.

Presented by Dr.Corse.

1090.19- Embryo. Abortion; commencing amputation of the left
319
Sec 9
Shelf 1
thigh and probable death from compression of the cord. There is one turn of the umbilical cord around the left thigh 2 cm. above the knee so tightly encircling the limb as to have produced a deep groove in the soft tissues and to have cut off the circulation of the limb below

the part where this funis ligature is fixed,

From Mrs. S., supposed to be nearly four months advanced in pregnancy. Could assign no cause for the threatened abortion. Uterine pains and hemorrhage preceded expulsion; the amnion came away entire. It was estimated that the foetus had been dead two weeks before abortion.

Trans. Coll. Phys. Phila. Vol. IV. p 211. 1866

Presented by Dr. A. Nebinger.

1090.20-4 Foetus. Third month
320
Sec 9
Shelf 1

This specimen when turned toward the light shows well the centres of ossification in the radius and ulua, metacarpals and phalanges; the latter appear as mere dots.

Presented by Dr. J.M. Corse.

1090.21-4 Foetus. Third month
321
Sec 9
Shelf 1

Presented by Dr. J.M. Corse.

1090.22-4 Foetus. Third Month
322
Sec 9
Shelf 1

Length 9 cm.

Presented by Dr. J.M. Corse.

1090.23-4 Foetus. 4th Month
323
Sec 9
Shelf 1

Presented by Dr. J.M. Corse.

1090.24-4 Foetus. 4th month
324
Sec 10
Shelf 1

Presented by Dr. J.M. Corse.

1090.25- Foetus. Exd. mend.

Presented by Dr.J.M.Corse.

1090.26- Foetus,membranes,and placenta. Exd. mend.

Presented by Dr.W.L.Atlee.

1090.29- Foetus and placenta. Exd. mend.

Presented by Dr.J.M.Corse.

1092.2- Foetus and placenta. Exd. mend.

Length 11 cm.

Presented by Dr.J.M.Corse.

1090.22- Foetus and placenta. Exd. mend.

Presented by Dr.J.M.Corse.

1090.30- Foetus and placenta. Exd. mend.

Presented by Dr.J.M.Corse.

1090.31- Foetus and placenta. Exd. mend.

Presented by Dr. J.M.Corse.

1090.32- Foetus. Exd. mend.

Presented by Dr.J.M.Corse.

Foetus and placenta. Exd. mend.

Presented by Dr.J.M.Corse.

1090.25- Foetus. Fifth month
325
Src 10
Shelf 1

Presented by Dr.J.M.Corse.

1090.26- Foetus,membranes,and placenta. Fifth month
326
Src 10
Shelf 1

Presented by Dr.W.L.Atlee.

1090.27- Foetus and placenta. 4th month
327
Src 10
Shelf 1

Presented by Dr.J.M.Corse.

1090.28- Foetus and placenta. 5th month
328 Length 11 cm.
Src 10
Shelf 1

Presented by Dr.J.M.Corse.

1090.29- Foetus and placenta. 5th month.
329
Src 10
Shelf 1

Presented by Dr.J.M.Corse.

1090.30- Foetus and placenta. 5th month
330
Src 10
Shelf 1

Presented by Dr.J.M.Corse.

1090.31- Foetus and placenta. 5th month
331
Src 10
Shelf 1

Presented by Dr. J.M.Corse.

1090.32- Foetus. 5th month.
332
Src 10
Shelf 1

Presented by Dr.J.M.Corse.

1090.33- Foetus and placenta. 5th month
333
Src 10
Shelf 1

Presented by Dr.J.M.Corse.

1090.34- Foetus and placenta. 5th month
334
Sec 10
Shelf 1
Length 15 cm.

Presented by Dr.J.M.Corse.

1090.35- Foetus and placenta. 5th month
335
Sec 10
Shelf 1

Presented by Dr.J.M.Corse.

1090.36- Foetus and placenta. Destroyed June 1-1939
336
Sec 10
Shelf 1
Destroyed

Presented by Dr.J.M.Corse.

1090.365- 337 " membranes
Sec 10 " 6th month. " " " " T.M. Drysdale.
Shelf 1

1090.37- Foetus. 5th month
338
Sec 10
Shelf 1
Length 21 cm.

Presented by Dr.J.M.Corse.

1090.375 342 Foetus 5th month
Sec 10
Shelf 1

Presented by Dr.J.M.Corse.
" " " " " "

1090.38- Foetus. 6th month
339
Sec 10
Shelf 1

Presented by Dr.J.M.Corse.

1090.39- Foetus, membranes and placenta. Missing
340
Sec 10
Shelf 1

Presented by Dr.J.M.Corse.

1090.40- Foetus. 5th month
341
Sec 10
Shelf 1
Length 26 cm.

Presented by Dr.J.M.Corse.

1090.405- Foetus 6th month (Hydrocephalic ?) " " " Drysdale.
343
Sec 9
Shelf 1

1090.41- Foetus and placenta. 6th month
344
Sec 9
Shelf 1
for J. M. Corse

1090.42- Foetus of six months in its membranes; with placenta attached.
345
Sec 9
Shelf 1

Presented by Dr.J.Ewing Mears.

5852a
1194.40

1090.0451 Skeleton see page 360

~~46~~ 1090. Foetus in utero
Dr Drysdale.

297
Sec 9
Shelf 1

Vol II - Pg. 517

1090.451 - Hydrocephalus. (infant)
#37 Presented by Dr H. A. Kelly.

1090.55 - Dried skeleton of a child. Approx at term or shortly after.

1090.56 - Foetus with cord and Placenta - Dried preparation. A six month foetus.

1090.57 - Dried skeleton of a child

1090.43 - Foetus. 6th month.
347
Sec 9
Shelf 1

Presented by Dr. Longaker.

1090.44 - Foetus; very large. 9th month.
348 Dr Jos. Price
Sec 9
Shelf 1

1090.45 - Foetus in utero. 8th month.
349

1090.46 Foetus. 6th month. Presented by Dr. Jos. Price.
350

1090.50 - Twin foetus. 2nd month.
351 Length of each foetus, 2.5 cm.
Sec 9
Shelf 1

Presented by Dr. J. P. C. Griffith.

1090.60 - Colytedonous placenta.
352
Sec 9
Shelf 1

Presented by Dr. W. L. Atlee.

1090.7501 to 1090.7524 see pages 245-247-249-251 incl. vol I.

1090.59 - Human foetus. History unknown. Formerly the property of Wm D Oelermann whose heirs were asked to give the specimen to the museum. The foetus is approx. 3 mo
Presented by Dr. J E Cottrell Sept. 9 1935

~~1694. Uterus and appendages with foetus in situ at term.~~

~~1694.05 Uterus, containing placenta in situ~~, and foetus.

1091. Foetal liver.

1093 Kidney.

685 a
1194.40

385

6852

1194.40

-b

3)

1098.03 Foetal skull at term.
353 The anterior portion of the jaws has been removed, showing the alveoli and the temporary teeth yet undescended.

1098.04 Jaw bones of a child about 7 months old. The central incisor teeth have erupted.
357

1098.05 Jaw bones of a child about ten months old. The eight incisor teeth have erupted.
358

1098.06 Jaw bones of a child about one and one-half years old. Eruption of sixteen teeth. The permanent teeth are visible, deeply imbedded in the upper jaw.
359

1098.07 Jaw bones of a child about two years old. Eruption of sixteen teeth.
360

1098.08 Jaw bones of a child about three years old. Eruption of the twenty temporary teeth.
361

1098.00: Two teeth extracted in clinic.
Presented by Dr. Mears.

1098.01 Foetal skull of six months.
354
Sec 10
Shelf 2
The anterior and posterior walls of the aveoli are well marked; The septa marking the sockets are faintly seen.

1098.02 Foetal skull of about eight months.
355
The sockets are better marked. The upper incisor teeth are undescended but visible above the alveolar border.

1098.03- Foetal skull at term.
356 The anterior portion of the jaws has been removed, showing the alveoli and the temporary teeth yet undescended.

1098.04- Jaw bones of a child about 7 months old. The central incisor teeth have erupted.
357

1098.05- Jaw bones of a child about ten months old. The eight incisor teeth have erupted.
358

1098.06- Jaw bones of a child about one and one-half years old. Eruption of sixteen teeth. The permanent teeth are visible, deeply inbedded in the upper jaw.
359

1098.07- Jaw bones of a child about two years old. Eruption of sixteen teeth.
360

1098.08- Jaw bones of a child about three years old. Eruption of the twenty temporary teeth.
361

1098.09- Jaw bones of a child about seven years old. The lower middle incisor and first molar permanent teeth of the upper and lower jaw have assumed their proper position. The remaining permanent teeth are beautifully shown by the removal of the outer table of bone. In all the specimens the bone about the mental foramen is untouched.
362

1098.10- Jaw bones of a child about eight years old. The central and lateral lower incisors and first molar teeth of the lower jaw and the central incisor teeth and first molar teeth of the upper jaw are <u>in situ</u>.
363

1098.11- Jaw bones of a child about eight years old.
364

1098.12- Jaw bones of a child about eleven years old.
365 Both canine of the upper jaw have erupted. A marked irregularity in the line of the aveolar border is noticeable in the neighborhood of teeth about the time of their eruption.

1098.13- Jaw bones of a child about twelve years old.
366 The canine and first molar teeth have only partially descended.

1098.14- Jaw bones.
367 All the permanent, excepting the wisdom teeth, have assumed their position.

1098.15- Right half of the skull; showing all the permanent
368 teeth and their vascular supply.
The fangs of the teeth have been sawn so as to show the pulp cavity and vascular supply.

1098.16- Left half of the skull; showing the nervous distri-
369 bution for the teeth.
The carotid and jagular vessels are well seen; the branches of the fifth nerve and the filaments terminating in the fang of each tooth are also seen.

1098.17- Lower jaw of childhood; showing the obliquity of the
370 ramus.

1098.18- Lower jaw of youth; showing the approx imation to a
371 right angle in the relation of the ramus to the body of the bone.

Siamese Twins. p. 391 A
Eng and Chang Bunker, Died at Mount Airy, North Carolina, January 17th 1874. The twins were 63 years old at the time of their death,
An autopsy on these twins was made by the Commission appointed by The College of Physicians of Philadelphia, February, 1874.

See Transactions of The College of Physicians, Third Serie, Vol. I,

1098.19- Lower jaw of old age;showing the obliquity of the ramus. 372

1098.20- Bones of the face;old age. 373

The outer table of the left half of the inferior maxilla has been removed. The aveolar border has disappeared so that the left mental foramen is within 2 mm. of the upper border ofnthe bone.

1098.21- The temporary and permanent teeth of the upper jaw. 374

These teeth are displayed,side by side, in the superior maxillary bone.

1098.22- Temporary teeth previous to eruption. 375

1098.23- Temporary teeth. 376

1098.24- Permanent teeth. 377

685 a
1194.40

Labyrinth of the Ear.

of.

Man and mammals.

No. 1100.

Homo.

1100. Embryo of five months.

1100.001. Embryo of six months.

1100.002. Embryo of seven months.

1100.003. Embryo of eight months.

110.004. Embryo at maturity.

1100.005. Infant at the age of two years.

1100.006 Youth of twenty years.

1100.007. Man of ninety years.

1100.008. Hottentot youth.

1100.009. Deaf mute girl.

1100.010. Labyrinth of man in situ.

Quadrumana and chiroptera.

1100.011. Simia satyrus. (Orang).

1100.012. Hylobates syndactylus Long armed ape (Gibbon).

1100.013. Cynocephalus sphinx Dog-headed baboon (Papion).

1100.014. Mycetes Seniculus. (Red Howler of Guiana)

1100.015. Ateles paniscus. animal related to the raccoon (Coaita of Brazil)

1100.016. Callithrix personata. (Masked monkey).

1100.017. Macacus cynomolgus Old world monkey (Macaque).

1100.018. Lemur mongoz. Ascembled opossum (Lemur).

1100.019. Galeopithecus volans Bat-like creature from Philippines (Galeopithecus)

1100.020. Pteropus edwardsii Flying fox or fruit bat (Edwards roussette).

Insectivora and Carnivora.

1100.021 Gymnura rafflessii. Insectivorous mammal from Borneo (Bulan).

1100.022. Eupheres goudoti Cat-like animal from Madagascar (Falanaka).

1100.023. Erinaceus europaeus. (Hedge-hog).

1100.024. Ursus spelaeus (Cave bear extinct)

1100.025. Hyaena spelaea (Cave hyaena: extinct)

1100.026 Felis tigris (Bengal tiger)

1100.027. Cynailurus jubatus (Hunting Leopard).

1100.028. Felis yaguarondi Wild cat (Yaguarondi).

1100.029. Canis lupus (Wolf).

1100.030. Vulpes lagopus. (Arctis fox).

Carnivora and Pinnipedia:

1100.031. Otaria jubata. (Eared seal)

1100.032. Proteles lalandii So. Africa Aard wolf).

1100.033. Lutra brasiliensis (Brazilian Otter).

1100.034. Meles taxus. (Badger).

1100.035. Viverra zibetha (Civet).

1100.036. Rhyzaena capensis. Civet or Genet family

1100.037. Helictis orientalis. Weasel-like animal from China and India

1100.038. Trichecus rosemarus. (Walrus).

1100.039. Calocephalus vitulinus (Harbor Seal).

1100.040. Stemmatopus cristatus (Harbor Seal).

1100.041. Latax stelleri (Northern Sea-lion).

Rodentia:

1100.042. Hydrochoerus capybara South American Water-pig (Capybara).

1100.043. Caelogenys paca One of the largest rodents of So. & Cent. America (Paca).

1100.044 Myopotamus coypu So. American rodent - resembling beaver (Coypu).

1100.045. Dasyprocta aguti Rodent size of rabbit - So. America (Agonti)

1100.046. Cavia aperea (Guinea pig)

1100.047. Bathyergus maritimus. Mole-rat

1100.048. Ascomys canadensis. Parasitic crustacean

1100.049. Erythizon dorsatum (American porcupine)

1100.050. Cercolabes prehensilis.

1100.051. Sphingurus insidiosus. Animal like porcupine with prehensile tail.

1100.052. Castor fiber (Beaver).

1100.053. Arctomys empetra. Woodchuck

1100.054. Spalax typhlus (Mole-rat).

1100.055. Lepus timidus (Hare)

1100.056. Pedetes caffer (Jumping-hare)

1100.057. Sciurus vulgaris. (Squirrel)

1100.058. Lagomys pusillus (Pika or little "chief hare")

1100.059. Eriomys chinchilla (Chinchilla)

1100.060. Octodon cummingii So. American (Degu) rodent

1100.061. Capromys fournieri (Member of the rat family.

Pachydermata.

1100.062. Hyrax capensis. (Rock rabbit of the Cape of Good Hope)

1100.063. Sus scrofa. (Hog)

1100.064. Porcus babyrussa Wild swine (Babirussa)

1100.065. Dicolyles labiatus (White lipped peccary)

1100.066. Dicotyles torquatus (Collared peccary)

1100.067. Phacochoerus aeliani (Wort-hog).

1100.068 Tapirus malayanus (Tapir).

1100.069. Rhinoceros indicus. (Indian Rhinoceros).

1100.070. Hippopotamus amphibius (Hippoptamus)

1100.071. Elephas africanus (African Elephant)(Largest)

Bisulca and Solidungula.

1100.072. Cervus elaphus (Red-deer)

1100.073. Moschus moschiferus (Musk-deer)

1100.074. Ovis musimon (Corsican Sheep)(Sheep).

1100.075 Capra ibex (Alpine ibex) (Ibex).

1100.076. Auchenia llama (Llama).

1100.077. Bos taurus. (Ox).

1100.078 Camelus bactrianus. (Camel).

1100.079 Camelo pardalis giraffa. (Giraffe).

1100.080 Equus caballus — (Horse)

1100.081. Hippotigris zebra. (Zebra).

~~1100.082. Equus burchellii. (Burchelli's Zebra)~~ next page #1100.103

Marsupiatia and Edentata.

1100.083. Macropus giganteus. (Kangaroo).

1100.083 Phascolarctos cinereus. (Koala) Marsupial Ursidae or mammal resembling bear + sloth

1100.084. Phascolomys wombat (Wombat).

1100.085 Orycteropus capensis. (Aard-vark, earth-hog)

1100.086. Myrmecophaga jubata. (Ant-eater).

1100.087. Cheloniscus gigas. Tortoise or turtle

1100.088 Dasypus novem cinctus (Nine banded armadillo)

1100.089. Choloepus didactylus (Two toed sloth).

1100.090. Manis macroura (Long-tailed pangolin).

1100.~~092~~ 091. Chlamyphorus truncata. (Achiciago). Armadillo from Argentina

Cetacea and Monotremata.

1100.092. Halicore cetacea. Tusked aquatic herbivorous mammal resembling whale (Dugong).

1100.093. Manatus australis. Sea-cow (Manatee.)

1100.094. Balaenoptera rostrata (Finback whale)

1100.095. Physeter macrocephalus. (Sperm whale)

1100.096. Monodon monoceros. (Narwhal).

1100.097. Delphinapterus leucas (White whale)

1100.098. Phocaena communis. (Porpoise).

1100.~~100~~ 099. Tachyglossus hystrix Anteater (echidua).

1100.100. Ornithorhyncus fuscus. (Duck-bill).

1100.101. Lithofalca aesolon.

1100.102. Balaena mysticetus. (Greenland Whale).

1100.103 Equus Burchelli. (Horse)

1100.104. Gorilla

1100.20 Temporal bone, cut to show the mastoid cells, labyrinth, membrana tympani and ossicles.
Prepared by Dr David Gregg Metheny.
Deposited by Dr Howard Dehoney.

Changed to 1100.20a.

~~1100.21~~ Temporal bone, cut to ext. acoustic meatus, membrana tympani and ossicles, mastoid cells and labyrinth.
Prepared by Dr David Gregg Metheny.
Deposited by Dr. Howard Dehoney.

Changed to 1100.20B.

~~1100.22~~ Temporal bone cut to show, mastoid cells, antrum, tympanum and labyrinth The eustachian tube is opened.
Prepared by Dr David Gregg Metheny.
Deposited by Dr. Howard Dehoney.

Poltzer Collection

1100.201 to 1100.267

I. Normal anatomy.

1100.201-1100.202. The outer and inner surface of the membrana tympani, with the issicles of hearing. (From an adult)

1100.203. Two osseous auditory organs, showing the semicircular canals and the Eustachian tubes.

1100.204-205. The osseous auditory canal, with the membrana tympani and the ossicles.

1100.206. The cartilaginous part of the Eustachian Tube.

1100.207. Transverse section of the organ of hearing, showing the dimensions of the cavity of the drum.

1100.208-209. Horizontal section of the labyrinth, with a view of the structures in the cavity of the tympanum.

1100.210-211. (view from below-)

1100.212-213-222. The semi-circular canals and their topographical relation to the cavity of the drum (From an adult)

110.214-215-220-221-223-224-226. The cochlea and its topographical relation ~~the~~ to the drum-cavity. ?

1100.216-217-218-219. Membrana tympani, ossicular auditus, tendon of the tensor tympani, semi-circular canals, and cochlea, shown in their complete relation to each other.

1100.225. The cochlea and its topographical relation to the membrana tympani-The cochlea is opened.

b. Outer surface of the membrana tympani and the Eustachian tube, from an adult, right side.

c. The same, left.

d. " " ".

II. Pathological Specimens.

1100.227-228-229-230. Calcareous deposits in the membrana

tympani.

1100. 231. Funnel-shaped adhesion of the membrana tympani, below the manubrium, to the inner wall of the tympanic cavity.

1100. 232. An extensive perforation of the membrana tympani; small calcareous deposits in the remnant of the membrane.

1100. 233. Detachment of the lower part of the manubrium from the membrana tympani.

1100. 234. Almost entire destruction of the membrana tympani. Adhesion of the tip of the manubrium to the promontary.

1100. 235. Extensive perforation of the membrana tympani. Osseus anchylosis of the stapes

1100. 236-237 - Double perforation of the membrana tympani.

1100. 238 - Triple perforation of the membrana tympani; the long process of the incus destroyed; small cabcareous spot beneath the anterior perforation.

1100. 239. Extensive cicatrix upon the anterior half of the membrana tympani. (The cicatrix becomes very distinctly visible when the membrana tympani is moistened with a drop of water.)

1100. 240 Perforation of the membrana tympani; also an adhesion between a cicatrix of the membrana tympani and the inner wall of the tympanic cavity, so extensive as to entirely cover the tympanic mouth of the Eustachian tube.

1100. 241 - Perforation on the porterior half of the membrana tympani.

1100. 242 - Perforation of the membrana tympani. The remnant of the membrana tympani. Partly adherent to the inner wall of the drum cavity. The tympanic mouth of the Eustachian tube closed by a thin layer of cicatricial tissue.

1100. 243. Extensive calcareous and cicatricial degeneration of the membrana tympani and adhesion of the same to the inner

wall of the tympanum.

1100.244. Caries of the posterior wall of the auditory canal, erosion of the Fossa sigmoidea, Thrombosis in the sinus.

1100.245. a. Preparation showing the inclination of the membrana tympani to the horizon. (From an adult.)

b. The same, from a child.

c. View of the drum-cavity, normal bands of connective tissue between the ossicles of audition and the inner wall of the drum-cavity.

d. Topographical position of the ossicles of hearing, the tendon of the tensor tympani and the stapedius-(Seen from underneath.)

1100.246. a. Styloid process, several prongs.

b. The organ of hearing, with congenital constriction of the external auditory canal.

c. The organ of hearing, with congenital dilation of the external auditory canal.

1100.247. a. Muscles of the Soft palate and Eustachian; right, the abductor tubae; left, the Levator palati mollis and the abductor tubae.

b. Five transverse sections of the organ of hearing.

1100.248. Four sections through the mastoid process.

1100.249. a. Outer surface of the membrana tympani and the Eustachian tube. From a child, left side.

1100.250. Horizontal section of the organ of hearing.

1100.251. Horizontal section of the organ of hearing.

1100.252. Horizontal section of the Organ of hearing.

1100.253. Tr ans verse section of the internal ear.

1100. 254. Meatus auditorius externus; ossicles; vestibule; cochlea: nerve of hearing.

1100. 255. Internal appearance of the membrana tympani; the ligament of the malleus and incus; the Chorda tympani; tendo tensor tympani.

1100. 256. External auditory meatus; tympanic cavity; cochlea; nerve of hearing.

1100. 257. Frontal section of the tympanic cavity and vestibule.

1100. 258. Internal aspect of the tympanum and tympanic cavity; internal auditory canal.

1100. 259. Perforation and calcareous deposit in the membrana tympani.

1100. 260. Perforation of the membrana tympani; calcareous deposit in the margin of the perforation.

1100. 261. Perforation of the membrana tympani. Remains of the tympanum and manubrium of the malleus adherent to the promontory.

1100. 262. Destruction of the membrana tympani ex foliation of the incus. Circumscribed caries.

1100. 263. Tensor tympani muscle.

1100. 264. Tensor tympani muscle.

1100. 265. Bending of the facial nerve; tympanic plexus.

1100. 266. Longitudnial section of the styloid process, the superior part of which touches the posterior wall of the tympanic cavity.

1100. 267. Perforation of the tympanic membrane. Calcareous deposit in the anterior wall of the tympanic membrane.

413

Mesny

15 models

Plaster casts.

I Normal membrana tympani (right)

II. Tightly distended vesicular protuberance of the upper part of the membrana tympani, the Malleus partially covered by the tumor (left).

III. Large kidney-shaped perforation of the membrana tympani beneath the manubrium of the Malleus; the lower end of the manubrium and the upper edge of the perforation in contact with the promontory.

IV. Extensive destruction of the membrana tympani; the manubrium, partly stripped of its membranous covering, in contact with the swollen inner wall of the tympanum; in the posterior superior part of the perforation the lower part of the long process of the Anvil is visible.

V. Extensive loss of substance in the membrana tympani; the partly eroded malleus adherent to the inner wall of the tympanum; in the hinder part of the large perforation the lower end of the long process of the anvil is seen and below it the niche in which the round window lies.

VI. Kidney shaped perforation in the membrana tympani; on each side of the manubrium; oblong calcareous deposits.

VII. Destruction of the posterior and of part of the under portion of the membrana tympani; through the perforation may be seen the promontory and the niche for the round windows, and above the latter the incudo-stapedial joint.

VIII. Double perforation of the membrana tympani; the lower end of the manubrium connected with the remnant of the membrane by means of a narrow bridge-like band.

685 a
1194.40

1 IX. Heated perforation, kidney shaped cicatrix beneath the menubrium.

X. Oblong cicatrix on the hinder half of the membrane tympani, lying partly over the incudo-stapedial joint.

XI. Extensive cicatrix on the membrana tympani; the thin wrinkled cicatrix and the handle of the mallens in contact with the promontary.

XII. Oblong cicatrix behind the handle of the Mallens; the cicatrix is greatly depressed and in contact with the incudo-stapedial joint and the promontory.

XIII. Destruction of the hinder part of the membrane, the perforation is overgrown with panulations springing from the cavity of the tympanum.

XIV. Myringitis granulosa together with a central perforation in the memnrana tympani.

XV. Marked retraction of the membrana tympani; Manubruim drawn upward and inward, perspectively foreshortened; short process of the Mallens and posterior fold of the membrana tympani very prominent; the peripheral part of the drum head appears bent on the central portion.

Translation made by Dr. C. H. Burnett.

~~127 South 15th Street.~~

List of water color sketches of various conditions of the Membrana tympani. By Prof. A. ~~Pobtger~~ Politzer, of Vienna. Presented by him to the Museum.

1. Normal Drum-head or membrana tympani.

2. Hyperaemia ~~of~~ and injection of the vessels of the Manubrium

4. Injection and ecchymoses of the membrana tympani, acute otitis.

3. Injection of the vessels of the membrana tympani in acute otitis media.

5. Exudation on the membrana tympani, in a man 32 years old; duration three weeks.

6. Acute Myringitis with formation of vesicle on the membrana tympani; duration 36 hours; cure in two days.

7. Collection of Serum in the under part of the tympanic cavity, duration 3 days, cure by means of inflation.

8. Collection of tough yellow, mucous exudation in the tympanic cavity, six weeks duration. Cured by paracentesis of the membrane.

9. Cretaceous deposits on the membrana tympani, in front of and behind the manubrium of the malleus, after Otorrhea ~~rhoea~~, in a girl.

10. Cretaceous deposits and perforation, following otorrhoea of 14 days duration, four months previous, in a girl 15 years old.

11. Crescentic, gray, opacity behind the manubrium of the malleus in chronic sclerotic inflamation of the middle ear, in a man 45 years old.

12. Large cicatrix and calcification in the membrana tympani in a man 69 years old. Otorrhoea in childhood. Watch heard at 32 cm. Speech-10M

13. Rupture of the membrana tympani behind the manubrium of the malleus, in consequence of a "box on the ear" in a young waiter.

14. Central perforation, chronic otorrhoea for many years, in a woman of 40 years old.

15. Perforation of the membrana tympani, in a man 20 years old, duration 3 years.

16. Otitis media purutenta chronica; great swelling of the promontory, in a man 26 years old; duration 20 years.

17. Perforation and calcification in the membrana tympani, injection of vessels on the promontory; in a man 32 years old.

18. Double perforation in a girl 19 years old, Otitis purulenta since childhood.

19. Extensive perforation; manubrium laid bare; in a man 28 years old, duration since childhood; followed scarlatina.

20. Myringitis granulosa in a young woman: duration 16 years, cured by repeated applications of sequichloride of Iron

21. Kidney-shaped cicatrix beneath the manubrium, after otorrhoea in a man 28 years old.

22. Retraction of the membrana tympani in consequence of closure of the Eustachian tube, in a young man.

23. Great retraction of the membrana tympani, under part of manubrium visible, short process and posterior fold projecting.

24. Delicate, thin cicatrix behind the manubrium. lying close upon the promontory and the incude stapedial joint.

685 a
1194.40

5 cased - Case 2 - Shelf 2 - Basement 423
See Vol. III - Pg. 756

V. Capillary Vessels.

17830.59

The five cases furnished with inseriptions in gold letters contain microscopical injected preparations of the capillary system of all organs of man and of vertebrate animals Among these are objects, such as the pathological specimens the diseased conditions of the eye and many others, which have never yet been represented by injections-By means of microscopical injections I conduct a very lively trade with anatomists, anatomical societies and scientific physicians all over the world. A catalogue of my preparations to be disposed of, appeared this year: "Catalogue of microscopical injected preparations," which may be obtained by exchange or by purchase from J. Hyrtl. Vienna, 1873.

N. B. -The preparations marked with the letters AV are those on which arteries ans veins have been injected with differently colored materials.

I. Pathological Specimens.

1. Papilla of a suppurating wound.
2. Cicatrix after amputation.
3. Scrofulous cicatrix.
4. Small-pox cicatrix. (Skin of the face).
5. Telangiectasis of the upper lip.
6. Bronchial catarrh.
7. Pneumonia. AV and air vesicles.
8. Emphysema of the lung. Air vesicles.
9. Newly-formed vessels in a false membrane of the lung.
10. Hypertropic heart.
11. Arteriitis. Vasa vasorum of the poplitcal artery AV:

Intestinal villus. Cholera.

13. Basis of an ulcer of typhoid fever, constructed through the muscular membrane.

14. Cirrhosis of the liver AV.

15. Fatty degeneration of a paralyzed muscle.

16. Ossifying callus.

17. Periostitis. Syphilitic tophus of the tibia.

18. Ovarian cyst, young.

19. The same, old.

20. Colloid sac of the thyroid gland. AV.

21. Cystic hygroma of the patella.

22. Fibrous unterine polypus.

23. Bright's disease. Malpighian corpuscle and uriniferous tubule.

24. Hydrocephephalus. Lubarachnoid lymphplexus.

14830.59

II. Normal and pathological conditions of the capillary vessels of the eye.

1. Skin of the eyebrow.

2. Skin of the upper eyelid.

3. Palpebral conjunctiva.

4. The same with Meibomian glands.

5. Turning point of the palpebral conjuctiva into the bulbal conjunctiva.

6. Semilunar fold.

7. Ectropium of the lower eyelid (of twenty years duration with entire change of the capillary net, so that there is seen in it not a conjunctiva, but the skin of the cheek.)

8. Sclero conjunctiva.

9. Cronic catarrh (Lippitude) of the conjunctiva.

10. Hypertrophy of the papillary body of the conjunctiva. (Trachoma).

11. Keratitis artificially produced on the eye of an animal. New formation of blood-vessels.

12. Chemosis. Artificially produced on the eye of an animal.

13. Iris. Posterior surface, with the ciliary body.

14. Pupillary membrane. (Embryo of five months).

15. Ciliary body of the eye of an lynx.

16. Choroidal vessels.

17. Vasa vorticosa of the eye of a salamander.

18. Locus iridescens (Tapetum lucidum) of the eye of a fox.

19. Retina.

20. The same from a seal. AV.

21. Entrance of the arteria centralis into the colliculus nervi optici.

22. Capsule of the lens. (Embryo of six months).

23. Cerator palpebrae.

24. Lachramal sac (with the valvular protuberance on the inner wall). AV.

III. Genital organs. 17830-59

1. Large mymphae. External surface.

2. Internal surface of the same.

3. Nymphae.

4. Hymen.

5. Vagina. (Papillae.).

6. Mucous membrane of the uterus at the canal.

7. Arbor vitae in the canal of the cervix of the uterus AV

8. Decidua Hunteri(third month of pregnancy.)

9. Subperitonel blood-vessels of the uterus.

10. Subperitoneal lymphatic vessels of the same.

11. Broad uterine ligament. Lymphatic glands of the same.

12. Section of a child's ovary, with Graafian follicles.

13. Mucous membrane of the Fallopian tube, (from the Isthmus tubae).

14. Oviduct of the crocodile. AV.

15. Oviduct of Menopoma alleghaniense AV.

16. Uterus AV.

17. Lacteal ducts from the breast of a woman in pregnancy.

18. Seminal canal of the marmot.

19. Mucous membrane of the vesicula seminalis of man.

20. Corpus cavernosum pevis.

21. Caput gallinaginis of the Orang-outang.

22. Dartos.

23. Lymphatic vessels of the scrotum.

24. Fossa navicularis of the male urethra.

17830.59 IV. Uriniferous Tubules and Malpigian Corpuscles.

1. From the Leuciscus virgo.

2. " " Abramis brama.

3. " " Rana temporaria.

4. Origin of the uriniferous tubule from the capsule.

5. Uriniferous tubule of the Alligator sclerops.

6. " " " " Varanus niloticus.

7. " " "" and portal vein of the kidney of Coluber ratux.

8. Uriniferous tubule of Bipes Pallasii.

9. " " " Fulica atra.

10. Uriniferous tubule of Psittacus aestivus.

11. Tubuli Bellinian of the human kidney.

12. Convoluted tubules of the cortical substance.

2. Malpighian Corpuscles

13. From Anguilla muraena.

14. " pelobates fuscus.

15. " Proteus.

16. "Pleurodeles.

17. " Siredon Axolotl, with renal veins.

18. " Vipera Redi, with renal veins.

19. " Fasianus Gallus.

20. " Ornithorhynchus.

21. " Elephas.

22. From an embryo of seven months.

23. From a grown person.

24. From the Wolffian body of the embryo of a horse.

V. Various Tissues. 17830.59

1. Hairy scalp.

2. Skin of the face (brow).

3. Chin.

4. Glabella.

5. Palm.

6. vertical section of the same.

7. Back of the hand.

8. Tactile papillae of the finger points.

9. surface from the back of the finger.

10. Matrix of the thumb nail.

11. Sole of the foot.

685 a
1194.40
-b
8)

12. very large tactile papillae on the heel of a negro's foot.

13. Ball of the toes.

14. Tactile papillae of the ends of the toes.

15. Matrix of the nail of the great toe.

16. Tactile papillae from a bear's foot.

17. The same from a lion's claw.

18. The same from the sole of an ostrich's foot.

19. Skin from the leg of Rana esculenta.

20. The skin of the neck of the salamander.

21. The same from Triton.

22. The same from Proteus.

23. Skin of an eel's throat.

24. Skin around the opening of a sturgeon's mouth.

2. Intestinal CanaL.

25. Mucous membrane of the mouth (cheek)

26. " " of the pharynx.

27. Cardia AV.

28. Pylorus AV.

29. Intestinal villi at the beginning of the jejunum.

30. Intestinal villi of the ourang-outang.

31. Origin of the chyle vessels in the intestinal villi.

32. Peyer's glands.

33. Muscular coat of the small intestine.

34. Brunner's glands of the duodeuum.

35. Valvula Tulpii AV.

36. Vermiform process AV.

37. Caecum.

38. Colon, with solitary follicles. AV.

39. Rectum. AV.

40. Peritoneal view of the same. AV.

41. Drüsenmagen of Ardea garzetta. AV.

42. Intestinal villi of the ostrich. AV.

43. Intestinal villi in the small intestine of the goose AV.

44. Cloaca of the heron AV.

45. Bursa Fabrizii of Rhea americana. AV.

46. Stomach of the toad. AV.

47. " " " frog. AV.

48. " " " Hyla arborea.

49. " " proteus. AV.

50. " " Lelamandra atra AV.

51. " " Testudo tabulata.

52. Small intestine of Rana alpine. AV.

53. " " " proteus AV.

54. " " " Salamandra atra AV.

55. Large intestine of Rana alpine AV.

56. " " " Salamandra atra.

57. Junction of small with large intestine in Proteus AV.

58. Stomach of crocodile. AV.

59. " " shark. AV.

60. " " sturgeon AV.

3 Lungs.

61. Air vesicles of a child's lung.

62. Inflated lung AV.

63. Section of the same. AV.

64. Lung which has not yet breathed. (Embryo of six months) AV.

65. Mucous membrane of larynx.

66. Vocal cord.

67. Lung of a dog.

68. Lung of a salamander.

69. Lung of a crocodile. AV.

70. Cellular lung of a snake. AV.

71. Glottis Bufonis cinerei.

72. Gills of the Proteus.

4. Glands.

73. Human liver. Artery and portal vein.

74. The same. Artery, portal vein, and hepatic veins.

75. Section of the liver. Artery, portal vein, and gall vessels.

76. Lobule of pig's liver. Artery, portal vein, and hepatic vein. (vasa inter-und intralobularia).

77. Liver of Orang-outang. Hepatic veins, and portal vein.

78. " " the frog. " " " " "

79. " " " Triton " " " " "

80. " " a shark. AV.

81. Parotid gland with Steno's duct. AV.

82. Thyroid gland.

83. Spleen. AV.

84. Thymus gland.

5. Kidneys.

85. Malpighian tuft of the human kidney.

86. The same in Bright's disease.

87. Venous injection of

88. Urinferous tubules of Bellini of the pyramids.

89. Convoluted tubules of the cortical substance.

90. Section of the pyramid of a kidney A.V.

91. Renal papilla.

92. Urinary bladder..

93. Malpigian tuft and wriniferous of a bird's kidney Section.

94. Malpighian tuft of a kidney of a Proteus.

95. Triton's kidney. Renal arteries and veins.

96. Uriniferous tubule of the kidney of a crocodile.

6. Muscular and nervous system.

97. Diaphragm.

98. Mylo-hyoid muscle.

99. The same of the salamander

100. Muscle of snake.

101. Muscle of fish.

102. Tendo Achillis of the horse.

103. Myocardium of man.

104. Glenoid cavity of the shoulder blade.

105. Synovialis of the knee-joint.

106. Cortical substance of the brain.

107. Nervus ischiaticus.

108. Chorsid plexus of the lateral ventricle of the brain.

7. Various.

109. Periostium of tibia.

110. Anterior fontanelle.

111. Ossified cartilage.

112. Vasa vasorum. (Fermoral artery)

113. Mesentery. AV.

114. Mucous membrane of the Eustachian tube.

115. Giant papillae of the matrix of horse's hoof. Plantar surface.

116. The same. Dorsal surface.

117. Lacuna Morgagni of the rectum.

118. Stroma ovarii.

119. Caudal vertebrae of Menopoma.

120. Decidua Hunteri (from the third month of pregnancy).

685 a
1194.40
9-6
18)

443

6852

1194.40

9-6

18)

1307.21
VI
1003
30
4

Presented by Surgeon General U.S.A.

Gunshot injury of radius + ulna of left side
Bullet "6" Calibre .30; entrance wound, wound
of exit is below and external to olecranon,
irregular 2.13 inch diameter, or removing skin +
muscle the head of the radius is found
detached and split thro' the articular surface
into two very nearly equal halves, the projectile
struck ulna + lower segment entry splitting
bone into 3 fragments, The fracture thro' the
head of the radius is finely comminuted
no fissuring into elbow joint. The projectile
was dented on one side or conical end.

1307.45
VII
1004
30
4

Gunshot injury of rt. elbow joint, Bullet "3",
Calibre .30, Wound of entrance round 0.30
inches in diameter, Wound of exit is distinguished
by a longitudinal tear 2.76 inches in length
0.79 inch below the tip of the olecranon, The
coronoid process of the ulna and the
olecranon are comminuted into the joint,
Projectile slightly flattened at the conical
End. Presented by the Surgeon-General U.S.A.

1382.15
1006
30
4

Fracture of Pelvis; Bullet "3" Calibre .45 Range
250 yds. Pg. 965 - Vol. 1

1262.79(A)
995
29
4

Notes of gunshot injuries on the human body, conducted at Frankford Arsenal, Pa., on March 18, 1893, with the large and small caliber projectiles, for the purpose of noting the explosive effects at relatively short ranges.

I. Gunshot injury, left humerus, at junction of middle and lower thirds; bullet, No. 4, caliber .45; range, 17 yards. The wound of entrance is oval, 0.55 inch in its greatest diameter. The wound of exit is marked by a chasm on the back of the arm 4 inches in length, 2.36 inches in width, the edges of which are ragged. There is eversion of muscle and fat. The soft parts contain minute fragments of bone, which have been driven some distance into the tissues. The bullet struck the humerus at the junction of the middle and lower thirds. The foyer of fracture shows a loss of substance of the shaft 1.60 inches in length. There is extensive comminution. The fragments (twenty-three being readily counted) are greatly displaced, and the majority of them are free from the periosteum. The bullet is very much mushroomed, having lost about one-half in weight.

1262.79(B)
992
29
4

II. A gunshot injury by the .30-caliber projectile, at the same range, on the opposite arm produced a wound of entrance which is round, 0.35 inch in diameter. The wound of exit is 4.30 inches in length and 2.36 inches in width. It is marked by pulpification of the muscles, which contain bony sand. The missile struck the shaft of the humerus above the middle, comminuting the bone extensively, but not to the extent observed in the preceding injury with the .45-caliber leaden projectile. Fourteen principal fragments were readily counted. They are large, and not so much displaced as in the injury on the left humerus. The larger fragments are retained in place by their periosteal attachment. The fissures are not so extensive in the shaft above and below the seat of injury. The projectile was recovered, the leaden nucleus having escaped from the harder metallic mantle. The cylindrical part of the envelope is intact, the conical end having split in four pieces, one of which is entirely detached from the shell.

Notes on the effects of the projectiles of large and small caliber impressed by the velocity possessed at 100 yards, on the human body, conducted at Frankford Arsenal, Pa., January 10, 1893.

1397.0081
992
29
4

III. Gunshot injury of the upper third of the right femur; bullet No. 6, caliber .45. The wound of entrance is round, 0.47 inch in diameter; the wound of exit is ragged, quadrilaterally shaped, 0.79 inch in its longest diameter. The track of the wound from the bone posteriorly to the wound of exit is one pulpified mass, in which are found bony sand and many free splinters of bone. There are a number of fissures in the ends of the broken shaft; the longest in the upper fragment is 3.54 inches, extending to the anatomical neck. The projectile was very much set up.

1262.87
991
29
4

IV. Gunshot injury of the left humerus at the junction of the middle and upper thirds; bullet No. 8, caliber .45. The wound of entrance is round, 0.47 inch in diameter; the wound of exit is marked by a longitudinal tear, 3.15 inches long. The track of the wound between the posterior surface of the bone and the wound of exit contains a number of free splinters of bone. The lower fragment of the shaft shows one longitudinal fissure, 3.54 inches in length; the upper fragment has two longitudinal fissures, the larger being 1.57 inches in length. The projectile is mushroomed.

Notes on the effects of the projectiles of large and small caliber impressed by the velocity possessed at 150 yards, on the human body, conducted at Frankford Arsenal, Pa., January 10, 1893.

1262.85
1007
30
4

IV. Gunshot injury of the lower third of the right humerus into the elbow joint; bullet No. 9, caliber .30. The wound of entrance is round, 0.31 inch in diameter; the wound of exit is 1.18 inches above and internal to the tip of the olecranon. It is marked by a longitudinal tear, 0.79 inch in length. The projectile shattered the lower part of the shaft immediately above the spongy structure, fissuring the articular surfaces extensively into the elbow joint. The splinters were all free from the periosteum covering the shaft. The bullet was not deformed.

Notes on the effects of the projectiles of large and small caliber impressed by the velocity common at the range of 250 yards, on the human body, conducted at Frankford Arsenal, Pa., January 11, 1893.

1262.89
1005
30
4

IX. Gunshot injury of the left shoulder joint; bullet No. 6, caliber .45. The wound of entrance is round, 0.45 inch in diameter; the wound of exit is irregular, with torn edges, 1.18 inches in its greatest diameter. The projectile passed through the upper and outer portion of the head of the humerus, separating entirely the head from the shaft at the junction of the surgical and anatomical necks. The wound is full of finely pulverized débris; one fragment, 0.30 inch in length, remains attached to the periosteum. There are two fissures on the outer surface, the longest one being 2.50 inches down the shaft. The projectile was not recovered.

1151.44
1000
29
3

XIII. Gunshot injury of the skull; bullet No. 8, caliber .45. The wound of entrance is 2.17 inches above the middle of the right orbit. The explosive effects were so great as the bullet perforated the skull from before backward that the skull cap was literally blown to pieces. It is difficult on account of the great destructive effects to state even approximately the point where the bullet emerged from the skull posteriorly. The bullet is very much deformed at the conical end, flattened in the cylindrical portion near the base, and bent.

June 14, 1901 S.R.M.

Notes on the effects of the projectiles of large and small caliber impressed by the velocity common at 350 yards on the human body, conducted at Frankford Arsenal, Pennsylvania, January 12, 1893.

II. Gunshot injury of the left ankle joint; bullet No. 3, caliber .45. The wound of entrance is round, 3.54 inches in diameter, and torn, the tears radiating from the edges of the wound. The wound of exit is irregularly quadrilateral in shape, 0.79 inch in its greatest diameter. The bullet entered through the internal malleolus and made a grooved fracture of the astragalus; there is complete pulverization of the inner half of the articular surface of the tibia. The missile then passed out, piercing the posterior portion of the external malleolus, the anterior portion remaining attached to the shaft. The projectile was mushroomed.

1262.83
1008
30
C

Gunshot injury of left humerus (lower pt) into elbow joint, bullet no "C" calibre .45 – range 150 yds.
Wound of entrance is ~~round~~ marked by a longitudinal slit 0.79 inch in length, wound of exit measures 1.57 inches in its widest part; it is funnel shaped with the base of the funnel corresponding to the skin, the humerus was fractured just above the articular surface, comminuting the bone to the joint. The bullet was very much deformed laterally, being rolled as if it had been wrapped around a bone on impact.

1262.81
1009
30
H

Gunshot injury ~~left~~ right humerus, involving the head
250 yds –

1412.85
997
29
3

Vol. 1 Pg 1180
Fracture of Patella. Calibre 45. Range 1200 yds

1412.90
998
29
3

Vol. 1 Pg 1180
Fracture of Patella Calibre .30 Range 1200 yds.

1427.98
999
29
3

Vol. 1 Pg 1277
Fracture of Tibia & Fibula near ankle joint

1307.22
1010
30
4

From Surgeon-General, USA
Gunshot wound of radius & ulna, Calibre .45
Range 250, 500 gr. bullet. fract. involves inner surface of olecranon and has caused a comminuted fract. of upper portion of ulna

new no- 6045.10 see vol II Page 346
Flesh wound entrance & exit .30 Calibre
Range 500 yds.

447

1307.35
993
29
4

VIII. Gunshot injury of the right elbow joint; bullet marked "E," caliber .30. The wound of entrance is on the external aspect of the arm opposite the bend of the elbow, 2.36 inches from the olecranon; it is round, and equal in diameter to that of the projectile; the wound of exit is 0.59 inch below the tip of the olecranon; it is star-shaped, and 0.30 inch in its greatest diameter. The projectile passed through the head of the radius, permitting the outer and posterior aspect of the forearm to receive the wound; the head is split in two portions, one-half of which is finely comminuted, the outer half, together with its portion of the neck and 0.79 inch of the shaft, remains in place without much damage to the periosteum. The pulverized bone, comprising the inner half of the head, lies free in the joint. The projectile entered the ulna 0.20 inch below the joint, near the posterior margin of the lesser sigmoid cavity; the olecranon is completely crushed; fissures extend through the greater sigmoid cavity, and the posterior portion of the articular surface. There are seventeen small splinters detached from the periosteum about the foyer of destruction. The projectile was slightly dented on one side in the cylindrical portion; otherwise it sustained no deformation.

Notes on the effects of the projectiles of large and small caliber impressed by the velocity common at 500 yards on the human body, conducted at Frankford Arsenal, Pa., March 8, 1893. Some of the notes describing the lesions in the soft parts were unavoidably lost.

1307.40
994
29
4

VII. Gunshot injury right elbow; bullet No. 7, caliber .30. The ball entered the front of the right elbow joint in the middle line, fracturing the external and internal condyles obliquely and carrying away the central portion of the articular surface, which is finely comminuted. Two and thirty-six hundredths inches of the ulna, including the olecranon, were comminuted. The fissures were longitudinal. The radius was uninjured. The bullet was slightly set up at the conical end.

1397.095
1002
30
3

IX. Gunshot injury of the left knee-joint; bullet marked "A," caliber .45. The wound of entrance is round, 0.39 inch in diameter, 0.20 inch external to the upper external border of the patella; the wound of exit is in the popliteal space, irregular in shape, 0.59 inch in its greatest diameter. The projectile penetrated the external condyle 0.79 inch from the upper margin of the articular surface, and passed obliquely downwards and inwards, emerging through the articular surface posterior to the internal condyle. There is very slight displacement of splinters anteriorly, and only a small splinter displaced posteriorly; the latter is still held by cartilage at its upper margin. There is an inter-condyloid fracture, but the line of separation extends through the cartilage in its posterior part only. It may be seen through the cartilage anteriorly curving upwards along the trochlear surface towards its upper margin. The patella was not injured. The bullet was slightly dented at the conical end, also in the cylindrical part near the base.

1200 yards.

1397.097
1001
30
3

VII. Gunshot injury of the right knee; bullet No. 1, caliber .45. The wound of entrance is 0.30 inch internal to and above the patella; it is round, 0.45 inch in diameter; the wound of exit is in the middle of the popliteal space, star-shaped, 0.59 inch in its greatest diameter. The bullet entered the bone 1.18 inches above the articular surface. The diameter of the perforation corresponds to the diameter of the missile. The orifice of exit posteriorly admits the index finger and is situated in the popliteal space above the trochlear surface on the inner side of the median line. The bullet was recovered, very little dented at the conical end.

101 new no. 6045.11 see vol II Page 346
30
3. Flesh wound thigh + left.
Caliber .45 – 500 grains – 500 yds

new no. 1652.15 see vol I Page 1599.
1613
30
3 Comminuted fragments, fract left knee joint, Caliber .45 500 yds
Vol. I-Pg. 1599

Gunshot Fractures
Presented by U.S. Base Hospital No. 10. 115 spec. 449
(Pennsylvania Hospital Unit)

1111.100 Skull Col. No. 151 (see filing cards)
1111.102 Skull and clavicle Col. No. 153
1111.104 Skull and fibula Col. No. 136

1111.110 Face Col. #17

1111.120 Skull cap Col. No 186
1111.122 Skull cap and shell fragment Col. No 164
1111.124 Skull cap Col. No. 124
1111.126 Skull cap Col. No. 126
1111.128 Skull cap. L. Femur (lower half). Rifle bullet. Col. No. 143
1111.130 Skull cap, bullet and driving band. Col. No. 152
1111.132 Skull cap and shrapnel ball Col. No. 146
1111.134 Skull cap and bomb fragment Col. No. 145
1111.136 Skull cap Col. No. 102
1111.138 Skull – upper part. Col. No. 87
1111.140 Skull cap and part of left orbit Col. No 170

1111.160 Part of skull cap. Col No 52a
1111.162 Temporal and shell fragments. Col No 174
1111.164 Skull left temporal region Col. No 93
1111.166 Skull (temporal region) and part of mandible Col. No. 30
1111.168 Skull. Right temporo-occipital region and dura. Col. No. 36
1111.170 Skull, posterior half. Col. No. 156
1111.172 Skull, right side, and atlas, right side. Col. No. 86

1111.200 Atlas and axis. Col. No. 190

1111.210 Vertebral column and shell fragment Col. No. 11
1111.211 Vertebral column and nose piece of shell Col. No 179
1111.212 Dorsal vertebrae and shrapnel shrapnel bullet. Col. No 139

(see filing cards)

1111.213 Four vertebrae Col. No-125
1111.214 Vertebrae. Col. No-150
1111.215 Two vertebrae, ribs and shell fragment Col. No. 16
1111.216 Vertebrae and parts of two ribs Col. No. 88

1111.230 Vertebral column. Col. No-172
1111.231 Vertebral column. Col No 23
1111.232 Vertebral column and shrapnel ball Col. No-14
1111.233 Two lumbar vertebrae Col No. 149
1111.234 Lumbar vertebrae. Col. No-199
1111.235 Lumbar vertebrae and rifle bullet. Col. No. 141

1111.300 Thorax, right anterior portion, and shell fragment. Col. No 43
1111.301 Rib, clavicle, radius and ulna and part of frontal bone. Col. No. 24

1111.325 Sternum Col. No 81

1111.350 Clavicle, left. Col. No. 169

1111.375 Scapula, left Col. No. 37
1111.376 Scapula, left Col. No. 7

1111.400 Humerus, right, lower part Col No. 12
1111.402 Humerus (right) upper half and hand (right). Col. No. 18
1111.404 Humerus (left) lower half. Col. No 46
1111.406 Humerus (left) Col. No. 56
1111.408 Humerus (left) lower half. Col. No. 140
1111.410 Humerus (left) Col. No-153a

1111.450 Elbow joint. (right) Col. No. 13
1111.452 Elbow joint (left) Col. No - 32
1111.454 Elbow joint (right) Col. No 188

1111.500 Radius [illegible] ulna (left) Col. No. 187

1111.502 Radius, ulna (right) lower half. Col. No. 94

(see filing cards)

~~1111.600 Hand~~ see no. 1111.402

1111.610 Finger. (4th) Col. No 9

1111.700 Pelvis Col. No- 148
1111.702 Pelvis Col. No 40
1111.704 Pelvis - Col. No 138
1111.706 Pelvis - Col. No-138P
1111.710 Pelvis and upper parts of femurs. Col. No. 177
1111.712 Pelvis and head of femur. Col. No. 10
1111.714 Sacro-iliac joint (right) with shell fragment. Col. No. 25
1111.716 Innominate bone and femur (right) Col. No. 48
1111.718 Portion of innominate and head of femur. Col. No. 109
1111.720 Part of innominate (right) Col. No. 101
1111.722 Innominate bone (right) with shell fragment. Col. No. 176
1111.724 Ilium (right) Col. No. 157

1111.750 Sacrum and portion of innominate. Col # 59
1111.752 Sacrum and innominate bone (right) Col. No 165
1111.754 Sacrum, part of ilium (left) and lumbar vertebrae Col. No. 175
1111.756 Sacrum, part of ilium (left) and rifle bullet. Col. No. 181

1111.775 Sacrum (right half) Col. No. 57
1111.776 Sacrum, Col. No. 49
1111.778 Sacrum. Col. No. 27
1111.780 Sacrum. Col. No. 19

1111.800 Femur Col. No-114B
1111.802 Femur. Col. No-30
1111.804 Femur (right) lower half Col. No. 171
1111.806 Femur (right) upper half with fragment of driving band Col. No. 158
1111.808 Femur (right) lower half. Col. No. 118
1111.810 Femur (left). Col. No. 115
1111.812 Femur (right). Col. No. 110
1111.814 Femur (left) Col. No-90
1111.816 Femur (left) lower half. Col. No- 85
1111.818 Femur (right). Col. No. 83
1111.820 Femur (left) lower half. Col. No 80
1111.822 Femur (right). Col. No. 68
1111.824 Femur (right) lower half. Col. No. 52
1111.826 Femur (right) lower half and shrapnel ball. Col. No. 44

1111.828 Femur (left) Col No 35 (see filing cards)
1111.830 Femur (right) Col no 2

1111.850 Knee joint (left) Col. No 50
1111.852 knee joint (left) Col. No. 51
1111.854 Knee joint (left) Col. No. 53
1111.856 Knee joint (left) Col. No. 60

1111.900 Tibia and fibula Col. No. 114a
1111.902 Tibia, fibula and shell fragment Col. No. 189
1111.904 Tibia and fibula (right) Col. No. 184
1111.906 Tibia, fibula (right) and shell fragment. Col. No 167
1111.908 Tibia and fibula (left) upper halves Col. No 160
1111.910 Tibia and fibula (left) Col. No. 159
1111.912 Tibia and fibula (right) lower two-third Col. No 137
1111.914 Tibia and fibula (right) Col. No. 125
1111.916 Tibia and fibula (left) Col. 106
1111.918 Tibia and fibula (left) Col. No 82
1111.920 Tibia and fibula (left) Col. No. 58
1111.922 Tibia and fibula (right) Col. No 55
1111.924 Tibia and fibula (right) Col. No 54
1111.926 Tibia and fibula (shafts) (right) Col. No 47
1111.928 Tibia and fibula (left) Col. No 45
1111.930 Tibia and fibula (shafts) Col. No 38

1111.950 Tibia (left) upper half. Col. No 168
1111.952 Tibia (right) upper half. Col. No 167
1111.954 Tibia (left) upper half. Col. No 166
1111.956 Tibia (left) upper half. Col. No. 14
1111.958 Tibia (lower half) and astragalus (left) Col. No 133

Page 263

~~1125.05~~ 1040.15 Left arm and hand Presented by Dr. John H. Brinton

~~1125.10~~ 1040.20 Bones of the left arm and hand " " " " " "

Page 263

missing Page 265

1048.10 ~~1125.55~~ Left leg and pelvis. Presented by Dr. John H. Brinton.

~~1125.60~~ ~~Right Femur, Tibia and Fibula, articulated~~ Dupl.

1123.10 Osteo-periosteal bone graft by subcutaneous method. The time which elapsed ~~of~~ between the operation and the autopsy was 211 days. Note the perfect graft which is good, thick and strong
From the University of Pennsylvania
Department of Surgery
Dr. Dorrance.

1123.15 Osteo-periosteal Bone graft by subcutaneous method Graft was in place for 213 days. Remained attached to the left side only. Perhaps the continuous action of the muscles caused the non-union of one end.
From the University of Pennsylvania
Department of Research Surgery
Dr. Dorrance.

1123.20 Osteo-Periosteal Bone Graft by subcutaneous method The graft was in place for 2.4 days.
From the University of Pennsylvania
Department of Research Surgery
Dr. Dorrance.

1126.17 to 1126.31 Inclusive on Page 338 Vol II old Catalogue

LUXATION OF BONES.

1125 Bones of the upper extremity articulated with springs so as to demonstrate luxations.
#251 Sec 8 Shelf 6

~~1126~~ 1125.50 Bones of the lower extremity articulated with springs so as to demonstrate luxations.
252 Sec 8 Shelf 6

253 = Ilium (No old number)
Sec 9 Shelf 6

254 Tibia, fibula and Astragalus (No old number)
Sec 9 Shelf 6

255 = Humerus (No old number)
Sec 9 Shelf 6

256 = Femur (No old number)
Sec 9 Shelf 6

257 = Tibia (No old number)
Sec 9 Shelf 6 1005.17 see page 173

258 = Femur, tibia and fibula articulated (2 specimens) Page 173
Sec 8 Shelf 6 250 see page 173 (No old number) sec 8 shelf 6 1005.16

259 = Humerus (No old no.)
Sec 8 Shelf 6

260 = Femur - Head & upper 2/3 (No old number)
Sec 9 Shelf 6

261 Femur lower 1/4 (No old Number)
Sec 9 Shelf 6

262 " " " " "
Sec 9 Shelf 5

over

263 Femur lower ½ (No old number) 45

Sec 9
Shelf 5

264 Femur upper ½ " " "

Sec 9
Shelf 5

265 Femur lower ⅓ " " "

Sec 9
Shelf 5

267 Ileum (No old number

Sec 9
Shelf 5

268 Radius and ulna (articulated) (No old Number)

Sec 9
Shelf 5

269 Astragalus and Calcaneum

Sec 9
Shelf 5

270 Clavicle (No old number)

Sec 9
Shelf 5

271 Superior Maxillary (section at symphysis)
(No old number)

Sec 8
Shelf 4

272 Superior " " " "

Sec 8
Shelf 4

273 Atlas and Axis " "

Sec 8
Shelf 4

1036.05

~~417 Follows Humerus, Radius and Ulna.~~

Sec 11
Shelf 6

~~273.~~
~~(2 specimens)~~

1128. Absorption of sternum by pressure
Dr Allee

459

685 a
1194.40
-b
18)

461

6852

1194.40

9-b

18)

463

685 a
1194.40
9-b
18)

465

685 a
1194.40

CRANIA.

1143.00 441
1143.01 442
1143.02 443
1143.03 444
1143.04 445
1143.05 446
1143.06 447
1143.07 448
1143.08 449
1143.09 450
1143.10 451
1143.11 452
1143.12 453
1143.13 454
1143.14 455
1143.15 456
1143.16 457
1143.17 458
1143.18 459

Plaster Casts of Peruvian Skulls illustrating Primitive Trephining.

#440. 1143.00 to 1143.18

PRIMITIVE TREPHINING, ILLUSTRATED BY THE MUÑIZ PERUVIAN COLLECTION.

The Muñiz collection was brought together by Señor Manuel Antonio Muñiz, M. D., Surgeon-General of the Peruvian army. It comprises 19 specimens representing the trephined portion of a collection embracing about 1000 skulls. Five specimens come from the vicinity of Cuzco, 11 from Huarochiri and the neighborhood, and 1 each from Tarma, Pachacamac and Cañete. This material thus represents a considerable area. The collection was brought to this country for exhibition at the World's Congress of Anthropology held in connection with the Columbian Exposition at Chicago, and has been placed in the custody of the Bureau of American Ethnology for publication. Two of the crania remain in this country, one in the Bureau above mentioned and the other in the Army Medical Museum; the remaining 17 will shortly be returned to Lima to be preserved in the Museum of the Peruvian Geographic Society.

have been the weapons used among the ancient Peruvians. An operation essentially of the first type was begun, but only three incomplete incisions were made and the button was not removed when the work was discontinued, probably by reason of the death of the patient. The second example shows marks of a similar fracture in the posterior portion of the left parietal; in this case four incisions of the first type (although one is oblique) were made, and the operation was carried far enough to remove the button, but not the jagged edges resulting from fracture and operation, this individual also apparently dying in the hands of the operator. A third specimen displays a compound fracture involving the left temporal suture; and in this case an operation was performed by scraping, producing an elliptical aperture about five-eighths by three-quarters of an inch; and there is in addition a simple vertical incision such as those produced in the first type of operation, which apparently represents the first stage of supplementary treatment. This individual also apparently died before the final operation was completed. Another example exhibits a linear fracture fully six inches long, extending from near the center of the occipital across the lower portion of the right parietal and across the temporal, disappearing under the zygomatic arch. The treatment in this case consisted of scraping at several points along the fracture, including a scraped trephining, yielding an aperture of about three-eighths of an inch in the occipital bone not far from the termination of the fracture. This operation would appear to have been completed to the satisfaction of the surgeon. Then, as indicated by the condition of the specimen (a mummy in which a considerable part of the scalp is preserved), the scalp was laid open over the occiput and two incisions representing an operation of the first type, together with a minor vertical cut, were partially completed before treatment was finally abandoned, apparently by reason of death. Thus, while it can hardly be said that these four examples demonstrate the ante-mortem date of the operation, since it is just conceivable that they might represent post-mortem exploration, they nevertheless prove that, if ante-mortem, the operation was surgical; and the ante-mortem date of the operation in some cases is proved by examples already noted.

1143.18

1143.00

1143.04

685a

1194.40

1143.00 441
1143.01 442
1143.02 443
1143.03 444
1143.04 445
1143.05 446

Plaster Casts of Peruvian Skulls illustrating Primitive Trephining.

P. 467 A

The 19 specimens may be arranged in such order as practically to tell their own story. About half are of interest chiefly as indicating the manner in which the operation was performed. Three types of operation are exemplified.

In the first type four linear incisions were made in the cranium in parallel pairs intersecting each other at right angles so as to form a rectangular button; the incisions being narrow, v-shaped in cross section, and gradually increasing in depth from ends to center, thus indicating that the instrument was a pointed bit of stone or arrow-head held vertically and operated by reciprocal motion. This suggestion gains strength from the fact that American Indians are known to have produced incisions in bone in this fashion. This type of operation is rude and the resulting traumatism is jagged, each incision extending perhaps half an inch beyond the button at each extremity. There is no indication of the purpose of the operation of this type in any case, and nothing to suggest that if the operation was ante-mortem the individual survived. Aberrant examples of this type exhibit three or more parallel incisions, one example consisting of three approximately parallel incisions in each of the two rectangular sets forming a quadruplicate button or four coincident rectangles of which one remains, the other three being completely removed; and in another example the incisions of the rectangular system are still more numerous, and there are some oblique incisions, nearly four square inches of bone being removed and no fewer than 20 distinct incisions showing about the margin of the aperture.

In the second type of operation the incision was evidently made also by a rudely pointed instrument, probably of stone, held vertically and moved reciprocally; but as the cutting reached and penetrated the inner table, the locus of incision was moved forward and at the same time the direction of the sawing was changed so as to produce a rudely curved cut and, when two such incisions were made, an irregularly elliptical button. Some examples indicate that this type of operation was completed by scraping or grinding away the jagged surfaces left by the incision.

The third type of operation was performed largely or wholly by scraping in such manner as to remove the outer t e and

685 a
1194.40

~~1140.~~ 1143.00 to 1143.18

PRIMITIVE TREPHINING, ILLUSTRATED BY THE MUÑIZ PERUVIAN COLLECTION.

The Muñiz collection was brought together by Señor Manuel Antonio Muñiz, M. D., Surgeon-General of the Peruvian army. It comprises 19 specimens representing the trephined portion of a collection embracing about 1000 skulls. Five specimens come from the vicinity of Cuzco, 11 from Huarochiri and the neighborhood, and 1 each from Tarma, Pachacamac and Cañete. This material thus represents a considerable area. The collection was brought to this country for exhibition at the World's Congress of Anthropology held in connection with the Columbian Exposition at Chicago, and has been placed in the custody of the Bureau of American Ethnology for publication. Two of the crania remain in this country, one in the Bureau above mentioned and the other in the Army Medical Museum; the remaining 17 will shortly be returned to Lima to be preserved in the Museum of the Peruvian Geographic Society.

have been the weapons used among the ancient Peruvians. An operation essentially of the first type was begun, but only three incomplete incisions were made and the button was not removed when the work was discontinued, probably by reason of the death of the patient. The second example shows marks of a similar fracture in the posterior portion of the left parietal; in this case four incisions of the first type (although one is oblique) were made, and the operation was carried far enough to remove the button, but not the jagged edges resulting from fracture and operation, this individual also apparently dying in the hands of the operator. A third specimen displays a compound fracture involving the left temporal suture; and in this case an operation was performed by scraping, producing an elliptical aperture about five-eighths by three-quarters of an inch; and there is in addition a simple vertical incision such as those produced in the first type of operation, which apparently represents the first stage of supplementary treatment. This individual also apparently died before the final operation was completed. Another example exhibits a linear fracture fully six inches long, extending from near the center of the occipital across the lower portion of the right parietal and across the temporal, disappearing under the zygomatic arch. The treatment in this case consisted of scraping at several points along the fracture, including a scraped trephining, yielding an aperture of about three-eighths of an inch in the occipital bone not far from the termination of the fracture. This operation would appear to have been completed to the satisfaction of the surgeon. Then, as indicated by the condition of the specimen (a mummy in which a considerable part of the scalp is preserved), the scalp was laid open over the occiput and two incisions representing an operation of the first type, together with a minor vertical cut, were partially completed before treatment was finally abandoned, apparently by reason of death. Thus, while it can hardly be said that these four examples demonstrate the ante-mortem date of the operation, since it is just conceivable that they might represent post-mortem exploration, they nevertheless prove that, if ante-mortem, the operation was surgical; and the ante-mortem date of the operation in some cases is proved by examples already noted.

1143.18

1143.00

1143.04

1143.00 441
1143.01 442
1143.02 443
1143.03 444
1143.04 445
1143.05 446

Plaster Casts of Peruvian Skulls illustrating Primitive Trephining.

V. 1 p. 467a-b

P 467 b

diploë and reduce the inner table to a feather-edge. Some of the examples suggest that the scraping, which may easily have been effected with stone instruments and gives no indications of the use of metal, represents the final part of an operation begun by the curved incision.

Several specimens show by spicules of reparative growth and by the partial absorption of the outer table and diploë that the patient survived the operation, and hence that the trephining was ante-mortem. One individual appears to have long survived an operation forming a rudely circular aperture about three-quarters of an inch in diameter in the posterior portion of the cranium, and probably also for a short time a similar operation involving the metopic suture (which in this case is distinctly preserved). Another individual long survived two operations, probably of the second type, giving apertures nearly an inch in diameter, but apparently died about the time of the completion of a third trephining involving the coronal and sagittal sutures. A third individual long survived, as indicated by the reparative spicules and the complete absorption of outer table and diploë, an operation by scraping giving a rudely circular aperture about an inch in diameter. In none of these cases is the purpose of the operation evident.

1143.07

1143.11

1143.03

One specimen exhibits an operation of the first type remarkable for the small area involved. Although the skull is fully quarter of an inch thick, the parallel incisions are not more than three-eighths of an inch apart. In this example the surrounding bone exhibits a spongy texture indicating a diseased condition; and it seems possible that the operation was designed to relieve attendant symptoms after the manner of the primitive "medicine" of the American Indians, *e. g.*, by liberating an evil spirit; if so, the trephining in this case was thaumaturgic, and the example is noteworthy as the only one suggesting thaumaturgy.

Several examples are exceptionally noteworthy in that they prove the operations to have been surgical. In the first example the cranium shows a depressed fracture of the left temple such as might have been produced by impact of a sling-stone or blow from a spiked club, which are known to

1143.13

~~1140.~~ 1143.00 to 1143.18

PRIMITIVE TREPHINING, ILLUSTRATED BY THE MUÑIZ PERUVIAN COLLECTION.

The Muñiz collection was brought together by Señor Manuel Antonio Muñiz, M. D., Surgeon-General of the Peruvian army. It comprises 19 specimens representing the trephined portion of a collection embracing about 1000 skulls. Five specimens come from the vicinity of Cuzco, 11 from Huarochiri and the neighborhood, and 1 each from Tarma, Pachacamac and Cañete. This material thus represents a considerable area. The collection was brought to this country for exhibition at the World's Congress of Anthropology held in connection with the Columbian Exposition at Chicago, and has been placed in the custody of the Bureau of American Ethnology for publication. Two of the crania remain in this country, one in the Bureau above mentioned and the other in the Army Medical Museum; the remaining 17 will shortly be returned to Lima to be preserved in the Museum of the Peruvian Geographic Society.

have been the weapons used among the ancient Peruvians. An operation essentially of the first type was begun, but only three incomplete incisions were made and the button was not removed when the work was discontinued, probably by reason of the death of the patient. The second example shows marks of a similar fracture in the posterior portion of the left parietal; in this case four incisions of the first type (although one is oblique) were made, and the operation was carried far enough to remove the button, but not the jagged edges resulting from fracture and operation, this individual also apparently dying in the hands of the operator. A third specimen displays a compound fracture involving the left temporal suture; and in this case an operation was performed by scraping, producing an elliptical aperture about five-eighths by three-quarters of an inch; and there is in addition a simple vertical incision such as those produced in the first type of operation, which apparently represents the first stage of supplementary treatment. This individual also apparently died before the final operation was completed. Another example exhibits a linear fracture fully six inches long, extending from near the center of the occipital across the lower portion of the right parietal and across the temporal, disappearing under the zygomatic arch. The treatment in this case consisted of scraping at several points along the fracture, including a scraped trephining, yielding an aperture of about three-eighths of an inch in the occipital bone not far from the termination of the fracture. This operation would appear to have been completed to the satisfaction of the surgeon. Then, as indicated by the condition of the specimen (a mummy in which a considerable part of the scalp is preserved), the scalp was laid open over the occiput and two incisions representing an operation of the first type, together with a minor vertical cut, were partially completed before treatment was finally abandoned, apparently by reason of death. Thus, while it can hardly be said that these four examples demonstrate the ante-mortem date of the operation, since it is just conceivable that they might represent post-mortem exploration, they nevertheless prove that, if ante-mortem, the operation was surgical; and the ante-mortem date of the operation in some cases is proved by examples already noted.

1143.18

1143.00

1143.04

685 a
1194.40

1143.00 441
1143.01 442
1143.02 443
1143.03 444
1143.04 445
1143.05 446
Plaster Casts of Peruvian Skulls illustrating Primitive Trephining.

6852
1194.40
~~1140.~~ 1143.00 to 1143.18

PRIMITIVE TREPHINING, ILLUSTRATED BY THE MUÑIZ PERUVIAN COLLECTION.

The Muñiz collection was brought together by Señor Manuel Antonio Muñiz, M. D., Surgeon-General of the Peruvian army. It comprises 19 specimens representing the trephined portion of a collection embracing about 1000 skulls. Five specimens come from the vicinity of Cuzco, 11 from Huarochiri and the neighborhood, and 1 each from Tarma, Pachacamac and Cañete. This material thus represents a considerable area. The collection was brought to this country for exhibition at the World's Congress of Anthropology held in connection with the Columbian Exposition at Chicago, and has been placed in the custody of the Bureau of American Ethnology for publication. Two of the crania remain in this country, one in the Bureau above mentioned and the other in the Army Medical Museum; the remaining 17 will shortly be returned to Lima to be preserved in the Museum of the Peruvian Geographic Society.

1143.16

One of the specimens is of exceptional interest in several ways. The skull is small and thin; the anchylosis of the sutures is so far progressed as to indicate an age of twenty-five or perhaps thirty years; while the development of the teeth indicates an age not exceeding twelve years. In this case the aperture, which is on the right side, is of remarkable size, extending from the frontal within three-quarters of an inch of the orbital cavity across the coronal suture nearly to the center of the parietal, its length being fully four inches and the width averaging an inch. The specimen is of interest also in that it was the only one in which a plate is known to have been used, a silver plate having been found in place over the aperture in the mummy case. The presence of the plate, its seat in the skull showing long wear, and the absorption and reparative growth, all indicate that the operation was survived. No wound appears in the vicinity of the trephining, but there is a traumatic depression on the left side of the frontal an inch and a half above the orbital cavity and about the same distance from the center line, apparently due to a blow, such as produced the depressed fractures in other examples, suffered in early life when the bone was soft. Now, while the operation cannot directly be traced to this traumatism, it is suggested that this wound produced the abnormal, perhaps epileptic, condition which is indicated by other characters of the skull; and that the enormous trephining represents successive operations designed to relieve this condition. If these inferences be true, it will follow that the operation in this case was not only surgical, but parallel with the non-traumatic trephining of modern practice, thus indicating a considerable advance in medical knowledge and surgical skill.

On the whole, the Muñiz collection, which is by far the largest and most instructive assemblage of specimens of primitive trephining thus far brought together, is of special note in that it demonstrates certain points heretofore obscure with respect to primitive trephining. The most important conclusions are: (1) That the operation was ante-mortem, since five individuals out of the nineteen represented certainly, and two or three more probably, survived one or more operations; and (2) that the trephining was surgical. Two provisional conclusions of importance are also indicated by the collection: (3) that the operation was used in a medical way to relieve a general pathologic condition; and (4) that the operation was, as indicated by the total absence of marks of metallic instruments, anterior in date to the Spanish invasion and thus essentially prehistoric.

[From *The Johns Hopkins Hospital Bulletin*, No. 37, January-February, 1894.]

6852
1194.40

per

471

1145-
432.
Case 16.

Skeleton of a giant;lateral spinal curvature.

Height 2.3m. (7f.4. 6.3 in).

This skelaton is that of a young man probably 22-24 years old. The epiphyseal lines are plainly marked. The height of the skeleton as it stands would have been considerably augmented were it not for a lateral curvature of the spine;this must have diminished the height at least 8 cm. (3 in.+).

Among the noteworthy features of this skeleton are-

The cranial capacity,- 2320 cc.

The antero-posterior diameter of the chest,43 cm.,largely increased by the rotation of the spinal column,which at the ninth dorsal vertebrae,points nearly at right angles to the antero-posterior plane of the body.

		Normal skeleton,male age
The length of the femora,	65 cm.	45.5
" " " " tibia,	55 cm.	37.5
" " " " humeri	47.5 cm.	33.5
" " " " and metatarsal	9.5 cm.	7.5

Between the anterior superior spinous processes of the ilia,35 cm.

Antero-posterior diameter of the superior strait,14cm. (5.5in)

The depth of the acetabula. The lamina of bone between them and the pelvic cavity is very thin. The pressure of the femora has caused this lamina to encroach on the pelvic cavity and to present rounded prominences below the pectineal line. Fissures are seen on both sides in these eminences,parallel with the pectineal line. There is also a great exaggeration of the grooves for the obturator intermus as it lies over the innominate bone above the tuberosities of the ischii.

The sacrum is 16 cm. broad. The coccyx is in two portion segments. The superior segment has a breadth of 8 c

transverse colon following suppurative peritonitis. Disseminated tubercles in the lungs. There are areas of ossification in the costal cartilage. The left clavicle articulates with the first rib.

Height 1.73 m.

Purchased. 1882
from F. V. Rokon Munich

1145.20- Adult male; age 30 years.
421 Case 12.
Skeleton of Wilhelm Seiler; German descent; lithographer. Autopsy July 9th, 1882. Number of the protocal of the Pathological Institute of Vienne 77273/1057. Result of dissection: Ulcerating epithelial carcinoma of the oesophagus; stenosis of the same at the level of the bifurcation of the trachea. Old pulmonary tubercles. Chronic intestinal catarrh.

Purchased from
F. V. Rokon, Munich
1882

1145.25- Skeleton of Lucas Puskarczyk, age 32 years.
423 Case 14.
Purchased from
F. V. Rokon 1882

1145.30- Skeleton of a female, age 29 years. Marie Donker.
422 Case 12
Domestic. German descent. Pelvis flattened.
Purchased from
F. V. Rokon, Munich - 1882

1145.35- Skeleton of a ~~male~~ FEMALE, age ~~24~~ years. Solar Leopoldine
425 Case 14
~~Rosa Heikl~~. ~~Day laborer~~ Female.
Purchased from
F. V. Rokon - Munich - 1882

1145.40- Skeleton of a female, age 24. Rosa Heikl
420 Case 12
Day laborer
Purchased F. V. Rokon 1882

1145.45- Skeleton of a female.
427 - Case 15
Showing the result probably of tight lac...

For pelvic measurements, see 1365.07

Transversely contracted pelvis.

pelvic meas. 1365.07 Purchased

1145.50- Skeleton showing general exostosis deformity of the skull; fracture of the sternum united.

Case 12

Transversely contracted pelvis.

For pelvic measurements, see 1365.08

1145.55- Skeleton. Antero-posterior spinal curvature and caries.

431

Case 16

This skeleton is in. high. The curvature is most prominent in the lower dorsal and the lumbar spine, the convexity being backwards. The bodies of the lower seven dorsal and all the lumbar vertebrae are more or less destroyed, the last dorsal ~~the~~ and the first two lumbar, being most markedly affected. Below the eighth dorsal the intervertebral discs have disappeared and auchylosis has occurred between the spinous processes of all the vertebrae below the ninth dorsal; the remains of the lumbar vertebrae are firmly co-ossified. The articulating surfaces of many of the lower ribs are carious. The sacrum is roughened anteriorly and presents two or three slight exostoses. The upper epiphysis of the left tibia is separable from the shaft; the corresponding apiphysis on the right side has united with the shaft. The sternum is bowed.

The spinal curvature and the merging together of the diseased vertebrae have materially diminished the height of the skeleton and has brought the tenth and eleventh ribs almost in contact with the crest of the ilium. Transversely contracted pelvis

For pelvic measurements see 1365.11

1145.60- Skeleton of a female showing long standing antero-posterior spinal curvature anchylosis. See 1365.10

429
Case 17

Purchased.

1145.65- Skeleton showing spinal curvature and anchylosis.
Curves of the lower dorsal + all of the lumbar vertebrae.

428
Case 15

1145.70- Skeleton of a negro chil, age 6 years. Hydrocephalus.

430
Case 17

Circumference of head 70.5 cm.
27.75 in.

Above the right frontal region is an opening in the skull covered only by thin membrane. During life this was expanded so as to form a prominence on the skull. The longitudinal suture deviates to the left. There are numerous Wormian bones. Photograph of this child while living - is filed in the Museum - (#15400)

1145.75- Skeleton of a rachitic woman in whom Caesarean Section was performed.

433
Case 17a

Deposited by the Phila. Obstetrical Society.

(See Trans. Obstet. Society Phila. 1879 and Amer. Jour. Obstetrics Oct. 1879.) 3-7: 19-23 May 1 12: 766-770

1145.72- Hydrocephalic skeleton; foetal.
437
Presented by T. V. Rohon, Vienna
Vol II - Pg 517

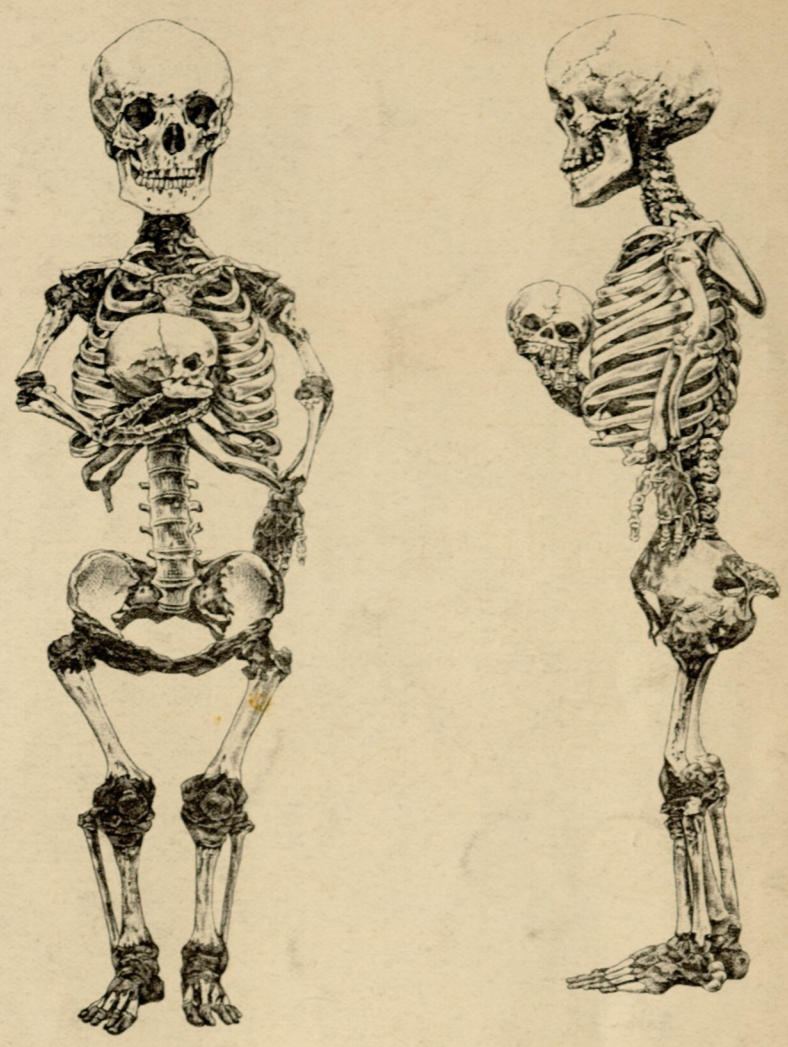

RACHITIC CESAREAN SECTION (WALSH)

481
685 a
1194.40
h,18
Dr.Cori

Obst. no 460
Shelf
Section. 19

4835

1150.10 Skull. Intra-uterine hydrocephalus.

The skull is of a foetus at full term. The bones of the face are normal, excepting foran accidental fracture of the inferior maxilla. The cranium is large, having a capacity of 1070 cc. The anterior fontanella measures 9x7 cm. The occipito-frontal diameter is 15.2 cm.; the biparietal, 12.5cm. and the bimalar 6.5 cm. The bones of the cranium excepting at its fontanelles are in apposition.

Mrs.S.J., third labor. Previous children healthy. After being in labor right hours, the body was born in breech presentation. The chin remained resting on the brim of the pelvis at the right acetabulum. Rotation was performed bringing the occiput to the acetabulum position. The long forceps were applied, but the head was discovered to be enormous. Efforts at compression were made. Amputation at the neck was resorted to. An opening was made through the soft parts under the chin and through the basilar process of the occipital bone into the cavity of the cranium. A considerable portion of the contents was them removed and by compression by means of the forceps, the cranium collapsed and moderate traction delivered thehead. The mother recovered.

H: 465-464

See Trans.Coll.Physicians Sept.4th, 1861.
Presented by Dr.Corse.

685 a
= 1194.40

Shelf 2
Section 19

485

1150.15- Skull. Intra-uterine hydrocephalus.
461

The skull is of a foetus at full term. The bones of the face are normal. The cranium, distended and dried, is enormous, having a capacity of 1310 cc. The occipito-frontal diameter is 16.2 cm. (6.5 in.); the biparietal, 14.5 cm. (5.75 in.); the bimalar, 7 cm. (3.75 in.). The cranial bones are separated from each other by broad bands of membrane thereby increasing greatly the cranial capacity. The fontanelles are very large. The two lateral halves of the fontal bones and the parietal and occipital bones are large and show well the radiation from the centres of ossification.

The head was perforated previous to delivery.

Presented by Dr. Corse.

1150.50- Encephalocele.
462
Shelf 2
Section 19

Presented by Dr. DeF. Willard.

1151.01- Skull. Gunshot fracture of the skull.
463
Shelf 3
Section 19

The cranium was perforated by a conoidal ball which entered at the anterior inferior angle of the left temporal bone carrying away a small fragment of the frontal bone and fracturing it howizontally in the line of the superciliary ridge, passing 1.5 cm. above the fronto-nasal

6852
1194.40

685 a
1194.40

Fig. 186.

A young skull with a number of depressions over its surface.—From a specimen in the Museum of the College of Physicians.

1150.15

junction, thence to the right orbital plate of the frontal bone, comminuting it. The ball traversed the brain and emerged at a point slightly lower and more anterior than the point of entrance, carrying away portions of the frontal, parietal, temporal and sphenoid. A small fissure is seen in the squamous portion of the temporal bone, also in the frontal close to the external ~~auglar~~ angular process.

The dimensions of the opening of entrance are 3 x 2 cm.; of the place of exit 3.75 x 3 cm.

The left supra orbital foramen is 8 mm. from margin of the orbit.

From a soldier killed in the battle of the "Wilderness."

Presented.

1151.02
464
Shelf B
Section 19

Calvarium. Depressed fracture of the frontal bone. Vertical fracture of the right parietal.

On the right fontal bone near its lower margin, there is a depressed area 3 cm. in diameter and 3 mm. indepth. At the margin of this area there are three concentric oval fracture lines not accompanied by any great displacement of the bone.

Viewed internally, the inner table is seen to be depressed and fractured near the falx;

6852
1194.40

three-fourths,however, of the depressed plate has yielded without fracture,being everywhere smooth. The depressed area of the internal table is 3 x 4 cm.

The fracture is recent and was undoubtedly made by direct violence.

The right parietal was fractured vertically. The inter-parietal suture is closed.

Purchased.

1151.03-465 Shelf 3 Sect. 19 Skull. Fracture of the base "by contre coup."

In this instance an area of the left frontal bone,colored red represents the place at which the blow was first received;no fracture is however, visible at this situation. The occipital bone is seen to be fractured into three fragments. The lines of fracture diverge from a point immediately below the superior curved line,2 cm. to the right of the insertion of the ligamentum nuchae;from this point one line passes upward to the superior angle of the bone; another,obliquely,toward the left mastoid process;the third, nearly to the right styloid process.

The sutures are closed.

Purchased.

685 a
1194.40

1151.04- Skull without calvarium. Fracture of the
466 right temporal and parietal bones. Recent.
Shelf 3
Sect. 19 The line of fracturepasses from the anterior border of the squamous portion of the right temporal bone horizontally backward through the posterior portion of the right parietal to the occipital bone near its superior angle. The sutures are not closed, The superciliary ridge is unusually prominent.

Presented by Dr. Mütter.

1151.05 Skull. Extensive fracture of the vault and
467 base of the skull. Union.
Sect 3
Sect. 19 Beginning at a point in the right parietal immediately above the superior border of the temporal bone the line of fracture extended horizontally backwards above the parieto-occipital suture near the lower border of the left parietal toward the mastoid process. At the beginning of this line there is an opening in the skull 4 x 7 mm.; the remainder of this fracture was united.

Another line of fracture probably passed from the anterior condyloid foramen through the jugular process of the occipital bone, traversed the posterior condyloid foramen and upward to the superior angle of the occipital; near the foramen magnum this line has not closed.

685 a
= 1194.40

The sutures are almost completely ossified; the orbital plates of the left frontal bone and the left parietal over the middle meningeal artery are extremely thin. On the left side the anterior condyloid foramen is double; the posterior condyloid, is wanting.

Presented by Dr. Mütter.

H
Wist. 05-
H68
Shelf 3
Set 19

Lower half of skull. Fracture of the base. Basant.

The fracture is extensive, passing from the right temporal bone through the sella turcica to the left temporal. The squamous portion of the right temporal is lost and the auditory canal exposed. On the right side, the greater wing of the sphenoid is fractured near its extremity and the orbital plate; the lesser wing is separated from the frontal and fractured through the median line. The body of the sphenoid is fractured transversely in the posterior portion of the sella turcica; the edges across the fracture passes just anterior to the left auditory canal and through the squamous portion of the upper border of the temporal bone.

Purchased.

Wist. 7- Cast taken of the fracture.

The sutures are almost completely ossified; the orbital plates of the left frontal bone and the left parietal over the middle meningeal artery are extremely thin. On the left side the anterior condyloid foramen is double; the posterior condyloid, is wanting.

Presented by Dr. Mütter.

1151.06- 468 Shelf 3 Sect 19.

Lower half of skull. Fracture of the base. Recent.

The fracture is extensive, passing from the right temporal bone through the sella turcica to the left temporal. The squamous portion of the right temporal is lost and the auditory canal exposed. On the right side, the greater wing of the sphenoid is fractured near its extremity and in the orbital plate; the lesser wing is separated from the frontal and fractured through the median line. The body of the sphenoid is fractured transversely in the posterior portion of the sella turcica; thence the fracture passes just anterior to the left auditory canal and through the squamous portion to the upper border of the temporal bone.

Purchased.

1151.07- 469 Sect 18 Shelf 3

Calvarium. Old fracture.

There are three openings at the seat of

fracture;one,near the median line in the right parietal,extends downwards 4.5cm. near the parieto-occipital suture and parallel with it; the second is in the inter-parietal suture and is 2 cm. long;the third which had a length of 7 cm.,lies in the left parietal near the median line and is united in the posterior portion throughout 2cm. These openings have a diameter of from 4 to 7 mm.,and have smooth edges. In the posterior portion of the inter-parietal suture is a Wormian bone having a diameter of 3 cm.

Presented by Dr.Mütter.

1151.08- Portion of the occipital bone. Old fracture in the left inferior curved line.

This would appear to have been inflicted by some cutting instrument. An opening 1.7 x 1.cm. remains,having sharp edges. Below it,the portion of bone detached seems to be united to the body of the bone forming a prominence.

Presented by Dr.Mütter.

1151.09- Calvarium. Fracture of left frontal and both parietals. Recent.

This fracture was evidently made by a saw. There is an opening 13 cm.long,of an irregular shape situated in the left frontal and parietal bones. It is ragged and,in places,has a

diameter of 1 cm. The cut in the right parietal is near the middle of the inter-parietal suture and is 4cm.long. The bones are thin.

Presented by Dr.Mütter.

1151.10
472
Sect 18
Shelf 3

Anterior half of calvarium. Punctured fracture at three points with depression of the internal table. One fracture occurred at the frontal protuberance;the second,4cm. distant,just within the temporal ridge;and the third near the anterior inferior angle of the left parietal 4 cm. from the sutures;these punctured openings are 5 to 7 cm.in diameter. On the external surface these openings are as clean as though made by a sharp cutting punch. No fissures radiate from them. Small rough fragments of the internal table project inwards from the margin of the holes at which they maintain their connection with the sound bone. One of these is a centimeter long,is connected with the fracture of the frontal protuberance.

Case of R.C.,aged 16,a factory hand who fell upon a large wheel covered with spikes of polished iron,9 cm.long,sharp at the points and 6 mm.thick at the base. It was practically a revolving comb for disentangling hemp. The boy fell upon it,became impaled by the hooks.

685 a
1194.40

It required two men to release him. When drawn off the hooks the boy was perfectly conscious; did not think he was much hurt and wished to walk home. He was admitted to the Episcopal Hospital, Philadelphia. Eight or ten large lacerated wounds of the back of the right hand and arm and a fracture of the left malar bone were also found.

There were no brain symptoms whatever at the time of admission. The lacerations were reflected and secured by sutures and water dressings applied to the head and face. The boy did well till the third day when there were intervals of delirium. On the fifth day, hemiplegia of the right side occurred. On the sixth day, difficulty in separating the jaws, especially on the left side; trismus; risus sardonicus; hard abdominal muscles; rectum and bladder. Setamus continued till the tenth day when the boy died unconscious.

Look on notes.

Besides the injury to the bones, the brain and its membranes were found lacerated at points corresponding to the fracture. The right anterior cerebral lobe was the seat of a large abscess and this lobe was more lacerated than the middle one. There was no particular congestion of the base and medulla. The spinal cord, not examined. Abscess about the left knee-joint. The wounds in the arm appeared to be

in good condition.

Trans.Coll.Phys.Phila.Vol.111,New Series,p.466.

Presented by Dr.Wm.Hunt.

1151.11-
473
Shelf 3
Sect 18

Calvarium. Depressed fracture of the left parietal bone.

There is a depressed fracture 5.5cm.long in the left parietal parallel to the inter-parietal suture and 6 cm. from it and 2 cm. distant from the parieto-frontal. The fracture was probably made by a single blow of a sharp instrument;two fragments are depressed 8 cm. from the outer surface;the upper fragment has a breadth of 1 cm.,the lower fragment,6 cm. The upper fragment is slightly longer than the lower.

From within,fragments of the internal table of slightly larger size are seen. They each have a breadth of 1cm.,and a length of 5cm. They are depressed so as to form an angle of 90° with each other. The fractured edges are separated by an interval of about 4cm. through which the diplöe is seen,but owing to the contact of the fragments of the outer table,there is no opening through the skull. The depressed portions of the internal table maintain their connection with the sound bone.

Presented by Dr.Mütter.

6852
1194.40

505

6852

1194.40

1181.12

474

Shelf 3

Section 14

Calvarium. Fracture of both parietal bones with separation of the sutures.

The right parietal has sustained a depressed fracture. The fracture lines radiate from the parieto-frontal suture near the anterior inferior angle of the bone. The longest fissure has a length of 7cm. The internal table is depressed and its fracture lines are more distinctly seen and are slightly more extensive. There is a fissure in the left parietal near the superior squamous angle, directed backward and downwards.

The frontal suture is persistent. It and the inter-parietal and fronto-parietal sutures are separated; the bones were not intimately locked together by them.

Presented by Dr. Mercier.

1183.1

474

Shelf 17

Section 3

Calvarium. Fracture of the left parietal near the middle of the inter-parietal suture. Recent.

The fracture was of small extent and slightly depressed. A trephine was applied immediately below the seat of injury removing a circle of bone 1.5cm. in diameter and some small fragments from the wall. Note of the outer bony lamina of the upper table was removed. The edges are sharp and the partial fissures have been [illegible].

Presented by Dr. M[illegible]

1151.12-
474
Shelf 3
Section 18

Calvarium. Fracture of both parietal bones with separation of the sutures.

The right parietal has sustained a depressed fracture. The fracture lines radiate from the parieto-frontal suture near the anterior inferior angle of the bone. The longest fissure has a length of 7cm. The internal table is depressed and its fracture lines are more distinctly seen and are slightly more extensive. There is a fissure in the left parietal near the anterior superior angle, directed backward and downwards.

The frontal suture is persistent. It and the inter-parietal and fronto-parietal sutures are separated; the bones were not intimately locked together by them.

Presented by Dr. Mütter.

1151.13-
475
Sect. 19
Shelf 3

Calvarium. Fracture of the left parietal near the middle of the inter-parietal suture. Recent.

The fracture was of small extent and probably depressed. A trephine was applied immediately below the seat of injury removing a circle of bone 1.8cm. in diameter and some small fragments from the skull. More of the outer table than of the inner table was removed. The edges are rough and the patient did not live long after the accident.

Presented by Dr. Mütter.

1151.14
476
Sect 19
Shel 3

Calvarium. Depression in the right parietal without fracture. (Classed for convenience among fractures.)

The cranium was extremely thin. In the temporal region the thickness is .5 mm. and in the occipital, 4 mm. In the posterior portion of the right parietal, there is a circular depression having a diamater of from 4 to 5 cm. and a depth of 7 cm. A corresponding depressed area is seen on the inner side. Evidence of fracture is seen. The calvarium is of adult size.

Presented by Dr. Mütter.

1151.15
477
Section 19
Shel 3

Calvarium. Depressed fracture of only the inner table of the frontal bone.

This is a rare specimen. The outer table of the cranium is smooth and no signs of fracture are seen. The inner surface of the frontal bone presents several fissures. One of these runs from near the inter-parietal suture downwards and backwards and near the middle of the left parieto-frontal suture the anterior portion of the inner table overlaps the posterior, or, in other words, is depressed 1.5 mm. This extends for 1.5 cm. Other small fissures are seen in the right frontal and in both parietals near the vertex. They do not follow any special direction.

The bone is extremely thin. The frontal has

6852
1194.40

a thickness of from .1 to.5cm. The occipital, .3 to.5 cm.

No instance of post mortem cracking and depression of the internal table being found in this collection, it is concluded without positive history that this specimen is an instance of fracture.

Presented by Dr.Mütter.

X

1151.16- Posterior portion of the right parietal.

478

Sect. 19

Shel. 3

Depressed fracture. Recent.

An oval space 4.5 x 2.5cm. is depressed. This space is marked on the outer side by two fracture lines and also by a smaller line running through the middle nearly parallel to the inter-parietal suture.

Viewed internally, the fracture is seen to be more greatly depressed than on the outer surface. A straight fracture line 4 cm. long and corresponding to the middle line in the outer table, is seen running at right angles to the course of the posterior branches of the middle meningeal artery. Above this line are two fragments separated by a fracture at a right angle to the first fracture. These fragments are depressed .5 cm. and are plainly seen to be much more depressed than the outer table. These are not detached fragments, but maintain continuity with the internal table.

Presented by Dr.Mütter.

685 a

= 1194.40

6852
= 1194.40

1151.17-
479
Sect. 19
Shelf 3

Calvarium. Fracture of the left parietal. Fragments detached from the inner table only. Recent.

At a point in the left parietal, 4 cm. from the inter-parietal and 5cm. from the fronto-parietal suture, there is a depression circular in shape, 1.5 cm. in diameter. The greater portion of this small area is smooth; its border is marked by numerous concentric rings, varying from .5 to 1. mm. from each other. The depression externally amounts to 2 mm.

Internally the internal table is detached over an area 2.5 cm. in diameter and the fragments are lost. The rough diploe is seen and through a fissure in it light may be seen coming through the unbroken centre of the outer table. The inner table is obliquely beveled at the border of the fracture.

The bones are thick and the sutures well ossified.

Presented by Dr. Mütter.

1151.18-
480
Sect 19
Shelf 3

Calvarium. Fracture of the right frontal. Old.

This fracture occurred near the fronto-parietal suture and ~~4 cm.~~ from 1 to 3 cm. from the median line. There is a depression due largely to absence of the outer table, 2 x 4 cm. in extent, having smooth borders and a central rough surface.

The inner table is seen to be slightly depressed and a T shaped opening in it is seen.

Presented by Dr.Mütter.

1151.19- IX
481
Sect 18
Shelf 3

Calvarium. Fracture of the right parietal above the temporal bone. Old.

The fracture was 10cm.long and ran parallel to the upper border of the parietal bone. .5cm. from it. A smotth ridge marked the fracture externally and from the inside a narrow ununited line can be seen. The internal table and diplöe are deeply corroded.

An old indian skull.

Presented by Dr.Mütter.

1151.20- X
482
Sect 18
Shelf 3

Calvarium. Fracture of the right parietal at the superior border. From a new-born child.

A small portion of the posterior superior angle has been detached and is attached to the dura mater; other fragments of the superior border have been lost. The dura mater is well seen. The frontal suture is ununited.

Presented by Dr.Mütter.

1151.21- X
483
Sect 18
Shelf 3

Skull. Fracture of the superior angle of the occipital bone with fracture of both temporal bones in horizontal lines separating the squamous from the mastoid portions and

passing through the auditory canals.

A circular fragment 3 cm. in diameter has been detached from the superior angle of the occipital bone. Two symmetrical fractures of the temporal bones continue from a diastasis of the ~~lambroidal~~ lambdoidal suture. The fractures in both instances pass from the most posterior portions of the temporal bones, at the posterior inferior angle of the parietals, downward and forward, traversing the roof and floor of the external auditory canals, terminating at the glenoid fossa. The line of fracture passes across the body of the sphenoid bone. Excepting the frontal, the sutures of the skull are not ossified.

Purchased.

1165- 529 Section 18 Shelf 5 Skull. Large wormian bone. Pg. 575

The skull is from a young person. The sutures are not ossified. In the right occipital there is a large Wormian bone 5 cm. in diameter. The occipital bone is prominent on the right side. The centres of ossification of the parietals are also prominent. One wisdom tooth has not descended.

Purchased.

1151.23- 484 Sect 18 Shelf 3 Skull. Extensive fracture of the vertex

Often the result of an old Indian tomahawk

685 a
= 1194.40

and base. Union. Large comminuted fragments removed forty years previously are attached to the specimen. Paramastoid process.

The skull shows an old fracture 12 cm. long in the line of the fronto-parietal suture, equally long on both sides of the median line. The fracture is bridged by bone in two places for the space of 1cm. The edges are smooth and separated from each other from 1 to 1.5 cm. Below two of the openings the dura mater is seen.

A united fracture of the base is seen extending from the left margin of the foramen magnum on the interior surface across the left side of the occipital bone and the petrous part of the temporal bone, obliterating the left carotid foramen. The left jugular fossa and the left lateral sinus are very much enlarged. When recently removed, a large cruciform cicatrix extended across the scalp in the direction of the inter-parietal and fronto-parietal sutures which, where the bone is deficient was adherent to the tissues beneath. In this deficiency was a firm membrane adherent to the dura mater. Very little evidence of abnormal condition was noted in the brain except that in each cerebral hemisphere there was a cavity or closed sac on the upper surface completely lined by a serous membrane and containing, the one in the right hemisphere,

6852
1194.40

about half an ounce, the one in the left, about two drachms of clear serum. The veins and sinuses were somewhat congested and the brain was rather harder than normal.

The fragments removed three months after the accident consist of portions of the parietal bones adjacent to the fronto-parietal and embrace 2 cm. of the inter-parietal suture. They are 7 cm. in their united length and have jagged edges.

Case of B.L., aged 16, admitted to the Pennsylvania Hospital Dec. 28th, 1824. The man was thrown from a heavy cart which overturned and caught his head between it and the pavement. There was a slight scalp wound on the back part of the head. His pupils became contracted; his pulse, slow; there was stupor but not stertor. There was effusion under the scalp near the front of the head and considerable hemorrhage from the left ear. His head being shaved and a close examination made no depression could be ascertained.

Dr. Parrish made a crucial incision over the top of the head. After removing clots a separation of the fronto-parietal suture of 6mm. was found. Free hemorrhage took place from the point where the suture crosses the track of the longitudinal sinus and the stupor was evidently relieved. "Several portions of matter, evidently medullary, were observed to

525

6852
1194.40

have escaped."

By the third day after free purgation and repeated bleedings, the pupils became natural and the discharge from the ear became purulent. The wound then granulated and on March 1st, 1825 portions of the parietal bones were removed as sequestra consisting of both tables of the bone. His vision was perfect with either eye alone, but on using both, had double vision.

June 1st, 1825 his health was completely restored, excepting loss of function of the left ear. Sight perfect.

Remaining in good health for five years, he then had epilepsy, which continued many years. Insanity supervened and continued till 1864 when he died in dementia.

This skull is remarkable for a right paramastoid process, a characteristic feature of the skulls of some of the lower animals, notably the pig.

See Trans. College of Physicians of Philadelphia, Nov. 6th, 1867. Vol. IV. New series. 219-222

Presented by Dr. J. C. Morris.

1151.24-
485
Sect 18
Shelf 3

Frontal bone. Gunshort fracture. Recent.

In the right frontal eminence, there is a circular opening 1.3 cm. in diameter when measured on the interior, 2cm. in diameter exter-

685 a
1194.40

iorly. Three short fissures radiate from this opening. The internal opening is well defined.

Presented by Dr.W.S.Halsey.

1151.27- 486 Section 18 Shelf 2

Portion of the anterior part of the skull. Fracture of the frontal and ethmoid bones.

The nasal eminence has been fractured in a transverse line at the level of the supra-orbital foramina. The nasal bones were driven inward with the fragment of the frontal and have fractured the cribriform plate of the ethmoid with depression. The line of fracture of the nasal eminence is straight and as though made by a cutting instrument.

Purchased.

1151.28- 487 Section 18 Shelf 3

The right temporal bone with portions of the sphenoid, parietal and occipital bones. Fracture of the petrous and squamous portions of the temporal. Recent.

The line of fracture may be traced running from the upper and posterior border of the squamous portion obliquely anterior to the auditory canal, though entering it at its deepest portion. The fracture then is seen to traverse the petrous portion, passing through the internal auditory canal, thus separating the petrous portion as a separate fragment.

6852
= 1194.40

Another line of fracture is seen to traverse the greater wing of the sphenoid from a point just internal to the spinous foramen, thence through the foramen ovale, to the inner side of the foramen rotundum and through the sinuses of the body of the sphenoid.

Purchased.

1151.29- 488 Section 18 Shelf 3

Portions of the frontal, ethmoid, vomer and nasal bones. Depressed fracture. Recent.

The frontal bone below the frontal eminences, including the orbital plates, the ethmoid, vomer and nasal bones are crushed in.

Presented by Dr. Mütter.

1151.30- 489 Section 19 Shelf 4

Portions of the right temporal, sphenoid and inferior maxillary bones. Fracture of the squamous portion and base of the zygomatic process. Recent.

The line of fracture may be traced from the anterior and upper border of the temporal bone obliquely backwards and downwards across the base of the zygomatic process and the glenoid cavity to the carotid canal.

Purchased.

1151.32- 490 Section 19 Shelf 4

Skull. Old depressed fracture of the left parietal bone.

685 a
1194.40

There is a depressed area in the left parietal near the median line measuring 4 x 4 cm. and having a depth of 8 mm. The borders are smooth, although the depression is abrupt. Removal of the calvarium shows thickening of the bone and a corresponding depression of the inner table over an area of 5cm. in diameter. The bone is smooth and marked by a groove for one of the anterior branches of the middle meningeal artery. The thickness of the skull is in many places 8 mm. and over the seat of injury, 10 mm. The dura mater is depressed in this location and has been preserved, showing well the teutorium and falx.

Presented by Dr. W. S. Halsey.

1151.33-
491
Section 19
Shelf 4

Calvaria. Stellate fracture of the occipital region. Recent.

This fracture can be best seen from the inner side. The centre of radiation is in the left parietal bone at its posterior superior angle. One long fissure skirts the posterior border; another passes at once into the occipital and quickly is lost in the right lambdoid suture.

From a member of a hose company 23 years of age, who fell fifty-five feet and died unconscious four hours afterward, July 4th, 1854. The dura mater was ruptured and effused blood was found under the calvarium.

Purchased.

685 a
= 1194.40

1151.34- Calvaria. Fracture of the frontal bone, compound comminuted and depressed.

The injury was from a sling-shot received on the left frontal eminence. The frontal bone was crushed in; the fracture involved the orbital plates and frontal sinuses on both sides. A detached fragment 4 cm. long lies between the frontal eminences and from the median line a line of fracture extends backward deviating slightly to the right. The bone was trephined immediately above the left frontal eminence.

From a man wounded by a sling-shot. Besides the fracture, the meninges and sub-jacent anterior lobe of the cerebrum were lacerated. The man was unconscious and, although the bone was trephined and the fragments elevated, remained in that condition until his death which took place on the fourth day.

Purchased.

1151.35- Calvaria. Fracture of the right parietal; compound, comminuted and depressed.

The injury was from a sling-shot received immediately above the temporal bone. There are no radiating fissures, but there is depression of a portion of the parietal immediately over the temporal bone. The depressed area is greater in the upper part than in

r37

685 a
= 1194.40

1151.34- Calvaria. Fracture of the frontal bone, compound comminuted and depressed.

492
Section 19
Shelf 4

The injury was from a slung-shot received on the left frontal eminence. The frontal bone was crushed in; the fracture involved the orbital plates and frontal sinuses on both sides. A detached fragment 4 cm. long lies between the frontal eminences and from the median line a line of fracture extends backward deviating slightly to the right. The bone was trephined immediately above the left frontal eminence.

From a man wounded by a slung-shot. Besides the fracture, the meninges and sub-jacent anterior lobe of the cerebrum were lacerated. The man was unconscious and, although the bone was trephined and the fragments elevated, remained in that condition until his death which took place on the fourth day.

Purchased.

1151.35- Calvaria. Fracture of the right parietal; compound, comminuted and depressed.

493
Sect 19
Shel 4

The injury was from a slung-shot received immediately above the temporal bone. There are no radiating fissures, but there is depression of a portion of the parietal immediately over the temporal bone. The depressed area is greater in the inner table than in

outer table. Trephining was performed immediately above the fracture. The frontal suture is persistent.

The man was injured by a slung-shot fracturing the skull and lacerating the brain and its meninges. There were symptoms of compression; death occurred in two days.

Purchased.

1151.36- Calvaria. Fracture of the occipital bone from a sabre blow. Healed.

494
Sect 18
Shelf 4

The sabre in descending vertically on the skull caused an opening 5.5cm. from side to side and about 1.5 cm. in vertical extent. The fracture has been partially repaired by a deposit of bone in the middle line as a band 1.5 cm. broad. The edges are smooth and further repair was evidently not going on. The frontal suture is persistent.

There is a small fragment from inner table lying partially attached at the edges of the opening.

From a Russian soldier wounded at the Battle of Inkerman. The man apparently suffered no inconvenience from loss of brain matter and bone following his accident. A membrane covered the openings in the bone. The man died of cholera while a prisoner in the British hospital at Skutari ten months

6852
= 1194.40

after the accident.

Purchased,

1151.37- Calvaria. Transverse fracture of the vault.

495
Sect 18
Shf 4

The fracture may be traced from the squamous portion of the left temporal through the parietals, crossing the sagittal suture close to the occipital bone into which the fracture passes behind the temporal bone. The skull is very thin.

From a young man who fell on the sidewalk. There was no external wound. Symptoms of compression occurred without reaction and death occurred twelve hours after the accident. In addition to the course of the fracture as described, the fracture was found to pass as far as the left external auditory meatus. A clot of blood displaced the dura mater under the parietal bones.

Purchased.

1151.38- Calvaria. Fracture of the occipital bone; depression of the fragments.

496
Sect 18
Shf 4

The fractured area is 2.4 cm. square in the occipital bone bordering on the right occipito-parietal suture. The fracture was obviously caused by a direct blow; the internal plate of the fragments is larger than the external. An upper fragment remains attached

685 a
= 1194.40

by the internal table,

Dissecting room specimen.

Purchased.

1151.39- Calvaria. Doubtful fracture of the left parietal bone;healed.

497
Sect 18
Shf 4

Near the inferior posterior angle of the left parietal bone a depression with smooth surface is seen in the external surface. Internally a sharp prominence is seen projecting inward about .5cm. The prominence is sharp but the internal table is generally smooth. Section of the bone in this region shows induration of the spongy tissue and obliteration of the diploë at this point.

From Edward Parr,a murderer,who was defended on the ground of insanity produced by what was claimed to be an old fracture of the skull, various opinions were given by surgeons at the trial, After conviction,the man committed suicide by swallowing poison in court;Philadelphia,June,1879. Phila. June 1879

Presented by Dr.John H.Packard at Dr.Chapman's request.

1151.40- Skull. Fracture of the right temporal and both parietal bones.

498
Sect 18
Shf 4

The fracture may be traced from the base of the zygoma of the right parietal bone ob-

liquely upward and backward through the right parietal to the angle of the occipital bone and thence transversely about 3cm.in the left parietal. There was no depression. The skull is thin.

From a man who fell in running to the fire of the Orphan Asylum in 1822 and was admitted to the Philadelphia Hospital. There was a slight cut 3 cm. from the posterior end of the sagittal suture. The fracture was discovered post mortem.

Presented by Dr.I.T.Sharpless.

1151.41- Plaster cast of cicatrix years after a perforating gunshot fracture of the skull.

Section 260
Shelf 2

Private Patrick Hughes,4th N.Y.V.,aged 23,wounded in the battle of Antietam September 17th,1862. Skull perforated by a conoidal musket ball,which,according to a report made eight days later,entered half an inch posterior to the junction of the coronal and sagittal sutures on the median line,passed backward under the scalp and escaped one inch above the occipital protuberance inflicting a wound four inches in length,producing a compound comminuted fracture of the skull of the same extent. At the time of his admission to the Mt.Pleasant Hospital, eight days after the wound,so much tumefac-

5-45

685 a
F 1194.40

tion existed that it could not be ascertained whether or not the brain or its membranes were injured. The field report, however, states that the ball traversed a portion of the brain, that the man dragged himself from the field, that he was conscious and answered questions rationally but that shock and depression were great.

In December 1862, the patient sat up and walked about the ward.

Patient alive twenty years later.

See Med.&Surg.History War of Rebellion Surg.Vol.1 p.206. Flints Physiology, Vol.V art.optic nerve.
W.W.Keen - Photographic Review 1:26, 1871

Presented by Dr.W.W.Keen.

1151.42- Skull; extensive fracture; from a case of murder.
499
Shelf 18
Shelf 4

The entire right side of the skull is crushed. Portions of the right parietal, frontal, temporal, occipital, and sphenoid bones are missing, having been shattered by the blow. An oval opening is also seen in the left occipital region as though caused by a second stroke.

The extreme force of the blow was also expended on the left side of the cranium and face. A long fissure is seen in the left frontal region passing vertically through the orbit, to the outer side of the supra-orbital,

1151.45 Skull - Extensive fracture Presented by Dr. John H. Brinton

1151.46 Calvarium - fracture of left parietal " " " " "

1151.47 Calvarium - fracture of right parietal and occiput Presented by Dr. John H. Brinton

1151.48 Calvarium fracture of right parietal " " " " "

1151.49 Calvarium Depression of outer and inner table of left parietal. Presented by Dr. John H. Brinton

1151.50 Portion of calvarium — fracture — force unknown — Died in 24 hours. Presented by Dr. John H. Brinton

1151.51 Fracture of the skull

and to the inner side of the infra-orbital foramen, thence to the alveolar border of the superior maxillary bone between the second bicuspid and first molar tooth. Another fissure is seen passing horizontally through the squamous portion of the left temporal bone.

Case of Ellen Jones who was murdered near Media, Delaware County, Pennsylvania in 1863. The woman was struck while asleep, by an axe in the hands of Wilkinson who dealt a crushing blow with the pole of an axe.

Presented by Dr. J. Ewing Mears.

1151.43- Skull; artificial fracture of the base.
500
Section 18
Shelf 4

The occipital bone is fractured at the apex. The sphenoid and temporal bones are missing. The skull has evidently once been perfect, for holes have been drilled in the parietal bones to support an inferior maxilla, which is not present.

Presented by Dr. J. Ewing Mears.

1151.44 Skull. Gunshot injury see Vol I Page 445

1152- Calvarium. Hypertrophy.
561
Sect. 19
Shelf 4

The specimen is very thick and heavy. The parietal bones are one centimeter thick; the occipital bone in the median line is two centimeters thick. The sutures are all ossified. Both surfaces of the bone are smooth.

The relation of the cancellous to the compact tissue does not seem to be altered.

From a man aged 42, who died of obscure cerebral trouble. He received a blow on the lateral superior and left aspect of his skull when twenty-one years of age. The size of his head increased. Toward the last years of his life, he became alternately excited and dull. On examining the base of the skull, the foramen magnum appeared small. The brain was not compressed by the skull.

Purchased.

1155- Skull, Caries of the posterior clinoid process of the sphenoid.

502 Sect. 19 Shf. 4

This process is nearly detached by caries at its base. The sutures are not united and the frontal suture is persistent. The crista galli is well marked.

Presented by Dr. Mütter.

1155.01- Skull. Caries of the Posterior clinoid process of the sphenoid.

503 Sect. 19 Shf. 4

This process is nearly destroyed. The c cancellated tissue is exposed. The skull is thick; the middle meningeal arteries were nearly imbedded in the parietal bones; the septum of the nose deviates markedly to the left and there is a peculiar prominence of the occipi-

1155.05 Skull Caries. Presented by Prof. George McClellan
1155.06 " " " " " "
1155.07 missing " " " " " "
1155.08 missing " " " " " "
1155.09 Calvarium-Caries extensive. Presented by Dr. John H. Brinton.

~~1155.10 Calvarium from a case of Osteitis Deformans (Paget's Disease) Presented by Dr. F.R. Packard~~

~~1155.11 Calvarium from a case of Osteitis Deformans From the collection of the late Dr. F.R. Packard~~

tal bone. The supra-orbital ridges and zygomatic arches are ~~and~~ prominent.

Presented by Dr. Mütter.

1155.02- Right temporal bone. Caries.
504
Sect 19
Shf 4

At the junction of the petrous and squamous portions the cancellous tissue is exposed.

Presented by Dr. W.S. Halsey.

1155.03- Skull of a gorilla (Troglodytes gorilla).
505
Section 19
Shf 4

Caries.

The supra-orbital ridges are rough and their central portion and the roof of the frontal sinuses are carious. The sinuses are open. The orbital and occipital ridges are very high and prominent. The rami of the inferior maxilla are 7.7 cm. broad. The cranial capacity is 600 cc. Purchased by Dr. Joseph Leidy in London - June 15, 1876.

1155.04- Calvarium. Caries of the external
506
Sect 19
Shf 4

table.

Presented by Dr. J. Ewing Mears.

1156- Anterior half of the skull. Necrosis
507
Sect 19
Shf 4

from malignant disease.

There is on the left side a large opening 10 cm. in its greatest diameter at which portions of the frontal, sphenoid, and superior maxillary have been destroyed. The left front-

685 a
= 1194.40

5-5-3

al sinus and antrum of Highmore are exposed. The edges are rough and the inner table next to the opening is carious. The posterior clinoid process is rough and irregular.

Purchased.

1156.10- Temporal bone, showing extensive destruction from malignant disease, originating in the mastoid cells.

508 Sect 18 Shf 4

Ashhurst Trans. Phila. Pathological Society, Vol. IV - 31-34 Ap. 10 1873

and Philadelphia Medical Times, August 27th, 1881. G.C. Harlan, II: 750,

Presented by Dr. Geo. C. Harlan.

1156.20- Temperal bone, showing necrosis of the roof of the tympanum and of the mastoid antrum. Death from abscess of the cerebrum induced by chronic purulent otitis media.

509 Sect 18 Shf 4

Phila. Med. Times, August 27th, 1881. II: 751 G.C. Harlan.

Presented by Dr. Geo. C. Harlan.

1157- Calvarium. Exostosis of the inner table of the frontal bone.

510 Sect 18 Shf 4

At points in the anterior portion of the inner table of the frontal on either side of the median line 1.5 cm. from it are small exostoses. The left one is the larger, having a diameter of .8cm. and a thickness of .3cm.

685 a = 1194.40

Their surfaces are smooth. The skull was not thick.

Presented by Dr.Mütter.

1157.01- Calvarium. Exostosis of the inner table. General hyperostosis.

511
Sect 18
Shf 4

The anterior portion of the inner table especially on the right side is covered with broad based exostoses,not projecting to a great extent,but considerably augmenting the thickness of the skull. The line of the longitudinal sinus is also roughened. The skull was long and narrow.

Presented by Dr.Mütter.

1157.02- Fragment of right parietal. Exostosis of the inner table. more accurately, calcareous Pacchionian Bodies

512
Sect 18
Shf 4

The exostosis is 2 x 3 cm. in extent and .5cm. thick. It is situated on the inner surface of anterior inferior angle of the right parietal. Its surface is rough and its outline rather irregular. As many as forty other exostoses (see next specimen),all of them small grew from the various cranial bones on the arch and sides,but not on the base,while the sides of the longitudinal sinus were plated by long,flat, irregular masses of bone which passed .5 cm. downward into the great fissure below the sinus,growing from the dura mater.

At the time the specimen was removed, the membranes at the upper and anterior portion of the skull were intensely inflamed, the basal membranes, to a slighter extent.

Case of M.C., aged 21, Had a history of severe headache, double vision; occasional squint ten days before death; unendurable sense of vertical pressure on the head. Movement of the eyes painful. Two days previous to death had a slight spasm, was slightly unconscious, finally comatose.

Presented by Dr. S. Weir Mitchell.

1157.03- Dura mater and exostoses near the longitudinal fissure.

See preceding specimen.

Presented by Dr. S. Weir Mitchell.

1157.04- Sphenoid. Hypertrophied ~~ostitis~~ Ostitis. Vol. 1- Pg. 14

The right lesser wing is enlarged to five times the thickness of its fellow. Its surface is rough and carious anteriorly. The optic foramen is narrowed upon the right side and grooves are seen between it and the left foramen. The pituitary fossa is narrow; the posterior clinoid process is rough and fenestrated and its left angle is adjacent to the left anterior clinoid process.

Presented by Dr. Mütter.

515 Shelf 4 Section 19 1157.04(A)

(A) Rt. temporal bone, necrosis external auditory canal. (no old no)

Lt. temporal bone, necrosis ~~outer~~ auditory canal.

(B) 516 Section 19 = Not old no

Shf 4

1157.04 (B)

1157.06 of Hyperostosis See 22nd Annual Report - Transactions of the American Neurological Society. Pg 207

1157.06 is evidently the case mentioned by Dr. Hinsdale in the 22nd annual report of the American Neurological Society, 1896. Page 207 of the Transactions. Woman aged 64 afflicted with rheumatism & enlargement of the head began. Presented to Museum by Dr. Herwirsch. E.H.W.

1157.06 - Calvarium from a case of Osteitis Deformans (Paget's Disease)
Presented by ~~Dr. F. R. Packard~~.

1157.07 Calvarium from a case of Osteitis Deformans,
From the collection of the late Dr. F. R. Packard.
See Vol 1. Pg 14

(~~Cancellous~~)

1157.05- Right temporal bone. Exostosis of the external auditory canal.

2956 Sec 18 Shelf 5

The bone is large and strong. There is an exostosis 10 x 7 mm. attached to the posterior portion of the external auditory canal almost entirely filling the opening.

R2 number 516-1

Presented by Dr. Mütter.

1157.09 See next page

1161- Skull. Syphilitic caries.

517 Sect. 18 Shf. 4

The cranium is deeply involved in tertiary syphilis. In the frontal bone are four areas of disease symmetrically distributed. One cavity on the right frontal, 3 x 2 cm. nearly perforates the skull. Its surface is rough and abounds in fine radiating fissures. At the anterior inferior angle of the left parietal, there is a circular opening 1 cm. in diameter, having beveled edges, comparatively smooth in the external aspect becoming thin and sharp. The parietals present the largest areas of disease. For a distance of 7 cm. in the inter-parietal line and for from 4 to 6 cm. on either side the wall is thinned and in the middle is perforated. The irregularity of the surface is greatest in the middle line. The surface is smooth and the disease apparently quiescent. The obtuse angle of the jaw would indicate old age.

Presented by Dr. Mütter.

1157.09 Plaster cast of a case of Osteitis Deformans or Paget's disease. 561

Calvarium of Henrietta N. aet. 58 years, a negress, dying in the Philadelphia General Hospital from meningitis. The disease is said to have begun 14 months before death with swelling of the head, most marked over the ears in mid-temporal region. The swelling was confirmed by x-ray at the above hospital. She became irresponsible mentally, developed headache, and the legs became thickened and bowed.

At autopsy the bone at the base of the skull was also found heavily thickened and in all parts soft and spongy, cutting almost like wood. The cranium measured 67.5 cm. in greatest circumference, and 3.6 cm in greatest thickness which was just about the right supra-orbital ridge. Chemical analysis showed 34.598 % of organic matter, which is that of a two months old child (Wells). Autopsy by Dr. D. M. Dry, the cast executed by Dr. Fred Weidman, the chemical analysis by Dr. Baldwin N. Lucke.

Presented by Dr. Fred D. Weidman 11/21/17.

685 a

= 1194.40

1161.03- Skull. Syphilitic caries.

519

Sep 19

The right frontal bone at and above the orbital ridges is the seat of superficial syphilitic caries. The external angular process has lost substance. There are fine vascular openings throughout the affected area which extend nearly to the frontal eminence. The same appearances are seen on the inner surface of the skull without actual loss of bone. The orbital plates are extremely thin and in many places perforated, indicating age. The frontal bone presents in its external surface numerous depressions. A large deep one is seen on the right side near the parietal bone. The left cerebral fossa of the occipital bone is larger than the right.

Presented by Dr. Matter.

685 a
F 1194.40

1161.01- Skull. Syphilitic caries.
518
Sect 19
Shf 5

The frontal and both parietal bones are eroded in an irregular, superficial manner. The surface of the frontal is quite generally involved, particularly so in the supra-orbital ridges and between them. The ridges are thickened and vascular. The parietals show ill-defined patches of superficial roughness and absorption. The cranial sutures are ossified.

Presented by Dr. Mütter.

1161.02- Skull. Syphilitic caries.
519
Sect 19
Shf 5

The right frontal bone at and above the orbital ridges is the seat of superficial syphilitic caries. The external angular process has lost substance. There are fine vascular openings throughout the affected area which extend nearly to the frontal eminence. The same appearances are seen on the inner surface of the skull without actual loss of bone. The orbital plates are extremely thin and in many places perforated, indicating age. The frontal bone presents in its external surface numerous depressions. A large deep one is seen on the right side near the parietal bone. The left cerebral fossa of the occipital bone is larger than the right.

Presented by Dr. Mütter.

565

1161.03-
520
Set 19
Ref 5

Skull. Syphilitic caries of the entire vault.

The disease involves every bone of the cranium. The sides of the skull, more than the vertex are rough, finely eroded over a larger portion of the area and at the same time the seat of inflammatory hypertrophy. The left temporal bone is deeply involved in caries both on the internal and external surface. The petrous portion is destroyed to such an extent as probably have seriously affected hearing. The posterior clinoid process is rough and long. The turbinated bones are broken, but the nasal bones are not invo,ved. The orbital plates are thick. The left frontal sinus extends higher than the right.

Presented by Dr. Mütter.

1161.04-
~~(1166)~~
521
Set 19
Ref 5

Calvaria. Syphilitic necrosis with sequestra.

Over than half of the surface of the frontal and parietal bones are invaded. At the vertex there are large vacancies in the skull, having sharp irregular edges, which belong usually to the inner table. Large excavations of the outer table are seen in places where the inner table is not perforated. Two sequestra are attached to the specimen. One is

685 a
F 1194.40

685 a
F 1194.40

1161.03- Skull. Syphilitic caries of the entire vault.

520
Sect 19
Shf 5

The disease involves every bone of the cranium. The sides of the skull, more than the vertex are rough, finely eroded over a larger portion of the area and at the same time the seat of inflammatory hypertrophy. The left temporal bone is deeply involved in caries both on the internal and external surface. The petrous portion is destroyed to such an extent as probably have seriously affected hearing. The posterior clinoid process is rough and long. The turbinated bones are broken, but the nasal bones are not invo,ved. The orbital plates are thick. The left frontal sinus extends higher than the right.

Presented by Dr. Mütter.

1161.04- ~~(1156)~~ Calvaria. Syphilitic necrosis with sequestra.

521
Sect 19
Shf 5

More than half of the surface of the frontal and parietal bones are invaded. At the vertex there are large vacancies in the skull, having sharp irregular edges, which be-,ong usually to the inner table. Large excavations of the outer table are seen in places where the inner table is not perforated. Two sequestra are attached to the specimen. One is

4 cm. long and consists of the outer table and diplöe. Its margines are irregular and rough. The outer is not quite so large and consists of both tables, In the calvarium a larger sequestrum is nearly detached, belonging to the right parietal bone.

The inner surface of the specimen is rough and lustreless, excepting near the occipitale bone and shows in places absorption of the inner table. Fluid doubtless separated the meninges from a large portion of the bony wall. No attempt at repair is apparent.

Presented by Dr. Mütter.

1161.05-
522
Sect. 19
Shf. 5

Calvaria. Syphilitic caries.

There are eight areas of syphilitic caries in this specimen. They are symmetrically placed. Four belong to the frontal bone. Two are at the supra-orbital rdiges and have a diameter of from two to three centimeters. The left one is a little nearer the parietal bone and perforates the skull. Immediately above these about 7 cm. distant are two more diseased areas. They are round, of the same size as the others and the right one perforates the skull. The outer areas are in the posterior portion of the specimen, involve chiefly the outer table and are not so large as those before mentioned. All the excavations have beveled margins and were in an active state when the specimen was

685 a
F 1194.40

secured. The fronto-parietal suture is well marked and the bones are separable;no traces of inter-parietal and occipito-parietal sutures are present. The skull was comparatively thick,long and narrow.

Presented by Dr.Mütter.

1161.06- Calvaria. Syphilitic caries.
523
Sect 19
Shf 5

The disease made deep in-roads in the frontal bone. A large area 6x 4 cm.is excavated and there is a vacancy in the skull wall. The edges are beveled down to the inner table which is sharp. All over the calvarium especially posteriorly,there are depressions and thin places. The surface is generally smooth and the disease was in a quiescent state. The inner surface is comparatively rough.

Presented by Dr.Mütter.

1161.07- Skull. Syphilitic necrosis.
524
Sect 18
Shf 5

The bones of the cranium,especially the frontal bone,ear and inferior maxilla on the left side,are deeply invaded. The frontal sinuses are opened. The diseased areas are symmetrically placed. The nasal bones are in a fair state of preservation. The vomer is partially destroyed. The alveolar processes are so involved that most of the teeth have

685 a
F 1194.40

been lost.

Dissecting room specimen. From a female, about 26 years of age.

Purchased.

1161.08- Calvaria. Syphilitic ostitis.

525

Seat 18

Shf

The outer table is irregular over the entire vault and is covered with fine vascular openings. There are no excavations. The color is white in the middle line. The inner table presents unusually large foramina. The sutures are ossified.

From a woman aged 28, who died in 1858 of dysentery coming on while she was suffering from tertiary syphilis.

Purchased.

1161.09- Calvaria. Syphilitic necrosis. Fatal.

526

Seat 18

Shf

The parietal bones, chiefly their inner table, are the seat of disease. A flat sequestrum has formed in both parietals near the longitudinal suture. These areas are near the posterior border of the bones. The surface is rough. The sequestra are almost ready to separate and the disease evidently active at the time of death. The outer table is destroyed over the left sequestrum.

From a woman, aged 30, who died of meningitis consequent to tertiary syphilis.

Purchased.

685 a
F 1194.40

1163 Skull, hydrocephalic

This skull has deteriorated to such an extent that it cannot be repaired. Is now on the work bench in laboratory. 11/27/39 - E.H.W.

Presented by Prof. George McClellan

No 529 - see old no 1165

Look several pages next to 1151.23.

1166 young negro
531
Sect. 19 Skull of adult showing extensive
Shf. 5 of syp. mentioning.

1163.20 - Hydrocephalic Skull

1161.10- Skull showing extensive syphilitic
527 caries.
Sect. 18
Shf. 5

Purchased of Tramond, Paris, 1889.

1161.11- Skull. Syphilitic caries.
528
Sect. 18
Shf. 5

Purchased.

1161.12 Skull. Syphilitic caries Presented by Prof. George McClellan

1164- Persistent frontal suture. See 1169.01

1165.00- see page 519.

1165.01- Skull. Large Wormian bone.
530
Sect. 19
Shf. 5

The skull is large and heavy. The Wormian bone is situated posterior to the occipital bone, is symmetrical and occupies a position between the parietals. It measures 5 cm. vertically and 13 cm. laterally.

Dissecting room specimen.

Purchased.

1167- Skull of a Digger Indian from Santa Bar-
532 bara Mission, California.
Sect. 19
Shf. 5

The skull shows a depression 1 cm. in diameter over the left frontal eminence; there is also an opening 2 cm. in diameter in the frontal bone immediately above the greater wing of the right side of the sphenoid. The orbital plates are thin and perforated. The angle of the jaw is very obtuse. Roots and dirt are seen at the base of the skull which has been probably long buried. Wesight 672 grammes.

Presented by Dr. Thos. M. Logan of San Francisco.

685 a
F 1194.40

685 a
F 1194.40

1167.10- Skull of a negro idiot, aged about 37 yrs.

533
Sect 19
Shf 4

The skull is thick and heavy; the sutures of the vertex are obliterated. The forehead retreats excessively and the jaws are very prognatious.

Dissecting room specimen.

Purchased.

1167.20- Skull of a lunatic; brachycephalic.

534
Sect 19
Shf 5

The skull is remarkably brachycephalic; the occipito-frontal diameter is 16.5cm. The distance from the condyles to the vertex is 17cm. The fronto-parietal and inter-parietal sutures are ossified. Several Wormian bones are seen in the occipito-parietal suture.

Purchased.

1167.30- Calvaria. Deep Pacchionian depressions.

535
Sect 19
Shf 5

The groove for the left middle meningeal artery is very deep and throughout its course and in the Pacchionian depressions the bone is translucent.

Dissecting room specimen.

Purchased.

1167.40- Portion of a skull from the Catacombs of Rome.

536
Sect 19
Shf 5

685 a
= 1194.40

This was found in the catacomb of St. Calestro at Rome, in 1866. It was in a tomb in the second stage or floor which is held to be most ancient. Many of the victims of the early persecutions of Christians were interred in that floor.

The bones of the face are well preserved; the front teeth are missing. Earth still remains in the cavities and sinuses.

Presented by Morris S. Wickersham.

✓1168-537
Sect 19
Shf 5

Skull. Partial obliteration of the left glenoid cavity due to anterior luxation of the inferior maxilla.

The left glenoid cavity is rough and partially filled with bone deposit. There is slight absorption of the articular eminence with roughness of its anterior border. The supra-orbital ridges are rough and prominent and abound in fine vascular openings.

Presented by Dr. Mütter.

581

685 a
F 1194.40

BONES OF THE FACE.

1169
to
1188 3

583

685 a

F 1194.40

595

685 a

F 1194.40

587

685 a

F 1194.40

589

685 a

= 1194.40

685 a
F 1194.40

1169-01
538
Sect 18
Shf 5

Skull of an idiot. Fracture of nasal bones. Union.

The nasal bones were fractured transversely at the middle and have united without deformity. There is a depression of the right zygoma.

The skull is ~~scapo~~-scaphocephalic.

From an idiot aet. 23 years.

W.S.F.

Purchased.

See page 593

lower than normal, owing to the fracture. Union did not occur between the fragments. The frontal suture is persistent.

Presented by Dr. Mütter.

1169.02-
539
Sect 18
Shf 5

Skull. Old fracture of the left malar, superior maxillary, and nasal bones.

The injury was apparently inflicted by a sharp instrument, cutting through the bone in a horizontal line, opening the antrum and cutting off 1cm. of the nasal bone. The bone has healed with a horizontal gap; the edges are quite smooth.

Presented by Dr. Mütter.

3-93

1169-565 Section 21 Shelf 3.

Right half of inferior maxilla, Deposit of tartar.

Presented by Dr.T.D.Mütter.

1169.01-538 Sect. 18 Shf. 5 See preceding page

Skull. Old fracture of the right malar, nasal and superior maxillary bones and orbital plate.

The malar bone was fractured at its junctions with the zygoma, the frontal and superior maxillary bones. The right nasal bone was fractured in the middle and united without deformity. The inferior plate of the right orbit is absent and communicates with the antrum. The inferior margin of the orbit is irregular, owing to a deficiency at this point in the superior maxillary. The frontal plate of the left orbit is almost entirely absent. The bridge of the nose is lower than normal, owing to the fracture. Union did not occur between the fragments. The frontal suture is persistent.

Presented by Dr.Mütter.

1169.02-539 Sect 18 Shf 5

Skull. Old fracture of the left malar, superior maxillary, and nasal bones.

The injury was apparently inflicted by a sharp instrument, cutting through the bone in a horizontal line, opening the antrum and cutting off 1cm. of the nasal bone. The bone has healed with a horizontal gap; the edges are quite smooth.

Presented by Dr.Mütter.

685 a
= 1194.40

1169.03 Skull. Old fracture of the nasal bone, the left malar and inferior maxillary.

540
Sect 18
Shf 5

The nasal bones were fractured at their inferior border; they are deflected to the right and have atrophied at the extremity. The zygoma was crushed inward, yielding at the malar junction. The inferior maxillary was fractured immediately posterior to the right mental foramen. Union took place in good position with slight irregularity of the inferior surface, owing to the action of the masseter. The skull is from an old subject.

Presented by Dr. Mütter.

1169.04 Skull. Old fracture of the nasal bones.

541
Sect 18
Shf 5

The bones were fractured transversely at their middle. Union has occurred with a slight deflection of the lower fragments to the left and with depression at the point of fracture.

Presented by Dr. Mütter.

1169.05 Skull. Old fracture of the nasal bones.

542
Sect 18
Shf 5

The bones were fractured transversely at the middle and also near the inferior border, forming from the two bones six fragments. Union has occurred in good position.

Presented by Dr. Mütter.

685 a
1194.40

685 a
= 1194.40

1169.06- Skull. Fracture of the nasal bones. Union.
543
Sect 18
Shf 5

The bones were fractured transversely at the middle and have united with a decided deflection to the left. The vomer is extremely displaced to the right. The middle and posterior clinoid processes on the left side are almost in contact.

Presented by Dr. Mütter.

1169.07- Old fracture of the nasal bones. Caries of the frontal bone.
544
Sect 19
Shf 6

The nasal bones were fractured transversely and have united in excellent position without deformity. There is caries of the right frontal eminence consequent upon an ulcer of the scalp. The compact tissue only is involved and is grooved in irregular lines.

Presented by Dr. Mütter.

1169.08-F13-Lower half of skull. Fracture of the left malar bone. Union.
545
Sect 19
Shf 6

The bone was fractured close to its junction with the superior maxillary. Union has occurred, incomplete inferiorly and marked by a spicule at the margin of the orbit, pointing toward the nose.

Purchased.

1169.09- Skull of an aged man. Old fracture of the nasal bones and left zygoma.
546
Sect 19
Shf 6

685 a
= 1194.40

The nasal bones were fractured at the middle and have united with decided depression of the nose. The nasal septum deviates strongly to the left. The left zygoma was fractured at the summit of the arch, but has united.

The marks of old age are characteristic. Absence of teeth in either jaw for years has been followed by absorption of the alveolar process. The mental foramina are close to the alveolar border. The ramii are at an obtuse angle with the body of the bone. The orbital plates are thin. The subject was nearly one hundred years old.

W.S.F.

Purchased.

1169.10-
547
Sect 19
Sig 6

Skull. Old fracture of the nasal and left malar bones.

The fracture occurred close to the upper border of the nasal bones and from the orbital margin of the malar towards the inferior angle.

The deformity of the nasal fracture is marked constituting a decided depression on the left side in which the internal angular process of the left frontal has shared. There is a fissure in the malar and slight exostoses on the orbital margin.

From a sabre cut.

Purchased.

1169.11- Nasal bones. Old fracture.
548
Sect 19
Shf 6

The bones were fractured just above the middle and have firmly united in good position.

Presented by Dr.W.S.Halsey.

1169.12- Portion of the skull. Gunshot fracture of both orbits.
549
Sect 19
Shf 6

The ball entered on the left side above the zygoma, passed through both orbits, fracturing the orbital border of the right malar bone, emerging at that point. The track of the ball is marked by projecting points of the ethmoid and other bones. The damage to the malar bone has been repaired by an irregular deposit of bone on the orbital border.

From a soldier wounded at Cold Harbor, Va., August 1864, who died of phthisis, January, 1869.

From the time of the injury there was total blindness. Post-mortem examination of the specimens showed fibroid degeneration of the right optic nerve and fibrous thickening of the sheaths.

Presented by Dr.H.Packard.

1169.13- Inferior maxillary. Ununited fracture.
566
Sect. 21
Shf 2

The fracture occurred through the left mental foramen. Failing to unite, the bone is thickened at the seat of fracture and the op-

posing edges are rough.

Presented by Dr.T.B.Mütter.

1169.14-F.25- Inferior maxilla. Old fracture of the body. Union.

567?

The fracture occurred midway between the symphysis and the right inferior dental foramen. The line of fracture approaches the symphysis at its lower part. Union occurred in good position, but with a deficiency at the alveolar border which exposes the fangs of the right incisors.

Presented by Dr.W.S.Halsey.

1169.15- Inferios maxilla, Fracture of the body, Union.

568
Sect. 21
Shf. 2

The fracture occurred close to the left side of the symphysis. Bony union has occurred in good position and is complete.

Purchased.

1169.16- Inferior maxilla. Fracture of the body and condyles. Recent.

569
Sect. 21
Shf 2

The body was fractured on the left side of the symphysis; a fragment of the outer wall of bone extending from the symphysis to the inferior dental foramen, is missing. Both condyles are missing, having been broken off obliquely

from without downwards and inwards,
H.H.S.

Purchased.

1169.17- Right half of inferior maxilla. Fracture
570 of the angle. Ununited.
Sect 21
Shf. 2

The line of fracture was oblique. Ligamentous union probably occurred to a slight extent although in their present state the fragments are ununited.

H.H.S.

Purchased.

1169.18- Inferior maxilla of old age. Fracture;
571 united.
Sect 22
Shf. 2.

The fracture occurred near the symphysis on the right side. The bone has also been accidentally brokwn, near the angle, after removal. The fracture was well united; the changes of old age are characteristic.

Dissecting room specimen; presented to Dr. W.S. Forbes by Baron Larrey.

Purchased.

1169.19- Inferior maxilla of old age. Fracture
572 near the symphysis. Union with deformity.
Sect. 22
Shf. 2

The fracture occurred almost exactly at the symphysis. Firm union has occurred in bad position due to sinking of the left fragment. A recent oblique fracture of the right half of the body has also occurred running from the angle downward and forward. The sockets of the

6852
1194.40

incisor teeth remain.

The angle of the body with the rami is 150°. Dissecting room specimen presented to Dr.W.S. Forbes by Dr. Von Laugenbeck,Berlin.

Purchased.

For figure,see Int.Encyl.Surgery.vol.~~III~~ 4,p.75.

1169.20- Skull. Fracture of the left malar. Fracture of the left condyle of the inferior maxilla. Union and sub-luxation.

550
Sect 19
Shf 6

The left malar was fractured obliquely, downwards anf forwards,near the zygoma. Union has occurred with slight depression of the zygomatic arch.

The left condyle of the inferior maxilla has doubtless been fractured,union having taken place with shortening and sub-luxation forwards, so that the condyle is anterior to the base of the zygoma.

The canine and bicuspid teeth on both sides are grooved from the use of a tobacco pipe.

Skull of a negress.

Purchased.

1169.21- Inferior maxilla. Oblique fracture of the ramas. Ununited.

573
Sect. 22
Shf 2

The left ramus was fractured obliquely in a line running from the sigmoid notch near

the coronoid process downward toward the angle of the bone. Union has not occurred. There is slight absorption of the adjacent edges of the fragments.

Purchased.

1169.22- Inferior maxilla. Fracture of the body.
574
Sec. 22
Shf 2

Recent.

The fracture occurred on the right side immediately behind the bicuspid tooth and mental foramen, passing vertically. Fissures are seen extending toward the ramus.

Presented by Dr. Mütter.

1171-10 Right superior maxilla. Supernumerary
575
Sect 22
Shf 2

bicuspid tooth. The tooth is well developed and lies on the inner side between the adjacent bicuspid and molar teeth.

Presented.

specimen missing

~~1171.20~~ 1171.20
~~1188.50~~- Inferior maxilla. Deformity of condyle.
581
Sect. 22
Shf. 2

Model.

The left condyle is large and irregular. It has an antero-posterior diameter of 2cm.

Presented by Dr. Mütter.

611

685 a
= 1194.40

1194-
560
Sec 18
Shelf 6

Skull of a negro. Displaced incisor tooth.

The right central incisor erupted immediately below the right nasal cavity, is directed outwards and forwards. The alveolar process is unaffected. The adjoining teeth have not closed the gap. The fang of the tooth is visible close to the anterior palatine foramen. The interparietal suture is remarkable for its direct course.

W.S.F.

Purchased.

~~1188.10~~ Inferior maxilla;massive. – Edurnated

Presented by Dr.J.Ewing Mears,

1171 50
~~1188.20~~ Inferior maxilla. Irregular situation of a central incisor,

The anterior wall of the symphysis has been removed displaying a central incisor which has a very oblique,almost a horizontal position. The crown is on the right,and the fang on the left,side. The crown nearly touches the extremity of the fang of the right canine. The central and right lateral incisors are imperfectly developed,owing doubtless to the presence of the incisor below;only their fangs are visible. A round hole made by a drill is seen in the apex of the crown of the irregular incisor.

From a subject about 21 years of age.

Purchased.

1171.60
~~1188.30~~ Inferior maxilla. Massive.

Dissecting room specimen.

W.S.F.

Purchased.

~~1188.10~~ Anterior portion of skull. Deflected nasal septum.

The septum,which is not complete,has a strong deviation to the right.

Presented by Dr.Mütter.

1171.70 - Inferior Maxilla. Massive. Pres. by Dr. J. Ewing Mears.

615

685 a
= 1194.40

specimen missing

1172.10 ✓ Deformity of the nasal septum

Presented by Dr. J. B. Roberts.

1172.50 - ✓ This specimen was removed from the upper jaw of President Cleveland by Dr. Jos. D. Bryant and Dr. W. W. Keen, July 1893.
Presented by Dr. Lasson C. Gibson of N.Y.

6852
F 1194.40

1176.01-
577
Sec 22
Shf 2

Section of the bones of the left face.

Caries of the antrum.

The walls of the left antrum are destroyed on all sides. The alveolar border is fragile and of small size. The margins of the surrounding bone are marked by bony ridges of rarified bone.

H.H.S. Purchased.

1176-
551
Sec 19
Shf 6

Skull. Caries of the superior maxillary.

The skull is from an old person, the angle of the inferior maxilla being very obtuse. The whole inferior border of the superior maxillary is carious, only one tooth, a right bicuspid, remains in the jaw. The nasal septum is displaced strongly to the right. The anterior wall of the right antrum has been accidentally broken. The temporal ridges are well marked.

Dissecting room specimen.

Purchased.

1176.02- Right half of the inferior maxilla. Caries.

578

Sect 22

Shf 2

There is a large cavity in the body near the angle, having a capacity of 2 c.c., opening above and on the inner side. Two molars are missing.

H.H.S.

Purchased.

1176.03- Inferior maxilla. Caries. Missing 4/6/39

The disease is superficial and extends chiefly on the outer surface of the right side of the body. There are large carious cavities formerly the site of second molars.

Presented by Dr. W.S. Halsey.

1176.04- Skull of a gorilla (troglodytes gorilla). Caries.

559

Sect 19

Shf 4

The external surface of the left angle of the inferior maxillary is carious; through an opening 1.5 x 1 cm. the spongy tissue can be seen.

The teeth are well worn; the right lower canine is small and nearly detached from the jaw.

Purchased.

1177- Skull. Necrosis of the face.

552

Sect 18

Shf 6

The disease is very extensive, having destroyed the right orbit, the bones of the nose, the body of the sphenoid and large portions of

the frontal superior maxillary right malar, parietal and temporal bones. A large opening 5 cm. in diameter is seen in the frontal region opening the cranial cavity. The edges of the bone are sharp and jagged. Small areas of necrosis are also seen in the left supra-orbital region and in the right angle of the jaw. The sutures are ossified.

Probably from a case of lupus.

Presented by Dr. Mütter.

1177.01- 553 Sect 18 Sub 6

Skull. Necrosis of the frontal, left malar, and inferior maxillary; in a child.

The frontal is necrosed at the left internal angular process and in the median line. A sequestrum was in process of formation near the internal angular process. The left malar bone is involved, especially on the inferior surface and a sequestrum lies between it and the superior maxilla. The left ramus of the inferior maxilla is wholly destroyed for the space of 3 cm. The margins of the remaining portions of bone are rough and friable. The base of the skull is also seen to be invaded.

The body and lesser wings of the sphenoid and the basilar process of the occipital and palatal bones have suffered.

The permanent teeth, including canines and bicuspids have not yet descended.

Presented by Dr. Mütter.

1177.025 Necrosis of the Jaw. Cause unknown. William Young - Oct 7 - 1/2/01

Page 627

1178.02- Superior and inferior maxilla. Cancrum oris.
582
Sect. 21
Shf 3.

The bones are from a child about three years old. The incisor and canine teeth of both jaws are missing. The alveolar processes are black but not carious.

Presented by Dr.Mütter.

Page 627
Vol 1-Pg 14

1178.03-(a)-Inferior maxilla. Cancrum oris.
583
Sect 21
Shf 3

The alveolar border is blackened in two localities;one,at the insertion of the left canine and first bicuspid;second,from the right canine to the posterior molar which has not erupted.

Presented by Dr. Mütter.

1179.01

Page 627

1178.04-(b)-Inferior maxilla. Cancrum oris.
584
Sect 21
Shf 3

The alveolar process is blackened at the insertion of the incisor,canine and first bicuspid teeth. Caries has not occurred.

Presented by Dr.Mütter.

1177.02-F30-Inferior maxilla. Necrosis.
~~580~~ 579
Sect 22
Shf 2

The ramus of the left side is missing.The body is,on the left side,necrotic and thickened.

H.H.S.

Purchased.

1177.035 - Inferior Maxilla - Small Necrosis

1178.06- Missing Sequestrum from inferior maxilla. Variola.

From William D., aged 7, who was severely attacked in March 1881, with variola. At the end of March a swelling appeared in the lower jaw; in May two teeth were taken out but necrosis in the lower jaw spread; in November the sequestrum was removed and comprises almost the entire thickness of the jaw at the angle of the left side and measures 4 x 6 cm.

Presented by Dr. Albert Fricke.

1177.03- 586 Sect 21 Shf 3 Inferior maxilla. Necrosis.

The right ramus is necrosed beneath the insertion of the masseter muscle. At the middle of the ramus the surface is rough and the cancellous tissue is exposed.

The bone is large; the angle of the ramus with the body of the bone is almost 90°.

Presented by Dr. Mütter.

1177.04- 587 Sect 21 Shf 3 Inferior maxilla. Necrosis from phosphorus.

Presented by Dr. Baker.

1177.05- 588 Sect 21 Shf 3 Necrosis of the inferior maxilla from Phosphorus.

The disease has destroyed the greater part of the left side. The pumice like appear-

1177.08 Left half of ramus of
591
Sect 21 Ramus of left half of lower jaw
Shf 3 Showing phosphorus necrosis

1177.12 Missing Phosphorus necrosis — and portion of ramus of right lower jaw
(1185 Langer) J. E. Mears.
591
Sect 21
Shf 3

1177.14 Necrosis of roof of superior maxilla and turbinates
551 Res by Dr. J. E. Mears

ance of the new bone is well seen.

Removed from Miss N., Akron, Ohio, by Dr. J. Ewing Mears, 1-22-'84 and 6-5-'84.

1177.06 Phosphorus necrosis of the jaw.
589
Sect 21 Left half of the lower maxilla removed
Shf 3 from Jacob S., May 13th, 1884.

1177.07 Necrosis of the jaw.
590
Sect 21 Result of fracture probably caused by ex-
Shf 3 traction of a tooth.

1177.09 Right half lower jaw. Phosphorus necrosis.
592
Sect 22 Removed by Dr. J. Ewing Mears.
Shf 3

Presented by Dr. Mears.

1177.10 Phosphorus necrosis. Portion of lower
593 maxillary.
Sect 22
Shf 3 Removed by Dr. J. Ewing Mears from Miss
Sallie G., aged 21. Presented by Dr Mears

1177.11 Right half of lower jaw. Phosphorus ne-
~~Sec~~ 594 crosis.
Sect 22 Removed by Dr. J. Ewing Mears, September
Shf 3 24th, 1883.

Presented by Dr. Mears.

1177.13 Necrosis of inferior maxilla; after var-
595 iola.
Sect 22
Shf 3

Presented by Dr. A. Fricke.

1178.02
1178.03 See page 623 Vol I
1178.04

1179-597 Sect 22 Shf 3

Lower half of skull. Exostosis of the alveolar processes.

The processes are thickened posteriorly to a breadth of 2 cm. Their surfaces are rough and, on the right side, there are the cavities of two molars long since displaced. Union has taken place between the posterior and middle clinoid processes on the left side.

Presented by Dr. Mütter.

1179.01- ~~580~~ 585 Sect 21 Shf 3

See Vol 1. Pg. 14

Inferior maxilla. Ostitis.

The bone is thickened, friable. The anterior molars are emerging.

From a child of about fifteen months.

under 1178.03 & 1178.04

Presented by Dr. Mütter.

1181- 554 Sect 18 Shf 6

Skull necrosis of the face; syphilitic.

The entire front of the face is involved. In the nasal region there is a vacancy in place of the ethmoid, nasal and lachrymal bones. The anterior portion of the superior maxillary, the body of the sphenoid are also destroyed. Openings are present between the nasal cavity and the antrum of both sides. The sutures are ununited.

Presented by Dr. Mütter.

1181.05- 555 Sect 18 Shf 6

Skull. Necrosis of the face; syphilitic.

The ethmoid, vomer, nasal and lachrymal and palate bones are wholly destroyed. The central portion of the superior maxillary and the body of the sphenoid are deeply involved. The frontal and maxillary sinuses are open. The skull is thick and heavy. The sutures are ossified. There are no other marks of disease about the skull.

Presented by Dr. Mütter.

1182-10 Right half of inferior maxilla. Tumor. (Model).

The tumor is 5cm. broad and 4 cm. long and envelopes the bone just anterior to the angle rising to the level of the sigmoid notch.

Presented by Dr. Mütter.

1182 15 Tumor of the Jaw.
Left half of inferior Maxilla —
No — 395
Sec — 10
Shelf — 2
Dr Mütter

685 a
= 1194.40

VERTEBRAE.

1183
to
1195

635

1183- Skull with atlas, paramastoid process.
557
18
6

Between the left occipital condyle and the mastoid process there is situated a process having a height of 1.5cm. and a thickness of 1.2 cm. It articulates by a small facet with the transverse process of the axis.

Presented.

1183.05- Three cervical vertebrae, deficiency of the posterior wall of the vertebrae canal.
599
Sect 21
Shf 3

The condition was probably acquired; it may have originated in violence which depressed the spinous process of the middle vertebrae after fracturing the left lamina. The specimen shows at present a vacancy through which the spinal cord is exposed.

The specimen is small but from an adult.

Purchased.

1183.10- Last three dorsal and first lumbar vertebrae, deficiency of the posterior arches.
600
Sect 21
Shf 3

This is a congenital condition. The deficiency is only in a narrow line generally not over a millimeter wide. In the tenth dorsal it is on the right of the spinous process; in the eleventh and twelfth in the median line and in the first lumbar on the left.

The specimen is from an adult.

Presented by Dr.Mütter.

1183.20- Two dorsal vertebrae. Fissure of the
~~612~~ posterior arch and anchylosis.
612 The fissure is narrow and lies on the
Sect 22 left side. The left segment of the arch is
Shf 3 anchylosed with the vertebrae below.
also 1191.10 — 1194.955

Presented by Dr.Mütter.

1183.30- Sacrum. Congenital absence of posterior
60 wall of the spinal canal. Coccygeal anchylosis.
Sect 21 The spinal canal is visible throughout
Shf 3 its whole extent. The edges are smooth and
their amount of separation varies from three
to twenty metres, being widest above. The
first portion of the coccyx is anchylosed
with the sacrum.

The specimen is from an adult.

Presented by Dr.W.S.Halsey.

see Pg. 645 - # 1185

~~1183.40- The vertebrae. Epiphyses ununited.~~
672 ~~from a man aged 23 years.~~
Se 22
6
Sf

~~Presented by Dr.Corse.~~

~~1187- The cervical vertebrae. Luxation of the~~
~~atlas.~~

634

685 a

OF 1194.40

641

. 685 a

OF 1194.40

643

. 685 a

OF 1194.40

7.75

ARREST OF DEVELOPMENT.

1184- Spina bifida; sacral. no 396 Sec 10 Shelf 2

Presented by Dr. Mütter.

1184.05- Spina bifida;sacral. no 397 Sec 10 Shelf 2

Presented by Dr. Mütter.

1184.10- Spina bifida;sacro-lumbar. no 398 Sec 10 Shelf 2.

Presented by Dr. Mütter.

Part of.

1185 The vertebrae. Epiphyses ununited
From a man aged 23 yrs.
672

Presented by Dr Corse.

.685 a
OF 1194.40
9.75

. 685 a
OF 1194.40
9.75

1187- 602 Sect 21 Shf 3 The Cervical Vertebrae. Luxation of the Atlas.

The atlas has left its articulation with the axis and their axes vary 45°. The head must have been violently twisted to the right; the transverse ligament and the ligament binding the first two vertebrae at the posterior portion of the canal were subjected to great violence,-almost rupture.

Removed from the body of a man who committed suicide by hanging. He was a lawyer of eminence, but addicted to drink and was recovering from an attack of mania a potu. The servant whom he had sent for aglass of water, onreturning within four minutes, found him suspended by the neck from a gas pipe projecting from the wall, his feet being on the floor. The man had tied a silk handkerchief around his neck and standing by the gas-pipe had after attching the handkerchief, jumped up. Death ensued immediately. The spinal cord was crushed.

Purchased.

1125- See 1187.

1188- 603 Sect 21 Shf. 13 Six lower cervical vertebrae. Fracture of the left lamina and pedicle of the fourth and of both laminae of the fifth cervical vertebrae. Recent.

The fracture of the fourth vertebra pass-

vertebrae canal. The loss of substance anteriorly has allowed the columna above to bend forwards 40°. The vertebrae column is fixed in this position by permanent callus thrown out so as to envelop the two fractured vertebrae and to bind them to those adjoining. This callus is strong, slightly rough and finely porous and has existed no very great length of time, although perhaps for a few months. The spinal cord was evidently compressed and subsequently obliterated by this accident. The surface of the vertebrae canal above and below are smooth.

Vertical section shows the anterior and upper edge of the first lumbar vertebrae situated posterior to the inferior and posterior edge of the eleventh dorsal, the body of the twelfth having nearly disappeared.

Presented by Dr. Mütter.

1188.20 Eleventh and twelfth dorsal and first lumbar vertebrae. Vertical fracture of the twelfth dorsal and crescentic fracture of the upper and anterior lip of the first lumbar. Recent.

605
Sect 23
Shf 3

The last dorsal is severely crushed. The left side of the body has suffered somewhat more than the right side. On the left the body is fissured transversely at the middle. The upper articulating surface has been forced downwards. This vertical pressure has fractured the first

tured the first lumbar vertebra at the anterior upper margin, nearly detaching a crescentic piece of bone embracing in the median line 7 mm. of the articular surface and 1 cm. of the anterior surface and being 5 cm. in extent.

The patient did not survive this accident long.

Purchased.

1188.30- Last three dorsal and first lumbar vertebrae; fracture of the body of the twelfth dorsal.

606
Sect 22
Shf 3

The body of the twelfth dorsal is crushed downward by pressure from above. The anterior border of the superior articulating surface is destroyed.

From a man who was crushed by the fall of a bank of earth. The man died instantly while being turned in bed while in the hospital.

Purchased.

1188.40- Ninth, tenth, eleventh, and twelfth dorsal and first two lumbar vertebrae. Fracture of the last dorsal. Recent.

607
Sect 22
Shf 3

The first lumbar was fractured by force vertically applied. The adjacent vertebrae are uninjured. The compact tissue of the body is forced forward and outwards in sections,

vertical fissures being seen at four places. The anterior plate overhangs the lumbar vertebrae, resting firmly on its lower border. The vertebrae canal has been exposed on the left side and shows a fractore of the right lamina. Portions of the three right lower ribs remain.

Presented by Dr. Mütter.

1188.45- Pelvis and upper ends of the femora.

#614 Case 20 Shelf 5

Fracture of the right wing of the first body of the sacrum. Union.

The right wing of the upper body of the sacrum was fractured close to the body, Union has occurred with absorption and consequent deformity. The spine inclines decidedly to the right, as is shown by the direction given the last lumbar vertebra which is attached to the specimen. The ligaments have been preserved.

Presented by Dr. Mütter.

1191- Two dorsal vertebrae, Atrophy of the bodies. also 1194.55 — 1194.60

609 Seat 22 Shf 3

The bodies are small and that of the superior vertebra is flattened, especially on the right side as though it had occupied a place in a column subject to lateral curvature. Posteriorly there is a deficiency of bone in the median line just below the superior notch.

This opening is 1.4 cm. in lateral extent.

Presented by Dr.Mütter.

1191.10- Two dorsal vertebrae. Atrophy of the
611 spinous process.
Sect 22 see 1183.20
Shf 3

Presented by Dr.Mütter.

1192- Eighteen lower vertebrae. Lateral cur-
615 vature.
Sec 20
Shelf 2

This vertebrae column presents three curves; the upper dorsal and the lumbar curves are convex on the left side; the lower dorsal curve is convex on the right side. The vertebrae are also turned on their vertical axis. In the upper dorsal region the antero-posterior line of the vertebrae points gently to the left, in the lower dorsal, to the right and in the upper lumbar to the left, thus following the direction of the curves. A line dropped from the middle of the last cervical vertebrae falls 4.5 cm. to the left of center of the fifth lumbar. Pressure in the line of each concavity has been followed by compression of both the intervertebral discs and of the bodies of the vertebrae. The result in the case of the bodies is marked and their measurement in a vertical line at the widest part-

4th Dorsal v. Right side, 13.5mm. Left side, 22mm.

10th Dorsal v.Right side,28 mm. Left side,23mm.
2nd Lumbar v.Right side,24mm. Left side,27mm.
The 10th,11th,and 12th Dorsal vertebrae present contiguous pouting exostoses anterior to the left facets. Similar ones are seen in the middle lumbar vertebrae of theright side.

Portions of the heads of the ribs remain attached to the specimen. The vertebral canal has been exposed by removing the spinous processes and pedicles. The bone tissue is not diseased.

1192,05 Thorax. Purchased. "Probably tuberculosis" Dr. McFarland
Vertebrae column and ribs — curvature
Presented by Dr. John H. Brinton
1192.10- vertebrae column,including the cervical, dorsal and three upper lumbar vertebrae with portions of the ribs. Lateral curvature.
617
Sec 20
Shelf 2

The curve involves all the dorsal vertebrae. These present a convexity upon the left side; their antero-posterior diameters are also turned in that direction. This allows the right ribs to hold a much more anterior position than do the left;consequently the right chest cavity was shallow;the left,deep. The body of the fifth dorsal vertebra has a thickness of 6 mm. measured in the vertical line anterior to the right facette;but has a thickness of 21mm. on the opposite side. The bone tissue appeared healthy. A line dropped from the apex of the atlas falls 5 cm. to the

left and slightly in front of the center of the second lumbar vertebra.

Purchased.

1192.15- Vertebral column with portions of the base of the skull, ribs and innominate bones. Lateral curvature.

618
Sec 20
Shelf 4

The curvature is chiefly in the lower dorsal region; convexity to the left ; rotation of the right ribs forward.

Purchased

1192.20- Dorsal and lumbar vertebral column with ribs, pelvis and upper end of femora. Lateral curvature.

623
Sec 20
Shelf 7

The deformity is marked. Two curves were present, one with the convexity on the right side in the upper dorsal region; the second with the convexity on the left in the lower dorsal and upper lumbar region. The upper dorsal vertebrae project over the body and a vertical line dropped from the first, passes through the anterior inferior spinous process. The vertebrae have also rotated on their vertical axes. In the upper dorsal region, the rotation is slightly to the right; it quickly passes to the left and attains its greatest degree in the eleventh and twelfth dorsal; the rotation then appears slightly to the right

665

in the lower lumbar region. The axis of rotation of the lower vertebrae is the extremities of the spinous processes; these, in the lumbar region preserve a straight line.

The right chest cavity is capacious; the left is narrow; the lower ribs of the right side have approached a straight line; the corresponding ribs of the left side are abnormally twisted and their extremities approach within 4 cm. of the bodies of the vertebrae. The rotation has apparently been produced by a force pulling the left ribs and transverse processes of the lower dorsal vertebrae, backwards, allowing the heads of the right ribs to advance. The ribs are strong. Anchylosis has taken place between the left ala of the sacrum and the fifth lumbar vertebra, while the corresponding portions of the opposite side seem to have atrophied.

The iliac crests are of equal height, but the right ischium is lower than the left. The right oblique diameter of the pelvis is 1.5 cm. greater than the left.

From an adult.

Purchased.

1192.25 Vertibrae Calumn and ribs
Curviture

Presented by Dr. George McClellan

p. 685 a
of 1194.40
I
19.35

#620
Sec 20
Shelf 4

1192.30- Vertebral column and pelvis. Lateral and antero-posterior curvature.

The cervical vertebrae, excepting the last, are not present; they and the first four dorsal vertebrae appear in the correct position; below this point, deviation to the left occurs with rotation in the same direction, the curvature reaching its highest degree at the eleventh vetebra. In this region the last four left ribs curve around the bodies of the vertebrae owing to a rotation of about 90°. This rotation gradually diminishes until the sacrum is reached. The last cervical vertabra is in a vertical line passing through the pubes; it is probable, however, that the upper vertebrae were carried more to the right, for the tenth and eleventh dorsal seem to have been forcibly separated, a wedge shaped gap existing between them. This point is 14 cm. distant from a line passing through the pubis and last cervical vertebra. Viewed posteriorly the spinous processes of the last five dorsal vetebrae lose their prominence, the angles of the left ribs protecting the bodies of the vertebrae. The ribs are flattened on the right side and excessively curved on the left. The pelvis is normal.

Purchased.

1192.40- Vertebral column, ribs and pelvis. Lateral curvature.

622
Sect 20
Shf. 7

Deviation to the right and rotation commenced with the dorsal vertebrae, reaching their maximum in the eight and ninth; a curvature to the left with rotation is seen in the lumbar region. The bodies of the third, fourth, fifth, sixth and seventh dorsal vertebrae are depressed to such an extent that they form a horizontal, instead of a vertical column; the third and fourth dorsal are actually on a lower plane than the fifth and sixth dorsal and approach within 5 cm. of the first lumbar vertebrae.

Owing to the rotation of the vertebrae, the heads of the ninth and tenth left ribs are anterior to the bodies of their vertebrae while the nine lower right ribs formtthe most prominent feature of the back. These ribs are very strong and broad and have apparently undergone an hypertrophy to prepare them for their function as protectors of the spine. The corresponding ribs of the left side are slender, long and nearly straight; they have not more than from one-third to one-half the thickness and breadth of their fellows of the opposite side. The lower ones are crowded together and the last left rib articulates in the middle of its shaft with the left transverse

process of the second lumbar vertebra; the ninth and tenth extend downwards below the crest of the ilium. The unequal vertical compression of the upper dorsal vertebrae is marked and they have a decided wedge shape.

The pelvis is normal and is from an adult female.

#619 Sec 20 Shelf 4

Presented by Dr. Mütter.

1192.50 Spinal curvature with nine fractures of ribs - X Purchased

1194-66 Sec 2 Shelf 2

Vertebrae column, thorax and pelvis of a young child. Pott's disease; antero-posterior curvature. Pg. 15 Vol 1

The atlas and axis are not present; the remaining cervical vertebrae are apparently healthy, but occupy an oblique position owing to the caries below. All the dorsal vertebrae are carious; in the upper and middle region the bodies have been crowded together and owing to the loss of substance in the inflammatory process, the top of the column has fallen forward while the spinous processes are apparently intact; the fifth dorsal thus becomes the vertebra prominens. Without sawing the specimen, it is not possible to state to what extent the vertebrae canal was encroached upon, but the sharp angle of 90° which the two portions of the vertebrae column make, would indicate a considerable encroachment with probable compression of the cord. The ribs are slender and approach the straight line. A

p. 685 a of 1194.40

horizontal line drawn through the superior margin of the sternum passes through the spinous process of the seneyth dorsal vertebra and is 12.5 cm. in length; the lateral diameter in the same horizontal plane is 11cm. The sixth, seventh and eighth ribs on both sides are crowded so closely together that there are no intercostal spaces for those ribs. The subject was decidedly "pigeon breasted" and, considering the condition of the epiphyses, was probably about two years old.

Presented.

1194.05- Vertebrae column, thorax, pelvis and por-
677 tions of the humeri and femora of a child.
Se 21 Pott's disease; antero-posterior curvature.
Sg. 6.

The disease involves seven lower dorsal and four lumbar vertebrae. The bodies of the vertebrae named are carious and, in some instances, have wholly disappeared. The spinous processes, however, are intact and form a gentle antero-posterior curve whose prominence is at the eleventh dorsal. The angle formed by the lumbar spines with the upper dorsal spines is 110°. The child was not pigeon-breasted, but the lower ribs rest on the crest of the pelvis. There are no evidences of rickets. The sternum has six centres of ossification; the fourth and fifth lie side by side.

Presented.

1194.0 6 - Specimen showing Coeliac abscess 675
injected - new no 677.1

1194.10 Last cervical; the dorsal and four lumbar vertebrae with the ribs. Pott's disease.

676
Sec 21
Sf. 6

The disease affects the nine lower dorsal vertebrae; the bodies of the ninth and tenth have disappeared. Caries was making rapid progress at the time of death. The compact tissue of the affected vertebrae has been destroyed and deep pits are seen in the cancellae. The heads of the ribs have also been involved. The angle of the dorsal with the lumbar vertebrae is 150°.

The strength of the shafts of the ribs indicates a powerful adult.

Presented.

1194.15 Four lower dorsal and first lumbar vertebrae. Pott's disease.

624
Sec 21
Shelf 4

The bodies of the tenth, eleventh and twelfth are deeply invaded, especially upon the left side; nearly half of the body of the eleventh dorsal has been destroyed and the process has involved the heads of the ribs upon that side. The ninth rib was weakened and fractured at the neck. The column did not yield in its direction; the meninges of the cord are seen through carious openings in the vertebral canal.

Purchased.

P. 678 a

stone of the curve, and they are separated. All the vertebræ involved in the curve are to be treated in this manner.

Dr. Shaffer has performed this operation twice on the cadaver. The spinal artery and nerve can be easily avoided, and there need be no fear of wounding the pleura. It was found quite easy to separate the articular processes with the lever.

1194.16

Primary Tuberculosis of the Laminæ and Spinous Processes of the Vertebral Column. (*Philadelphia Polyclinic*, February 6, 1894.) By John B. Roberts, M.D.

Three months previous to admission to the hospital the patient, ten years old, had fallen down two steps. She became paralyzed in the legs shortly after the injury mentioned, which was slight. When the child was seen there was no marked deformity of the spine. Paralysis of both legs was complete, both of motion and sensation, and bed-sores existed. Subsequently, swelling about the middle of the dorsal region appeared, but it was evident that this was not the ordinary kyphosis of tubercular disease of the vertebral bodies. The swelling was most marked on each side of the median line, being greater on the right than on the left. Believing that the case was one of tuberculosis of the laminæ, and that there was probably an abscess within the spinal canal, the author determined to do a laminectomy.

An incision was made in the swelling on the right side of the vertebral spines, from which a small amount of cheesy material, some small fragments of bone, and a considerable quantity of fluid blood escaped. The blood was dark in color and seemed to come from an active venous hemorrhage. The swelling on the left side consisted of a mass of tissue infiltrated with tubercular deposit. The patient died on the table from shock and bleeding, though the bleeding seemed to come only from veins and was not excessive, though it was quite free. Before the patient succumbed two vertebral arches had been removed which were so soft that the ordinary scalpel cut through them with ease, except in one place where the chisel was used. The spinal cord was flattened, but the finger could easily be passed into the vertebral canal above and below. This showed there was no pressure, except at the point where the tubercular swelling was situated. The hæmatoma was apparently due to the opening of a vein by the disease. A section of the spinal column was removed, examination of which shows that the tubercular disease was limited to the laminæ, and had not attacked the bodies of the vertebræ. The primary disease, therefore, was in the posterior arches of the vetebral column, instead of in the bodies where it is usually found. A pathological examination made by Drs. Coplin and Bevan prove the destruction of the bone to be due to tuberculosis. The bacillus was found in abundance.

Dr. Roberts reported the case because of its rarity. Some orthopædic authorities say that primary tuberculosis of the laminæ is unknown.

679

P. 685 a

T OF 1194.40

Ano 625
1194.16-
Sec 21
Shelf 4
1603
48
2

Dorsal spine,

Primary tuberculosis of the spinal arches.

Three months previously she had fallen down two steps. The exact history was difficult to obtain because of her ignorance of any other tongue than Russian. She became paralyzed in the legs shortly after the slight injury mentioned. It was difficult to determine whether any relation existed between the slight injury and the paraplegia, as one account of the fall seemed to indicate that it was due to heat prostration. When the child was admitted to the Hospital there was no marked deformity of the spine. Paralysis of both legs was complete, both of motion and sensation, and bed-sores existed. Subsequently, swelling about the middle of the dorsal region appeared, but it was evident that this was not the ordinary kyphosis of the tubercular disease of the vertebral bodies. The swelling was most marked on each side of the median line, being greater on the right than on the left. Believing that the case was one of tuberculosis of the laminae, and that there was probably an abscess within the spinal canal, I determined to do a laminectomy.

An incision was made in the swelling on the right side of the vertebral spines, from

p. 678 b

tightly around and above the fixation-needles and tied." Whatever method has been employed for rendering the limb bloodless, as the Esmarch bandage, is now removed. The operation is now performed. In the formation of flaps, the surgeon must be guided by the conditions present. The author prefers, when possible, to begin the skin-flaps six inches below the tourniquet, and to raise a cuff that includes the subcutaneous tissues down to the deep fascia and dissect it off to near the level of the trochanter minor. This is followed by a circular cut through the soft parts to the bone; here the blood-vessels, veins, and arteries are tied with good-sized catgut. After these are tied the muscular attachments are lifted off with scissors or the knife, keeping along very close to the bone. The capsular ligament is then divided, and, by forcible elevation, abduction, and adduction the disarticulation is easily effected. If now the tourniquet be carefully and gradually loosened, each bleeding-point may be determined and the forceps applied as required until the tube is entirely removed. The wound is then closed, with a drainage-tube from the acetabulum.

ORTHOPÆDICS.

IN CHARGE OF REGINALD H. SAYRE, M.D.,
Assistant to the Chair of Orthopædic Surgery, Bellevue Hospital Medical College, New York.

A Proposed Operation for Inveterate Cases of Rotary Lateral Curvature. (*Am. Medico-Surg. Bul.*, January 1, 1894).—At the December meeting of the New York Academy of Medicine Dr. N. M. Shaffer read a paper on this subject.

In a certain number of cases the deformity increases in spite of treatment, and with a view to unwinding the twisted spine he proposed to operate for the purpose of dividing the ligaments, whose strength prevented restoring the vertebræ to a normal position, on the same principle that inveterate club-feet require an analogous operation before they can be straightened. He proposed this operation in 1892, but, as it was discouraged by the general surgeons to whom the matter was suggested, the operation was not performed. The method is as follows:

Make a large curved incision on the concave side of the curve from one inch above the upper end of the pathological curve to one inch below it. An incision is then made through the trapezius muscle in the same line as the original incision, and the tissues dissected away, towards the spinous processes. This exposes the erector spinæ muscles. If necessary these are now divided, thus reaching the transverse processes. All the soft parts are here divided transversely, and after introducing a curved director between the ribs, and underneath the costo-transverse ligament, this ligament is divided with a probe-pointed bistoury. A small forceps lever is then placed between the two adjacent transverse processes, which form the key-

679
No 625
Sec 21
Shelf 4
1603
48
2
1194.16-

Dorsal spine,

Primary tuberculosis of the spinal arches.

Three months previously she had fallen down two steps. The exact history was difficult to obtain because of her ignorance of any other tongue than Russian. She became paralysed in the legs shortly after the slight injury mentioned. It was difficult to determine whether any relation existed between the slight injury and the paraplegia, as one account of the fall seemed to indicate that it was due to heat prostration. When the child was admitted to the Hospital there was no marked deformity of the spine. Paralysis of both legs was complete, both of motion and sensation, and bed-sores existed. Subsequently, swelling about the middle of the dorsal region appeared, but it was evident that this was not the ordinary kyphosis of the tubercular disease of the vertebral bodies. The swelling was most marked on each side of the median line, being greater on the right than on the left. Believing that the case was one of tuberculosis of the laminae, and that there was probably an abscess within the spinal canal, I determined to do a laminectomy.

An incision was made in the swelling on the right side of the vertebral spines, from

which a small amount of cheesy material, some small fragments of bone, and a considerable quantity of fluid blood escaped. The patient died during the operation. Before the patient succumbed I had removed two vertebral arches which were so soft that the ordinary scalpel cut through them with ease, except in one place where I used the chisel. The spinal cord was flattened, but I could easily pass my finger into the vertebral canal above and below. This showed there was no pressure, except at the point where was situated the tubercular swelling, and the hematoma was apparently due to the opening of a vein by the disease. I removed a section of the spinal column, examination of which, as will be seen by looking at the specimen before you, shows that the tubercular disease was limited to the laminae, and had not attacked the bodies. The primary disease, therefore, is in the posterior arches of the vertebral column, instead of in the bodies where it usually is found. A pathological examination made by Drs. Coplin and Bevan prove the destruction of the bone to be due to tuberculosis. The bacillus was found in abundance.

I report the case because of its rarity. Some orthopedic authorities say that primary

tuberculosis of the laminae is unknown.

Presented by Dr. John B. Roberts

1194.20- Dorsal and lumbar vertebrae. Pott's disease;antero-posterior curvature.

#626 Sec 4 Shelf 4

The disease involves the lower eight dorsal, and the first lumbar vertabrae;the first dorsal is not present. The bodies of the vertebrae named have been almost obliterated, allowing the superior portion of the column to bend forward,deviating 120° from the straight line. The spinous processes of the seventh,eighth,ninth,tenth, and eleventh dorsal vertebrae constitute the prominence of the back and their laminae are anchylosed,so as to form the acute angle. The vetebral canal is free and does not seem to have been constricted by the curvature. The heads of a few ribs are present on each side.

Presented by Dr.Mütter.

Vol. 1. Pg. 15

1194.25 Seven dorsal vertebrae. Pott's disease; antero-posterior curvature;anchylosis.

#627 Sec 4 Shelf 4.

The spinous and transverse processes and laminae constitute nearly all that remains of the vertebrae. The bodies have disappeared leaving a small residual mass rough and friable,embraced in the concavity formed by the arching vertebrae. The curve described amounts

to about 120°. The anchylosis is effected by irregular remnants of spongy bone and by ossific union of the laminae.

Presented by Dr.Mütter.

1194.30- Eleven dorsal and first lumbar vertebrae. Pott's disease. The bodies of the third to the tenth dorsal vertebrae are carious, causing antero-posterior curvature. The angular deviation amounts to 60°.

From a child aged eight or nine years of scrofulous taint. The disease was of two years duration and had not been treated.

Presented by Dr.J.Cheston Morris.

1194.35- Lower eight dorsal, and four lumbar vertebrae. Pott's disease; antero-posterior curvature; anchylosis.

The disease involves the six lower dorsal vertebrae and has completely destroyed the bodies of three; the column has fallen forward so as to bring the seventh dorsal within 2.5 cm. of the first lumbar vertebra, and so as to form with the lower portion of the column an angle of 80°. The antero-posterior curvature causes a wide separation of the spinous processes. The apices of the ninth and tenth are separated to an extent of 4 cm. but the supra-spinous ligament, though attenuated, is

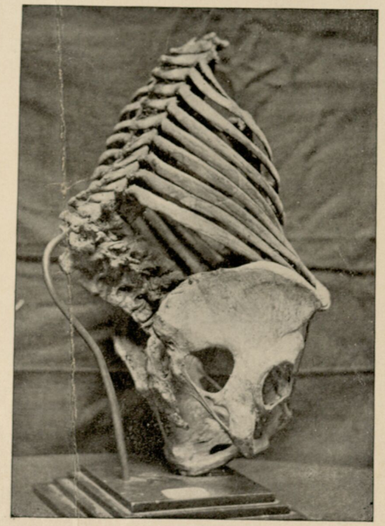

1194.40

1194.40 -

1365 14 Pelvis

not ruptured. Anchylosis has occurred between the lower three vertebrae, but the disease was active at the time of death.

From a well-developed adult.

Presented by Dr. Mütter.

1194.40- Vertebral column, thorax and pelvis, Pott's disease, antero-posterior curvature; obliquity of the pelvis.

The disease involves the bodies of the last four dorsal and first thr e lumbar vertebrae. The lumbar and lower dorsal have suffered to the greatest extent; the ninth and tenth show active caries but the excavations are not deep; the ninth affords an excellent illustration of the place where the disease first attacks a vertebra, viz., at the most anterior surface.

The upper vertebral column has tilted forward, but not so much as its angle with the lower portion of the column (90°) would indicate; in order to allow an approximately erect position of the thorax, the lumbar vertebrae are tilted backward. The spinous process of the first lumbar constitutes the most prominent object of the back. The vertebral canal is free. The thorax is of moderate capacity and occupies a fair position excepting that the five lower right ribs, as mounted, are crowded

together and project within and below the crest of the ilium.

The pelvis is oblique when the thorax is erect. The right iliac crest is 7 cm. above the left. In other respects it is not distorted; the acetabula do not show any changes and were adapted to receive a femoral head of small size. The pubic arch would indicate that the subject was an adult female. Flat oblique pelvis.

For pelvic measurements, see 1365.14.

Presented by Dr. Mütter.

1194.45 &1195- The ten lower vertebrae and sacrum; necrosis; anchylosis.

The disease affects all the vertebrae present. Their exterior is rough, in many places covered with exostoses. The bodies of the eighth dorsal and first and second lumbar present anteriorly cloacae through which may be seen sequestra which are loose and which have been derived from the spongy tissue. In the neighborhood of the cloacae are exostoses binding the contiguous vertebrae together. There was no curvature. The secrum is healthy.

Purchased.

689

Described as "probably tuberculosis" by Dr. Jas. McFarland - Curator Apr. 1939

1194.47- Ten dorsal and first lumbar vertebrae.

630

Caries. The disease was of long standing.

Sec 21 Shelf 4

Presented by Dr.A.S.Roberts.

1194.50- Missing Last three dorsal and first two lumbar vertebrae. Pott's disease;slight antero-posterior curvature.

The specimen is sawn vertically. The bodies of the last dorsal and first lumbar vertebrae are carious. The lower portion of the last dorsal is wholly destroyed and only the upper and posterior portions of the body remain. This has allowed the column above to tilt forward slightly. The body of the first lumbar has a large central excavation. The contents of this abscess were in a measure confined by a fibrous envelope which is seen on the right side of the affected vertebrae and which has a round opening 1cm. broad. The head of the eleventh right vertebra has been partly destroyed.

Purchased.

1194.55- Two lumbar vertebrae, Pott's disease; anchylosis, see 1191

608

Sec. 22 Shl 3

The bodies of the vertebrae are fused together,having lost by caries the intervertebral cartilage and adjacent portions of the bodies. Anchylosis has occurred with a

slight angular deformity.

Presented by Dr.Mütter.

1194.60- Two dorsal vertebrae. Caries, see 1191

610
Sec 22
Shelf 3

The vertebra affected is probably the tenth. The anterior and right portion of the body of the vertebra is destroyed. The intervertebral cartilage is intact.

Presented by Dr.Mütter.

1194.65- Four lumbar vertebrae and portion of the pelvis. Caries.

631
Sec 22
Shelf 4

The bodies of the fourth and fifth lumbar vertebrae are carious. The articular plates of the fourth are not invaded, but the anterior portion of the centrum is hollowed out by the disease. The inferior portion of the fifth lumbar at its junction with the sacrum is also eroded. Between the first and second sacral foramina on both sides there are ~~es~~ ex-ostoses.

The disease probably occurred late in life; there is no apparent curvature.

Presented by Dr.Mütter.

1194.70- Dorsal vertebra. Caries of the body and transverse processes.

632
Sec 22
Shelf 4

Purchased.

251 A-C
1049.75

1194.75- Skull with atlas and axis. Anchylosis.

558
18
6

The atlas is anchylosed with the occiput. The posterior arch is deficient for 3 mm. at the left of the median line. The left condyle of the occiput appears to have receded allowing the left articular surface of the atlas to occupy a higher plane than the right. The transverse process is thus cramped and atrophied. The axis is normal. The condition may have a traumatic origin.

Presented.

1194.76- Atlas and axis. Caries of the posterior arch.

~~632~~
633
Sec 22
Shelf 4

There is a deficiency in the posterior arch amounting to 4 cm. The extremities are roughened.

Presented by Dr.Mütter.

1194.77- Second and third cervical vertebrae, Anchylosis.

634
Sec. 22
Shelf 4.

The articulations between the two vertebrae are obliterated by anchylosis; the right superior articular surface is broadened, so as to present three times the area. The odontoid process is lengthened and pointed.

Presented by Dr. Mütter.

1194.78- Second and third cervical vertebrae.
635 Anchylosis.
Sect. 22
Shf 4 The articulations between the two vertebrae are obliterated by anchylos s which, however, does not involve the laminae and spinous processes. Anteriorly and between the two vertebrae, there is a small portion of bone nearly a centimeter in diameter and almost separated from the body.

Presented by Dr. Mütter.

1194.79- Second and third cervical vertebrae. Anchylosis.
636
Sect. 22
Shf 4. The anchylosis binds the two vertebrae together, not only by their bodies and articular surfaces, but by co-ossification of the laminae. The body of the axis projects in front of that of the third cervical vertebra, which is atrophied and pointed so as to resemble a spinous process.

Presented by Dr. Mütter.

1194.80- Second and third cervical vertebrae. Anchylosis. The bodies and articular surfaces are co-ossified.
637
Sect 22
Sh 4

Presented by Dr. Mütter.

1194.81- Five lower cervical vertebrae. Exostoses.
638
Sect. 22 The margins of the articulations and
Shf. 4 of the bodies of the vertebrae are everted
and prominent.

Presented by Dr.Mütter.

1194.82- The cervical vertebrae. Exostoses.
639 The margins of the articular surfaces
Sect 22 and of the bodies of the vertebrae are irreg-
Shf. 4 ular and present numerous exostoses.

Presented by Dr.Mütter.

1194.832- Second, third, fourth, fifth and sixth cer-
640 vical vertebrae. Exostoses.
Sect. 22
Shf. 4. The bodies are small and their margins
are fringed with an irregular ruffled deposit
of bone.

Presented by Dr.Mütter.

1194.834- Last four cervical vertebrae. Anchylosis.
644 The bodies and articular surfaces are
Sc 21 anchylosed. Posteriorly there are spaces be-
Sf. 4 tween the spinous processes.

Presented by Dr.Mütter.

1194.835 Axis and ~~third~~ cervical vertibrae.— Anchylosis
Presented by Dr. John H. Brinton

1194.836- Three cervical vertebrae. Anchylosis.
645 The bodies but not the articular surfaces
Sc 21
Sf. 4

are anchylosed. The bodies are atrophied.

Presented by Dr.Mütter.

1194.838- Three lower dorsal vertebrae. Anchylosis.
641 The bodies are co-ossified at their an-
Sect 22 terior borders, but the articular surfaces are
Shf 4 normal. In the situation of the inter-verte-
bral discs are smooth rounded exostoses.

Presented by Dr.Mütter.

1194.840- Two dorsal vertebrae. Anchylosis.
642 A plate of bone unites the two bodies on
Sect. 22 the left side. Its surface is smooth and con-
Shf 4 vex.

Presented by Dr. Mütter.

1194.842- Dorsal vertebra and rib. Anchylosis.
643 The rib is firmly anchylosed with the
Se. 22 vertebra. The spinous process is excessively
Sf. 4 long and measures 4 cm.

Presented by Dr.Mütter.

1194.844- Three lower dorsal and the lumbar ver-
646 te brae. Exostosis and anchylosis.
Se 21 The adjacent borders of the vertebrae
Sf. 4 have a prominent pouting character and in
many instances are connected by more or less
complete bony bridges; in the left lumbar

region these are especially prominent.

Presented by Dr.Mütter.

1194.846- Six lower dorsal vertebrae. Anchylosis.
647
Se 21
Sf. 4

The changes are seen chiefly on the right side. Over the situation of the intervertebral discs there are prominences of bone which serve to bind together the bodies of the vertebrae. There is apparently a carious condition of the surface of the left side of the vertebrae bodies.

Presented by Dr.Mütter.

1194.848- Four dorsal vertebrae. Anchylosis.
648
Se 21
Sf. 4

The disease is on the right side. The protruding bone deposit is smooth and most prominent over the intervertebral discs. The left side is unaffected.

Presented by Dr.Mütter.

1194.850- Three lower dorsal, and three lumbar vertebrae. Anchylosis.
649
Se 21
Sf 4

The disease in the dorsal vertebrae is confined to the right side where strong bone deposit binds the vertebrae together. In the lumbar region extensive new formation is present on both sides, especially on the right side where a large mass binds the first and

second vertebrae together. The space for the intervertebral disc is large and open anteriorly. There is no curvature.

Presented by Dr.Mütter.

1194.852- Two dorsal vertebrae. Anchylosis.
Se 650
Sb 21 Sect. 4 Shelf
The bodies are anchylosed throughout their opposing surfaces.

Presented by Dr.Mütter.

1194.854- Dorsal vertebra. Exostosis.
651
Se 22
Sb 4
The articular surfaces are everted and have prominent lips.

Presented by Dr.Mütter.

1194.856- Dorsal vertebra. Exostosis.
652
Se 22
Sb 4
The articular surfaces have prominent borders and the superior margin of the vertebral body projects.

Presented by Dr.Mütter.

1194.858- Lumbar vertebra. Exostosis.
653
Se 22
Sb 4
The vertebra is large and has prominent borders.

Presented by Dr.Mütter.

1194.860- Lumbar vertebra. Exostosis.
654
Se 22
Sb 4
Presented by Dr.Mütter.

1194.862- Lumbar vertebra. Exostosis.

655
Se 22
Sf. 4

Presented by Dr.Mütter.

1194.864- Lumbar vertebra. Exostosis.

655
Se. 22
Sf. 4

Presented by Dr.Mütter.

1194.866- Two lumbar vertebrae. Caries;anchylosis.

657
Se 22
Sf 4

The two bodies are firmly co-ossified. The lower body has undergone absorption after caries;it is deformed and the sides are covered with osteophytes.

Purchased.

1194.868- Three lumbar vertebrae. Anchylosis.

658
Se. 22
Sf 4

The anchylosis was incomplete,but large masses of bone project from the bodies upwards and downwards on both sides,rendering them practically immovable upon each other.

Purchased.

1194.870- Two lumbar vertebrae. Anchylosis.

659
Se. 22
Sf 4

The body of the upper vertebra has been compressed,whether consequent upon fracture or disease it is difficult to say; its height is about one-half that of the vertebra below. A fissureis also seen in the posterior portion of the upper surface of the body. This would suggest that fracture had occurred. The bodies are firmly anchylosed.

Presented by Dr.Mütter.

1194.872- Two lumbar vertebrae. Caries; anchylosis.
~~670~~ 660
Se. 22
Sf 4
The bodies are firmly co-ossified and their articulations are obliterated. The surfaces are rough and porous.

Presented by Dr.Mütter.

1194.874- Lumbar vertebra. Exostosis.
661
Se 22
Sf. 5
The articular surfaces and borders are fringed with inflammatory bone deposit.

Presented by Dr.Mütter.

1194.876- Lumbar vertebra. Exostosis.
662
Se 22
Sf 5

Presented by Dr.Mütter.

1194.900- Fifth lumbar vertebra and sacrum. Anchylosis.
663
Se 22
Sf. 5
The transverse processes of the vertebra are firmly co-ossified with the sacrum. The union is smooth and strong and of long standing. There is a space between the vertebra and the sacrum which was occupied by the intervertebral disc.

Presented by Dr.Mütter.

1194.905- Sacrum. Caries.
664
Se 22
Sf. 5
There is a large carious excavation in

the right side of the bone, communicating with the spinal canal. The posterior wall of the canal is deficient superiorly.

Presented by Dr. Mütter.

1194.910- Last lumbar vertebra and sacrum; from a child. Caries.

665 Sc 22 5 Sl

The segments of the sacrum have not united with each other by bone excepting posteriorly. The bone is carious on all sides.

Purchased.

1194.915- Segments of the coccyx; anchylosis.

666 Sc 22 Sl

The first fragment consists of the first and a portion of the second segments. They are co-ossified; the smaller segment being attached to the right lower corner of the first.

The other fragments consists of three of the lower segments co-ossified.

Presented by Dr. Mütter.

1194.920- Spinal column and pelvis. Antero-posterior curvature; anchylosis.

674 Sc 22 6 Sl

The specimen is from a very large powerful man. A slight backward curve in the lumbar region is seen in conjunction with a gentle anterior curve in the dorsal region. Throughout the dorsal region the vertebrae are co-ossified. The inflammatory bone pro-

duct is smooth, prominent over the discs and much more abundant upon the right side than upon the left. Between the last dorsal and first lumbar vertebrae and between the fourth and fifth lumbar there are exostoses of considerable prominence projecting, in the one case, to the left and in the other case, to the right. The second and third cervical vertebrae are also firmly co-ossified. The pelvis is massive.

Presented by Dr. Mütter.

1194.925- Vertebral column and pelvis, Anterior curvature; anchylosis.

673 Sr. 22 6 Sf

The disease is confined to the upper dorsal region. This region has been strengthened by inflammatory bone deposit which has taken place chiefly on the right side and which has rendered the spine immovable. The three upper cervical vertebrae are not present. There is a very slight curvature to the left.

From an adult male.

Presented by Dr. Mütter.

1194.930- Vertebral column with portions of the ribs. Anterior curvature; anchylosis.

671 Sr. 22 6 Sf

The greatest convexity is in the lower dorsal region. The curve is not extreme; it

was arrested by anchylosis which binds together all the vertebrae below the seventh dorsal. Exostoses are seen in the upper lumbar and lower dorsal vertebrae. There is no lateral curvatureor rotation.

Presented by Dr.Mutter.

1194.950- Vertebral column and pelvis. Anchylosis.
670
~~Sec 22~~
~~Sh. 6~~
Sec 10

The cervical vertebrae are not present; the remaining vertebrae are co-ossified on both sides of the bodies by the articular surfaces and by the spinous processes. The column is thus absolutely immovable. The crest of the ilia,the margins of the acetabula and the pubes are prominent from exostoses.

Purchased.

1194.955- Three lumbar vertebrae. Exostosis.
613
Sect 22
Shf. 13

The margins of the bodies and articular surfaces are rough and fringed with osteophytes.

Presented by Dr.Mütter.

1195.05- The lumbar vertebrae. Necrosis.
667
Sec 22
Sh. 5

The bodies of the third and fourth are involved and their cartilage has been destroyed. Between the remnants of the opposing bodies a sequestrum is seen, paler than the surrounding bone,but not detached. The vertebrae have been sawn vertically;there is no curvature.

Presented by Dr.Mütter.

1199- HYOID BONES.

1206- STERNA 1-6

1229- RIBS.

1199- ~~668~~ 669. Fracture of the right greater ~~corum;~~ cornu union.

Missing

SE 22

Sf 5

The fracture is united strongly with shortening and displacement to the inner side, but in the same horizontal plane.

There is a recent (probably post mortem) fracture of the opposite horn.

Presented.

1199.5- ~~669~~ 668 Hyoid bone; caries.

Missing

SE 22

Sf 5

The inner surface of the body is deeply eroded.

Presented by Dr. F.G. Smith.

STERNUM.

1202-678 Se. 23 Sf. 1

Oblique fracture of the sternum. Union.

The bone is well developed. The gladiolus was fractured near its junction with the manubrium. Viewed anteriorly, the callus marking the line of fracture runs from the attachment of the third right costal cartilage obliquely downward almost to the fourth left costal cartilage and then curves upward toward the third. The callus is strong and smooth. Viewed posteriorly, the callus is in an oblique, straight line running at a higher level; starting midway between the second and third right costal cartilages it descends to a point midway between the third and fourth left cartilages. The callus is smooth and prominent.

For figure, see Figure 597 International Encyclopaedia of Surgery. Vol. IV, p. 89.

Presented by Dr. MÜtter.

1202-10-679 Se. 23 Sf 1

Sternum 2. Transverse fracture of the sternum. Union.

The sternum was fractured transversely near its junction with the manubrium. Union has occurred with secondary changes in the bone. The union is not strong; anteriorly the surface of the bone is seen to be finely excavated in the neighbor-

hood of the fracture and the bone is narrow at that point. Posteriorly the bone is rough, almost honeycombed and presents at the seat of fracture a bridge of callus of fantastic shape. The bone is porous and was the seat of great vascular activity.

A portion of the second left rib and its cartilage remain; the latter is ossified and consists of a mere shell with an opening posteriorly. The costal cartilage of the opposite side as well as the third cartilages of both sides are ossified, but are mere shells.

The ensiform appendix is missing.

Purchased.

1206- 680 Erosion of the manubrium by aneurism.

Se 23
Sf 1
1752
107
6

The specimen consists of a large manubrium, 7.6cm. broad, and a portion of the gladiolus. The manubrium is hollowed into a thin shell and is perforated at many points by the action of an aneurism.

From a case of large aneurism of the transverse aorta with obliteration of the left carotid, and almost complete obliteration of the left subclavian arteries.

The patient had a well marked thrill and died after a pulmonary hemorrhage

from exhaustion. No rupture was found in the aorta.

Presented by Dr.Walter F.Atlee.

1207- 681 Caries of the sternum.

~~671~~ Sr. 23 Sf 1

The gladiolus is excavated from the junction of the third costal cartilage downward. The arrangement of the bone would suggest an abscess cavity enclosed below by the fenestrated remains of the gladiolus and bony prolongations toward the fifth, sixth and seventh right ribs.

Presented by Dr.Mütter.

1207.10- 682 Caries of the sternum.

~~672~~ Sr 23 Sf 1

Only a portion of the gladiolus with the costal cartilages remain; it is rough and carious at both extremities.

Presented by Dr.Mütter.

1214- 683 Sternum with ossified costal cartilages.

~~670~~ Sr 23 Sf 2

The ensiform appendix is unusually broad and flat and deviates slightly to the right side. The costal cartilages are partially ossified. In cross section, the bone is seen chiefly on the outside of the

cartilage and below it. At the extremity of the seventh right rib there is a nodule of bone carious on its under surface.

Presented by Dr.Mütter.

1217 ~~674~~ 684 Four lower left ribs, Fracture;union. The upper rib,probably the eighth,was fractured 7 cm. from its costal cartilage;the next lower rib was fractored 8 cm. from the angle;the next 12 cm.from the angle; and the lowest rib 5 cm.from the angle. The fractures have all been securely and smoothly united.

It is not necessary to presume that they occurred in the same person.

Presented by Dr.Mütter.

1217.02- ~~675~~ 685 Three right ribs, Fracture;union. The intervening rib is not fractured; the other ribs,which are perhaps the eighth and tenth,are fractured;the upper at a point 10cm. and the lower about 5cm. distant from the vertebral extremity. The upper one has united well,but the lower one,although strongly united,presents an exostosis pointing outward and backward.

Presented by Dr.Mütter.

1217.04- 686 Four left ribs. Fracture;union.
~~676~~
Se 23
Sf 2

The fractures in the two ribs occurred near the sternal end and in about the same vertical line. Union has occurred in good position and is of long standing. What are apparently the fifth and sixth ribs sustained double fractures dividing them into thirds.

Presented by Dr.Mütter.

1217.06- 687 Two left ribs. Fracture;union.
~~677~~
Se 23
Sf 2

In one, the fracture occurred 5 cm. from the tubercle;in the other at about the same locality;the vertebral ends of both are missing. The fractures have strongly united.

1217.08- 688 Right second rib;fracture;union.
~~678~~
Se 23
Sf 2

The fracture occurred at the middle; it is firmly united, but at a bad angle and with prominent permanent callus.

also 1217.20

Presented by Dr.Mütter.

1217.10- Right rib. Double fracture;union.
690
Se 23
Sf 2

The rib is from the middle thoracic region and was fractured at its middle

and at the sternal third. Both fractures have well united. The line of union is more prominent on the inner than on the outer side.

also 1217.12, 1217.14, 1217.18, 1217.22

Presented by Dr.Mütter.

1217.12- Right rib. Double fracture; union.

691

Sec 23

Sb 2

This rib is from the same locality and is fractured in the same way as the previous specimen. The rib is slightly heavier and the lines of union somewhat more distinct.

see 1217.10

Presented by Dr.Mütter.

1217.14- Right rib. Fracture; union.

692

Sec 23

Sb 2

This rib is from the upper thorax and was fractured at the vertebral third. Union has occurred with a slight prominence of the vertebral fragment; the surface at the place of union is smooth.

see 1217.10

Presented by Dr.Mütter.

1217.16- Right rib. Fracture; union.

702

Sec 23

Sb 3

The rib is from the lower thorax; the fracture occurred at the proximal third; the point of union is marked by

projections of callus above and below.

Presented by Dr.Mütter.

1217.18- Right rib. Fracture; union.
693
The rib is from the middle thoracic
Sq 23 region and was fractured at the vertebrae
Sq 2 third. Union has occurred and the bone at
the point is strong and smooth.
see 1217.10

Presented by Dr.Mütter.

1217.20- Left first rib. Fracture; union.
~~699~~ 689
The fracture was oblique and passed
Sq 23 from the inner side opposite the tuberos-
Sq 2 ity forward and outward. The vertebral
fragment terminates in a spine. The
union is strong.
see 1217.08

Presented by Dr.Mütter.

1217.22- Left second rib. Fracture; union.
694
The fracture occurred 7 cm. from the
Sq 23 sternal extremity and passed laterally
Sq 2 in reference to the body, obliquely as to
the bone. Union is strong. There is a
slight prominence of the distal fragment.
see 1217.10

Presented.

1217.24- Left rib. Fracture; union.

695

Sz 23

Sb 2

The rib was fractured 10cm. from the tubercle;it has united strongly,but with decided roughness on all sides of the point of union. The specimen was from the lower dorsal region.

Purchased.

1217.26- Left rib. Fracture; union.

696

Sz 23

Sb 2

The fracture occurred 12 cm. from the tubercle;union is strong and the united surfaces are smooth;the bone being of its usual thinness at this point. The vertical diamater is increased. One of the lower ribs.

Purchased.

1217.28- Left rib. Fracture; union.

697

Similar to the preceding specimen.

Sz 23

Sb 2

Purchased.

1217.30- Right rib. Fracture; union.

698

Sz 33

Sb 2

The fracture occurred 5cm.from the sternal extremity. It has united with scarcely a trace of the event. An upper rib.

Purchased.

1217.32- Right rib. Fracture; union.

699

The fracture occurred 1 cm. from the sternal extremity. Union has taken place with smooth surfaces and in perfect line.

Purchased.

1217.34- Left rib. Fracture; union.

700

The rib is probably the third or fourth and is strong. The fracture occurred 7 cm. from the sternal extremity and has united strongly, but with excrescences of permanent callus above and below. The lower projection is 2 cm. long, is thick and points downward and forward.

Presented by Dr. Mütter.

1217.36- Left rib. Fracture; union.

701

This rib resembles the preceding, but is from a somewhat lower position. The sternal fragment is over-lapped by the proximal fragment and callus forms a slight tuberosity above and below. The fracture occurred 9 cm. from the sternal extremity.

Presented by Dr. Mütter.

1217.37- Left rib. Fracture; union.

702

The fracture occurred 10 cm. from the sternal extremity and has united with excellent result, both inner and outer surfaces being smooth; the vertical diameter is slightly increased.

Presented by Dr. Mütter.

1217.38- Left twelfth rib. Fracture; union.

703
Sr 23
86 3

The rib was fractured slightly nearer the vertebral end than the sternal. Union is firm but above and below the union there are exostoses.

Presented.

1217.39- Left eleventh rib; oblique fracture; union.

704
Sr 23
86 3

The fracture occurred at the proximal third.

Presented by Dr. Mütter.

1217.40- Left twelfth rib; oblique fracture; union.

705
Sr 23
86 3

The fracture occurred at the proximal third; union is firm.

Presented by Dr. Mütter.

1217.41- Left twelfth rib. Fracture; union.

706
Sr 23
86 3

The rib was fractured at the proximal third and has united well, but with some permanent callus above and below the site of fracture.

Presented by Dr. Mütter.

1217.42- Right rib. Fracture of the shaft; union.

The fracture occurred at the middle of the shaft; union has occurred with depression of the external surface. The head is small and has a small facette which originally may have been double.

Presented by Dr. Halsey.

1217.44- Right rib. Fracture of the shaft; union.

The fracture is at the middle and the union is strong.

Presented by Dr. Halsey.

1217.46- Left rib. Double fracture; union.

Both fractures occurred at the middle; they are distant only two centimaters from each other. It is impossible to say whether they occurred at the same time or not. The bone is irregular and rough

over the seats of injury.

Presented by Dr.Halsey.

1217.48- Left rib. Fracture; union.

The fracture occurred at the middle and has united well. There is more irregularity on the inner than on the outer side.

Presented by Dr.Halsey.

1217.50- Left rib. Fracture; union.

The fracture occurred 6 cm. from the proximal end. Union is good.

Presented by Dr.Mütter.

1217.52 Portion of ribs and sternum. — fracture

Presented by Dr John H. Brinton.

1217.54 Four ribs; — fracture — union.

Presented by Dr George McClellan.

1224- Two left ribs. Synostosis.

The ribs are probably the third and fourth. They are united by a strong osseous band, smooth and dense; having a breadth of 2 cm.

Presented by Dr.Mütter.

1224.05- Right and left first ribs. Anchylosis.

There is co-ossification of the ribs with the manubrium. The under surface of the manubrium is rough and on the right side the junction with the rib is rough

and was evidently the seat of inflammatory action.

Presented by Dr.Mütter.

1224.10 Two first ribs. Anchylosis with the manubrium.

The ossification of the cartilages is complete and the manubrium has apparently separated from the gladiolus. The outer border of the manubrium is rather sharp and is marked by small prominences, but gives no evidence of of articulation or junction with the remainder of the sternum. There is,however,apparently on the inner surface a diamond shaped facet. Section of the bone through the middle of the gladiolus shows a triangular cross-section a cavity of nearly 1 cm. in diameter with hardened contents. This cavity must have a length of 2cm.

Presented by Dr.Mütter.

1224.12 Two right ribs. Synostosis.

The ribs are united at their necks by a strong osseous band,smooth and 2cm. in width.

Presented by Dr.W.S.Halsey.

1224.14- Twelve right ribs. Ostitis of the head and neck.

716
Sz 23
Sb 4

1224.16- Twelve left ribs. Ostitis of the head and neck.

717
Sz 23
Sb 4

1229- Right first rib. Ossified cartilage.

718
Sz 23
Sb 4

Presented by Dr.Mütter.

1232.01- Right clavicle;recent fracture sternal extremity.

720
Sz 23
Sb 4

The fracture is comminuted and is close to the extremity.

Purchased.

destroyed
1232.02- Fracture of the left clavicle. Deformity.

721
Sz 23
Sb 4

The specimen consists of a plaster cast of the clavicle and a portion of the sternum. The fracture occurred at about the middle. There is posterior displacement of the acromial end and 4 cm. of overlapping.

H.B.Tuson fecit.

Purchased.

1232.04- Left clavicle;oblique fracture of the outer third.

There is strong union and smooth callus.

Purchased.

1232.06- Right clavicle;fracture of the outer extremity;union.

1232.08- Fracture of the clavicle;union.

The bone was broken at the middle.

The callus is massive.

also 1232.10

Presented by Dr.Mütter.

1232.09- Fracture of the clavicle;union.

Presented by Dr.Mears.

1232.10- Left clavicle;fracture of the acromial end. Union. see 1232.08

Presented by Dr.Mütter.

1232.12- Left clavicle;simple fracture between the middle and outer third.Union.

The subject,aet.19,had his clavicle broken by a fall on his shoulder. He was treated by placing a pad in his axilla held in place by adhesive straps. The

outer fragment was carried upwards, outwards and backwards and held in its proper relation to the inner fragments by adhesive straps, holding the forearm and arm across the lateral and anterior aspect of the thorax. (W.S.F.)

Purchased.

1232.14- Right clavicle. Fracture at the outer third. Union.

728 Sc 23 Sb 4

Purchased.

1232.16- Left clavicle. Comminuted fracture at the middle.

729 Sc 23 Sb 4

The patient aet.22, received a blow on his clavicle. The axillary pad and adhesive straps were used and straps after the third bandage of Dessault.

Union has occurred, but there is some caries at the sternal end.

Purchased.

1232.18- Right clavicle; fracture at the middle; union.

730 Sc 23 Sb 4

Presented by Dr. Mütter.

1232.20- Right clavicle; fracture at the middle; union.

731 Sc 23 Sb 4

Presented by Dr. Mütter.

1232.22- Right clavicle;fracture at the outer
732 third;union.

Presented by Dr.Mütter.

1232.24- Right clavicle;fracture at the inner
733 third;union.

Purchased.

1232.26- Left clavicle;old ununited fracture
*734 at the inner third.

The specimen shows necrosis and exostosis. A sequestrum is in process of formation at the inner fragment.

Purchased.

1232.28- Left clavicle;fracture of the out-
735 er third;union.

Presented by Dr.Mütter.

1232.30- Left clavicle;fracture of the outer
736 third;union.

Presented by Dr.Mütter.

1232.32- Left clavicle;fracture of the outer
737 extremity;union with deformity from excessive callus.

Purchased.

753

1232.34- Left clavicle;fracture of the scap-
738 ular end;deformity;excessive callus;short-
Sec 23
Shelf 5 ening.

Purchased.

1232.36- Right clavicle;fracture of the out-
739 er end;union;excessive callus.
Sec 23
Shelf 5

Purchased.

1232.38- Right clavicle;oblique fracture of
740 the middle;union and shortening.
Sec 23
Shelf 5

Purchased.

1232.40- Right clavicle;fracture of the out-
741 er end;union.
Sec 23
Shelf 5

Purchased.

1232.42- Right clavicle;fracture of the out-
742 er end;union.
Sec 23
Shelf 6

Purchased.

1232.44- Left clavicle;fracture of the mid-
743 dle;union.
Sec 23
Shelf 6 see 1232.46 + 1237

Presented by Dr.W.S.Halsey.

1232.46- Right clavicle; fracture of the acro-
744
Sec 23
Shelf 6 see 1232.44

251 A-C
1049.75

1232.52 Clavicle — oblique fracture at the middle — union.
Presented by Dr. John H. Brinton.

1232.54 Clavicle — oblique fracture — union
Presented by Dr John H. Brinton

1232.56 Clavicle — fracture at the end — union — vertical section.
Presented by Dr. John H. Brinton

1232.58 (A) (B) Clavicle - fracture at the middle — union — vertical section
Presented by Dr. John H. Brinton

1232.60 (A) (B) Clavicle - fracture — union with over laping — vertical section
Presented by Dr. John H. Brinton

mial end;union.

Presented by Dr.W.S.Halsey.

1232.48- Right clavicle;fracture at the middle;union. also 1237.05

746
Sec 23
Shelf 6

Presented by Dr.Mütter.

1232.50- Left clavicle and scapula;fracture at the acromial end of the clavicle; union.

748
Sec 23
Shelf 6

There is a small exostosis of the inferior surface of the clavicle at the seat of fracture.

Presented by Dr.Mütter.

1237- Left clavicle;caries of both extremities. see 1232.44

745
Sec 23
Shelf 6

Presented by Dr.Halsey.

1237.05- Left clavicle;caries of the acromial end. see 1232.48

747
Sec 23
Shelf 6

Presented by Dr.Mütter.

1237.10- Right clavicle;caries. also 1238

749
Sec 23
Shelf 6

Presented by Dr.Mütter.

251 A-C
1049.75

1237.15- (2) Caries of the right clavicle.
751
Sec 23
Shelf 6

Purchased.

1237.20- Caries of the left clavicle.
752
Sec 23
Shelf 6

Purchased.

1237.25- Right clavicle;caries,
753
Sec 23
Shelf 6

The disease is so great that fracture has occurred from disintegration.

Presented by Dr.Mütter.

1238- Left clavicle. Necrosis of the shaft.
750
Sec 23
Shelf 6

see 1237.10

Presented by Dr.Mütter.

1238.05- Clavicle;necrosis.
754
Sec 23
Shelf 6

This is a marked example. The sequestrum is situated at the acromial end and is large and surrounded by involucrum.

Purchased.

1239- (2) Right clavicle;slight exostosis.
755
Sec 23
Shelf 6

Presented by Dr.Mütter.

1239.10- Left clavicle;exostosis at acromial end.
756
Sec 23
Shelf 6

Presented by Dr.Mütter.

251 A-C
1049.75

1239.20- Right clavicle;exostosis at acromi-
757 al end.
Sec 23
Shelf 6

Presented by Dr.Mütter.

1239.30- Left clavicle;exostosis at acromial
758 end.
Sec 23
Shelf 6

Presented by Dr.Mütter.

1242- Right clavicle;syphilis.
759 The bone is enlarged and is rounded.
Sec 23 The surface is porous.
Shelf 6

From a man who had been treated for tertiary syphilis,but died as the result of a fall.

Purchased.

251 A-C
1049.75

251 A-C
1049.75

1245- Left scapula. Non-union of the epiphysis of acromion.

The epiphysis is 2 cm. long and has a transverse base which is smooth. It was not united to the acromion. In this case the condition is more likely to have been physiological than pathological. The supra-scapular notch is very deep.

Purchased.

1245- SCAPULAE.

1262- HUMERI.

Fig. 674.

Fracture of the posterior angle of the scapula. Two specimens. Dissection.

Specimen 2. Left scapula. Stellate fracture of the superior angle.

[illegible] that is the spine [illegible] order, fracture [illegible] ward to the posterior. The line [illegible] the superior horizontal [illegible] reaching the [illegible] as a fragment 2X3 [illegible] backward terminated [illegible] 4cm. from the [illegible] fractures are well united [illegible] especially near the [illegible] is abundant. There is no [illegible] the supra-scapular nerve.

Presented by Dr. [illegible].

1247. Specimen 1. Left scapula. Fracture of the posterior angle. Dissection.

1245- Left scapula. Non-union of the epiphysis of acromion.

The epiphysis is 2 cm. long and has a transverse base which is smooth. It was not united to the acromion. In this case the condition is more likely to have been physiological than pathological. The supra-scapular notch is very deep.

Purchased.

1247- Scap.2. Left scapula. Stellate fracture of the superior angle.

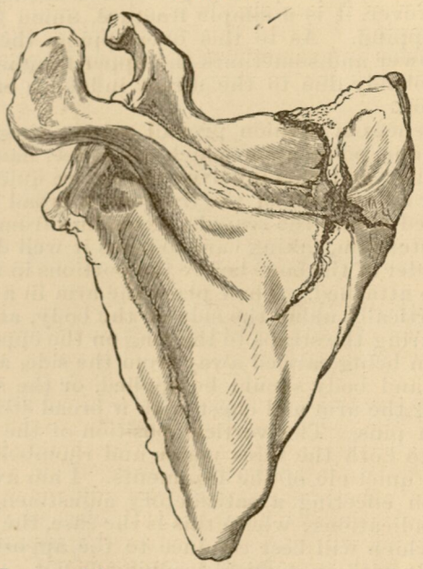

FIG. 674.

Fracture of the posterior angle of the scapula. Mütter collection.—Hamilton.

nt in the spine
rder, fracture
ard to the pos-
d. The line
e superior bor-
ine reaching the
l a fragment 2X5
vnward terminated
sa 4cm. from the
ractures are well
united. The callus, especially near the superior border, is abundant. There is no notch for the supra-scapular nerve.

Presented by Dr. Mütter.

1247.05- Described on Pg. 773 - # 1262.05 in cross index number.

1247.10- Scap.3. Left scapula. Fracture of the acromion. Ununited.

1245- Left scapula. Non-union of the epiphysis of acromion.

The epiphysis is 2 cm. long and has a transverse base which is smooth. It was not united to the acromion. In this case the condition is more likely to have been physiological than pathological. The supra-scapular notch is very deep.

Purchased.

1247- Scap.2. Left scapula. Stellate fracture of the superior angle.

Starting from a point in the spine 2cm.from the posterior border,fracture lines passed upward,backward to the posterior border,and downward. The line passing upward reached the superior border and by means of the line reaching the posterior border detached a fragment 2X5 cm. The line passing downward terminated in the infra-spinous fossa 4cm.from the point of starting. The fractures are well united. The callus,especially near the superior border,is abundant. There is no notch for the supra-scapular nerve.

Presented by Dr.Mütter.

1247.05 - Described on Pg. 773 - # 1262.05 is cross index number.

1247.10- Scap.3. Left scapula. Fracture of the acromion. Ununited.

The acromion is fractured 5 cm. from its extremity. The opposing surfaces are rough. There is no ligament. The fragment is somewhat longer on its under surface than above. The supra-scapular notch is well marked.

Presented.

1247.20- Scap.4. Right scapula. Ligamentous union of the acromion.

763
Sz 24
86.1

The end of the acromion, 3 cm. in length is united to the acromion by ligament. The separation is in a straight transverse line and was, in all probability, the epiphyseal junction which was never osseous. This was probably not a case of fracture. The other centres of ossification are all united. The transverse ligament has been preserved.

Presented by Dr. Mütter.

1247.30- Right scapula. Fracture of the coracoid process and body of the scapula. (Model).

764
Sz 24
86.1

The coracoid process is fractured in a line passing close to the supra-scapular notch from the under side downward to the supra-spinous fossa close to the outer or acromial margin of the glenoid cavity. The body of the bone is fractured

transversely by a line passing below the spine. It is a recent fracture.

H.B.Tuson, London, fecit.

Purchased.

V. 1 p. 767 a-b.

De Forest Willard

ALS; [Philadelphia, Pa.] to unknown correspondent, [n.d.] Apr. 28.

Re: 1150.50

2 to 2.5 cm. The edges are sharp and ragged.

H.H.S.

Purchased.

transversely by a line passing below the spine. It is a recent fracture.

H.B.Tuson,London,fecit.

V. 1 p. 767 a-b.

De Forest Willard

ALS ; [Philadelphia, Pa.] to unknown correspondent, [n.d.] Apr. 28.

RE ; 1150.50



1247

1253

7

Sp

coming into it, having a diameter of from 2 to 2.5 cm. The edges are sharp and ragged.

H.H.S.

Purchased.

transversely by a line passing below the spine. It is a recent fracture.

H.B.Tuson,London,fecit.

Purchased.

1247.40- Right scapula. Comminuted fracture of the base of the acromion process.Union.

One line of fracture passed transversely 5cm. from the apex of the acromion. The other passed at a right angle to it from its centre toward the border. A small fragment of the superior edge of the spine 3cm. long was thus detached. Union is complete on the under surface with a moderate amount of callus;on the outer surface the fracture lines are markedly deep indentations. The transverse ligament has ossified,leaving a large oval foramen.

Purchased.

1247.56- Right Scapula. Fracture.

1253- Right scapula. Necrosis.

The greater portion of the posterior border is destroyed. There is a large opening at the base of the spine and extending into it,having a diameter of from 2 to 2.5 cm. The edges are sharp and ragged.

H.H.S.

Purchased.

1254- Left scapula. Exostosis and fenestration.

767

The bone is not long but is very strong and well marked. There is at the point of origin of the long head of the triceps a bony prolongation nearly 1cm. long. Four cm. behind the glenoid cavity there is an oval fenestration, which has its external opening immediately below the bse of the acromion process and which has a diameter of 1cm. The ridges for the insertion of the septa of the subscapularis are well marked.

Presented.

1254.10- Left scapula. Exostosis.

769

On the under surface above the middle of the posterior border there is an exostosis having a broad round base, a diameter of from three to three and a half centimeters and a height of 1.5 cm. Its surface is rough excepting near the center where there has been some attrition from contact with a rib.

Dissecting room specimen.

W.S.F.

Purchased.

1254.20- Right scapula. Arthritis.

770

The glenoid cavity is deformed by

callus deposit. Its lateral diameter is short from loss of substance on the under margin. Its surface is rough and marked by vertical ridges. The bone is small.

Presented by Dr.Mütter.

1254.30-Right Scapula-Caries.

1259- Scap.13. Left scapula. Short acromion. The acromion process does not overhang the glenoid cavity to the usual extent.

771
Sk 24
Sb 2

Presented by Dr.Mütter.

1259.05- Scap.5. Left scapula. Indentation of the epiphyseal junction of the acromion. Two and five tenths centimeters from the tip of the acromion there is a transverse line, deeply indented, marking the epiphyseal junction. This was possibly not a case of fracture. There are no other epiphyseal lines present. The bone is large. The supra-scapular notch is slight.

772
Sk 24
Sb 2

Presented by Dr.Mütter.

1259.10- Left scapula. Artificial separation of the epiphysis of the acromion. Supra-scapular notch marked.

773
Sk 24
Sb 2

Presented by Dr.Mütter.

251 A-C
1049.75

1262- Right scapula, clavicle and upper
790 half of humerus. Fracture of the anatom-
8 25 ical neck of the humerus. Dislocation of
86 the head. Fracture ununited.

The upper fragment comprising the head of the humerus lies below the coracoid process and on the subscapular side of the neck of the scapula. It is firmly united to the latter, to the coracoid process and to the clavicle by callus. The upper end of the shaft of the humerus is large and very irregular from deposition of callus. The original shaft at this point is in a process of softening. The acromion is also irregular.

H.H.S.

Purchased.

1247.05 number changed to 1247.05
~~1262.05~~ Right scapula and humerus. Fracture
791 of the surgical neck. Union.
8 25
86

The head of the humerus lies in the glenoid cavity; it is atrophied and united by callus to the shaft of the humerus, which lies directly in front of it. The interior of the head is exposed by openings lying in the external surface. The tendon of the long head of the biceps remains. Motion was possible to a very slight extent.

H.H.S.

Purchased.

251 A-C
1049.75

1262.10- Left humerus. Fracture of the neck below the tuberosities. Impacted.

The fracture passed below the tuberosities and through the articular surface immediately above them. Only slight callus is seen. Vertical section shows an irregularity of the compact substance, indicating the passage to a slight extent, of the shaft into the head.

Presented by Dr.Mütter.

1262.15- H.4. Left humerus. Fracture of the surgical neck. Union.

The fracture passed immediately below the condyles and through the lower portion of the anatomical neck. The lower fragment was drawn to the inner side and has united in a position of outward rotation. An irregular opening leads through the callus in the anterior surface to the head. The union is strong.

Presented by Dr.Mütter.

1262.20- Portions of left humerus and scapula. Fracture of the anatomical neck. Union and eburnation.

The head is depressed, atrophied and eburnated. Its union with the shaft is

marked by an exuberant outgrowth of callus, which hangs in a large mass from the lower portion. The glenoid cavity is eburnated. The capsular ligament, tendon of the long head of the biceps and coraco-acromial ligament remain.

Purchased.

1262.25- Portions of the left humerus, scapula and clavicle. Separation of the upper epiphysis of the humerus. Necrosis of the upper shaft.

The head of the bone is rough and devoid of cartilage. The upper shaft of the humerus is in process of separation as a sequestrum. It is rough and of very irregular outline and its boundaries are marked by a deep groove about 1mm. wide. The coraco-acromial ligament remains. The bones are slender.

Purchased.

1262.26- Right humerus. Old fracture of the surgical neck. Absorption of the head.

Presented by Dr. A.S. Roberts.

1262.30- Right humerus. Fracture of the greater tuberosity.

Fracture of the greater tuberosity has probably occurred with slight posterior displacement due to the action of the supra-spinatus, infra-spinatus and teres minor muscles. A deep fissure lies between this fragment and the head of the capsular ligament. Motion of the head must have been modified by the prominence of the fragment. The uniting callus is smooth.

Purchased.

1262.35- Left humerus. Fracture of the upper third; union.

797 26 1

Union has occurred in excellent line, but with several sharp projections on the anterior and inner aspects of the seat of fracture.

Presented by Dr. J. Ewing Mears.

1262.40 Upper end of right humerus. Fracture of the upper shaft. Recent.

803 26 1

The specimen is 10cm. long. The fracture is transverse. A small amount of callus is seen on the inner surface.

Purchased.

1262.45- H.7. Right humerus. Oblique fracture of the shaft. Union.

798 26 1

251 A-C
1049.75

The fracture involved the upper portion of the shaft. Union has occurred in good position, but with prominence of the callus on the posterior side and an abrupt depression anteriorly. There are in this situation some prominent spicules of callus.

vertical section shows blocking of the upper half of the medullary cavity by indurated spongy tissue. There is no distinct septum of compact tissue.

Presented by Dr. Mütter.

1262.50- H.8. Right humerus. Oblique fracture
799 of the middle shaft. Union.
26
1

The fracture passed from the inner side obliquely downward and outward. The lower fragment lies on the inner side of the upper. The callus is smooth and the union strong. The head is much deformed by arthritis and is encircled by callus.

Presented by Dr. Mütter.

1262.52- Left humerus. Oblique fracture through
800 the head and shaft.
26
1

the posterior third of the head and upper shaft have been fractured and the fragment lost. One fracture line may be

traced throughout the entire shaft.

Presented by Dr.Mütter.

1262.54- Left humerus. Comminuted fracture of
801 the upper shaft. Union. (Plaster cast.)
24
1

The upper fragment has a length of 17 cm. The fracture is very oblique and passed from the inner side of the upper shaft downwards and outwards. Union is strong and the callus smooth.

H.B.Tuson,London,fecit.

Purchased.

1262.56- Left humerus. Fracture of the middle
802 shaft. United.
24
1

The fracture occurred exactly at the middle. There is slight outward bowing at this situation. The lines of insertion of the pectoralis major,latissimus dorsi and teres major constitute a prominent ridge. The uniting callus is strong and smooth.

Presented by Dr.Mütter.

1262.58- Left humerus. Fracture of the middle
804 shaft. Union.
25
2

The fracture occurred immediately above the middle. It has strongly united by callus,which is arranged in rough ir-

785

regular lines. There is a slight backward inclination of the fractured ends. The head has a small area of eburnation and on the inner side of the bicipital groove there is a depression with ridges of callus.

H.H.S.

Purchased.

1262.60- Right humerus. Oblique fracture of
805 the shaft. Union.
25
2.

The fracture occupied the entire middle third of the shaft. The lower fragment lies on the inner side of the upper and the fractured ends bow anteriorly; the deviation of the lower fragment amounts to 22o. Union is secure; the callus is smooth. There is a narrow fenestration in the callus on the outer side.
H.H.S.

Purchased.

1262.62 Left humerus. Oblique fracture of the
806 middle shaft. United. Longitudinal section.
25
2

Presented.

1262.64 Right humerus. Oblique fracture of
807 the shaft. Union.
25
2

The fracture passed from the anterior surface downward and backward through 9cm.

251 A-C
1049.75

of vertical extent. Union has occurred with slight irregularity of the callus.

vertical section shows a continuous medullary cavity, the irregularity in the compact tissue at the ~~seat~~ seat of fracture and periosteal deposit in the lower fragment.

Presented by Dr. Mütter.

1262.66- Left humerus. Fracture of the middle
808 shaft. Union.
25
2

The fracture is strongly united by smooth callus. There is backward displacement of the lower end of the lower fragment amounting to 24°.

Presented by Dr. Mütter.

1262.68- Left humerus. Fracture of the lower
809 shaft. Union with deformity.
25
2

The fracture occurred at the junction of the middle and lower third. Union has occurred by strong smooth callus, but with an inward and backward displacement of the lower end of the lower fragment amounting to 40°.

Presented by Dr. Mütter.

1262.70- Left humerus. Oblique fracture of the
810
25
2

lower shaft. Union. Arthritis of the shoulder-joint.

The fracturepassed from a point in the anterior surface 11cm. above the condyles, downward and backward through 5cm. of vertical extent. The fracture has united in good position. The callus is smooth, excepting on the inner side where there is a sharp ridge. The head near the greater tuberosity shows arthritis.

Presented by Dr. Mütter.

1262.72- Right humerus. Fracture of the lower shaft. Union.

The shaft was fractued close to the condyles and the fragments have united with some irregularity. The internal condyle has been drawn upward. The callus is strong. It presents a prominence above the external condyle. There is in the anterior surface of the callus a sinus of 1cm. diameter. The bicipital groove is wide and deep. Vertical section shows indurated spongy tissue at the seat of fracture.

Presented by Dr. Mütter.

1262.74- Right humerus. Fracture of the internal condyle and trochlea. Union with deformity.

251 A-C
1049.75

The internal condyle is drawn up. The lines of fracture are well-nigh obliterated. A prominent spine of callus is seen above the radial head. The articular surfaces are rough. The upper epiphysis has not united.

Presented by Dr. Mütter.

1262.76- Adjacent ends of the right humerus and ulna. Fracture of the internal condyle and trochlea. Union.

813
26
2

Owing to absorption, the articular surface has fallen in upon the inner side so that the measurement on the outer side is 2.5cm. greater than on the inner. The coronoid fossa is occupied by a pointed exostosis one centimetre long, directed downward and forwards and which fits into a corresponding cavity in the ulna. The latter bone was flexed at a right angle with slight motion and an inward lateral displacement. The radial head of the humerus is irregular but smooth. The coronoid and olecranon fossae communicate.
H.H.S.

Purchased.

1262.78- Right humerus. Fracture of the external condyle and radial head. Union.

814
26
2

The external condyle was fractured by a line passing to the inner side of the lesser head obliquely upward and terminating 5cm. above the joint. Union has taken place in excellent position, the articular surface presenting its proper appearance, excepting that the line of union in the articular surface is depressed and the lesser head does not present a smooth convex surface for the radius when flexed, but is marked by a vertical ridge, which, however, probably did not materially impair motion.
H.H.S.

1262.79 (A) Left humerus; Gunshot fracture Purchased. see Vol I Page 445
1262.79 (B) Right " " " see Vol. I Page 445

1262.80 H.18.5. Left humerus. Fracture of the external condyle and radial head. Union.

The line of union is marked by a depression on the inner side of the radial head. From this point, the fracture passed directly upward and outward, making the fragment 4cm. long. The convexity of the radial head has been turned to the inner side. The external condyle is prominent and is marked by an exostosis directed upward and outward. The union is strong.

Presented by Dr. Mütter.

1262.81 Right humerus; Gunshot injury see Vol I Page 446

251 A-C
1049.75

1262.82- Adjacent ends of the left humerus, radius and ulna. Fracture of the external condyle. Union with anchylosis of the elbow-joint.

816
26
2

The fragment of the condyle was about 4cm.long. It has united by smooth callus and with complete obliteration of the joint. The forearm is fixed in extreme extension and midway between pronation and supination. Dissecting room specimen.

1262.83 Left humerus; Gunshot fracture. Purchased. see Vol I Page 446

1009

1262.84- Left humerus. Transverse fracture of both condyles. Union with lateral displacement.

817
95
3

The bone is slender. The line of fracture passed transversely immediately above the joint. The lower fragment varies in thickness from one to two centimeters and has been displaced to the inner side so that the inner border of the trochlear surface falls immediately under the internal condyle. The internal condyle probably also formed a separate fragment. The union is strong; the internal condyle is prominent.

Presented by Dr.Mütter.

1262.85 Right humerus; Gunshot fracture. see Vol I Page 445

1007

1262.86- Upper half of left humerus. Commi- in case with bullet fracture
818 nuted gunshot fracture.
20
3

The fracture was caused by a conoidal ball. Eight fragments belonging to the upper shaft remain. A number are missing from the posterior side.

Presented by the Surgeon General, U.S.A.

1262.87 Left humerus; Gunshot fracture. See Vol I Page 445

1262.88- Lower half of left humerus. Commi-
819 nuted gunshot fracture of the lower shaft.
20
3

Five fragments remain. A number are missing from the anterior portion of the shaft.

From a soldier who underwent primary amputation.

Presented by the Surgeon General, U.S.A.

1262.89 Left humerus; Gunshot fracture. See Vol I Page 445

1262.90- Lower third of left humerus. Commi- in case with bullet fracture
820 nuted gunshot fracture of the shaft. Co-
25 noidal ball in situ.
3

Four fragments remain. The ball, which is much battered, lies on the outer and anterior aspect of the shaft.

From a soldier who underwent primary amputation.

Presented by the Surgeon General, U.S.A.

251 A-C
1049.75

1262.91- Adjacent ends of the bones of the left elbow-joint. Gunshot fracture of the external condyle, trochlea and olecranon. Recent.

in case with bullet fracture

The fracture passes close to the outer border of the trochlea and a large part of the outer side of the posterior portion of the expanded surface has been broken off. The olecranon has been fractured by a line passing near the upper end of the radial margin obliquely downwards below the inner condyle.

From a soldier who underwent primary amputation.

Presented by the Surgeon General, U.S.A.

1262.92- Adjacent ends of the bones of the right elbow-joint. Gunshot fracture of the shaft, internal condyle and radial head of the humerus and the coronoid process of the ulna.

in case with bullet fracture

The trochlea and internal condyle are missing. The shaft was fractured in a line passing from a point on the outer margin 6cm. above the radial head, obliquely downward and inward. The radial head was fractured in a line passing transversely through its middle and thence directly through the external condyle. The fragment of the coronoid process is 4cm.

long and embraces the anterior portion of the articular surface of the sigmoid cavity.

From a soldier who underwent primary amputation.

Presented by the Surgeon General, U.S.A.

1262.93- Lower shaft of left humerus. Fracture above the condyles. Recent.

The line passes from above the internal condyle downward obliquely to the middle, then transversely to the outer side.

H.H.S.

Purchased.

1262.94- Lower third of left humerus. Comminuted fracture of the shaft; intercondyloid. Recent. (Plaster cast.)

The shaft is broken nearly transversely 5cm. above the joint. The plane of fracture passes slightly obliquely from before downwards and backwards. The lower fragments are divided by a line passing vertically at the junction of the radial head and trochlear surface.

H.B. Tuson, London, fecit.

Purchased.

1262.95- Adjacent ends of left humerus, radius and ulna. Fracture of both condyles.
825
25
3
Recent.

The Bones are from a young child. From the outer portion of the trochlear surface two lines pass; one of them directed obliquely upwards and outwards, terminates 4cm. above the external condyle; the other terminates on the upper margin of the internal condyle. The cartilage was not fractured.

Presented.

1262.96- Lower third of right humerus. Fracture of the shaft. Recent.
826
25
3

The fracture was doubtless caused by direct violence, as by gunshot. The outer part of the expanded portion of the shaft has been carried away, producing greater destruction on the posterior surface. The bone is young.

Purchased.

1262.97- Left humerus and ulna. Fracture of the lower shaft. Union with anchylosis of the elbow-joint.
829
26
3

in conjunct bullet fracture

The fracture occurred immediately above the condyles, but it is difficult to say whether it passed into the joint.

1262.99. Fracture of elbow joint
Dr. G. L. Davis
828
25
3.

1262.991 Humerus. Fracture united
Presented by Prof. George McClellan

1262.100 Humerus – Gunshot fracture;– ununited.
Presented by Dr. John H. Brinton.

1262.101 Humerus;– fracture of the neck;– united.
Presented by Dr. John H. Brinton.

Union has occurred with strong and, in places, irregular callus. The two bones are anchylosed at a right angle. The olecranon fossa is filled by a mass of callus falling from the seat of fracture, but communicates with the coronoid fossa, in which the extended coronoid process of the ulna is imbedded. Upon the outer border of the olecranon is a mass of callus having a concavity upon the outer side. This callus is more prominent than the true olecranon.

Presented by Dr. Mütter.

1262.98– Bones of the right upper extremity.
827
25
3
Intercondyloid fracture of the humerus.
Union.

in case with bullet fracture

The bones are from a powerful adult. Both condyles were separated from the shaft and they have united with interval displacement, widening of the intercondyloid space and extreme prominence of the internal condyle. There is also a ridge of callus anteriorly above the condyles. The radial head has become concave corresponding to the convex head of the radius. Motion at the elbow was doubtless slightly impaired. All the ligaments connected with the specimen have been preserved.

Presented by Dr. Mütter.

251 A-C
1049.75

1266- Left humerus. Interstitial absorption of the head and anatomical neck.

The articular surface of the head has been absorbed to a large extent at its periphery. The anatomical neck is thus lengthened, having a length of 3cm. on its posterior surface and being marked anteriorly by spherical depressions. The bicipital groove is broad and deep. changes due to the process of absorption. H.P.S.

Purchased.

1266.1a- Right humerus. Probably an old dislocation. Absorption of the head.

The articularity of the head is greatly damaged. The head was atrophied and is marked by a deep incantation on its upper and posterior surface. Immediately above the greater tuberosity, there is obliteration and evidence of a change in the opposite articular surface, suggesting dislocation.

Purchased.

1266- Upper half of left humerus, [illegible] of the stump.

The separation of the epiphysis [illegible] term is nearly complete. An [illegible]

1266- HUMERI.

1307- RADII.

1263. ~~Resection of humerus ununited fracture 1859~~
Presented by Dr John H. Brinton.

1263.05 False joint of humerus of man. Excised by Dr. John H. Brinton
1885 cure.
Presented by Dr. John H. Brinton.

1266- Left humerus. Interstitial absorption
830 of the head and anatomical neck.
26
3

The articular surface of the head has been absorbed to a large extent at its periphery. The anatomical neck is thus lengthened, having a langth of 3cm. on its posterior surface and being marked anteriorly by spherical depressions. The bicipital groove is broad and deep, changes due to the process of absorption.
H.H.S.

Purchased.

1266.10- Right humerus. Probably an old dis-
831 location. Absorption of the head.
26
3

The upper extremity of the bone is greatly changed. The head has atrophied, and is marked by a deep indentation on its upper and posterior surface. Immediately above the greater tuberosity, there is ebunation and evidence of a change in the opposite articular surface, suggesting dislocation.

Purchased.

1268- Upper half of left humerus. Necrosis
832 of the stump.
26
3

The separation of the central sequestrum is nearly complete. An involucrum

has been formed, open posteriorly but marked by a very irregular fenestrated surface.

Presented by Dr. Mütter.

1268.05- 833 Upper half of the humerus. A stump. Found.
26
3
caries.

1268.10- 834 Right humerus and portions of the
26
3
ulna and radius. Necrosis of the humerus and secondary fracture.

The head of the humerus is not present. The entire shaft and lower extremity are involved in general necrosis. No well defined sequestrum and involucrum are present. The shaft is enlarged, rough, very irregular, porous and friable. Smooth compact tissue is not seen. The entire shaft seems to have been transformed by new bone deposit. At the middle of the shaft there is an ununited fracture.

From a man aet. 37, an accountant. At the age of 12, after the receipt of an injury and exposure to cold, he was attacked with fever and very painful swellings of the right shoulder-joint, which was followed by suppuration and discharge of dead bone, and anchylosis at the shoulder

251 A-C
1049.75

813

251 A-C
1049.75

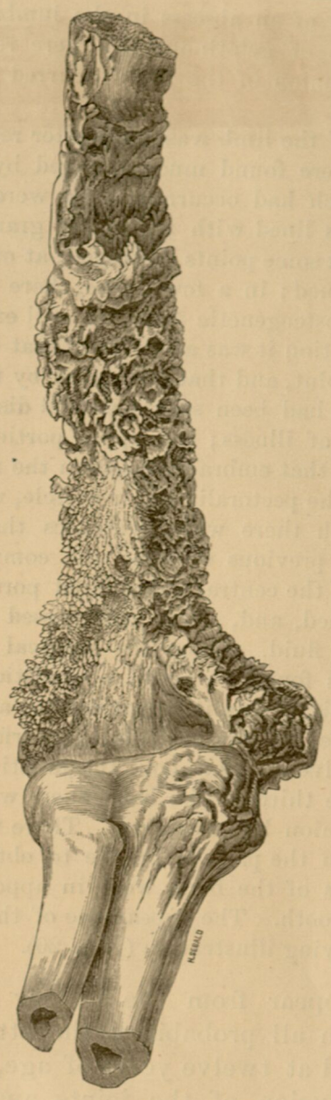

NECROSIS OF HUMERUS.

815

and elbow. At the age of 37, he strained his arm in lifting a heavy box. This was followed by swelling, fever, suppuration, and the discharge of bone. During this illness, he sustained fracture in an effort to raise his body in bed.

A successful amputation was performed by Dr. Mears, August 1st, 1876 for necrosis.

Presented by Dr. J. Ewing Mears.

Trans. Coll. of Physicians Phila., 3rd series, Vol. lll. p. 17-21-1876

1269-835 25 4

Left humerus and ulna. Hypertrophic ostitis of the humerus and anchylosis of the elbow-joint.

in case with bullet fractures

The humerus is thickened except at the upper extremity. Its surface is firm but rough. Three centimeters above the olecranon fossa there is a sinus having a diameter of 1cm. The elbow-joint is obliterated. There is no radial head, but a lesser sigmoid cavity of large size for the radius.

Presented by Dr. Mütter.

1269.02-836 25 4

H.49. Right humerus, radius, and ulna. Ostitis of the humerus. Anchylosis of the elbow-joint.

in case with bullet fractures

The humerus is thickened and pre-

sents on its posterior and outer border two long sinuses. The olecranon fossa is large. A broad osteophyte projects from its inner margin. The elbow-joint is obliterated. The forearm is flexed at an angle of 112° and the wrist isfixed midway between pronation and supination. There may have been in this case a fracture of the condyles of the humerus, but it is difficult to say positively.

Dissecting room specimen.

W.S.F.

Purchased.

1269.04- Upper third of right humerus. Arthritis deformity of the head. Eburnation.

837
25
4

The changes in this specimen may have been the result of luxation, but were probably not the result of fracture. At any rate, intense arthritis existed, followed by deposit of callus upon the surface of the head with eburnation of its posterior surface, a prominence and flange-shaped form of the greater tuberosity, indentation of the bicipital groove and fringed borders of the entire articular surface.

Purchased.

251 A-C
1049.75

1269.06- Left humerus, radius and ulna. Arthritis of the elbow-joint.
838
26
4

All the articular surfaces are rough and their margins are marked by thick growths of callus. The radial head of the humerus is large. The olecranon and coronoid processes of the ulna are large and the greater sigmoid cavity is deep and narrow.

Presented.

1269.08- Left humerus, radius and ulna. Arthritis with eburnation.
839
26
4

The lower articular surface of the humerus is greatly changed. A large plate of callus having a thickness of 1cm. covers the lower end of the bone. The greater sigmoid cavity of the ulna is very large and broad. The head of the radius is convex. All these articular surfaces are beautifully eburnated.

Dissecting room specimen.
W.S.F.

Purchased.

1269.10- Left humerus, radius and ulna. Arthritis.
840
26
4

The articular surfaces of the elbow-joint are all rough and their borders are

251 A-C
1049.75

thickened by deposit of callus. The head of the humerus is enlarged and the lesser sigmoid cavity of the ulna is larger than usual.

Purchased.

1269.12- Right humerus. Arthritis and exostosis of the head.

841
26
4

The head is encircled by a rough and heavy collar of callus, which is more prominent on its anterior and inner border. The bicipital groove is deep. The bone is slender.

Presented by Dr. Mütter.

missing

1269.14- Left humerus. Arthritis of the head.

842
25
4

The line of insertion of the capsular ligament is marked by a prominent circle of callus. The entire surface of the head is rough.

missing

Vertical section shows some thickening of the compact tissue of the shaft.

Presented by Dr. Mütter.

1269.16- Left humerus. Exostosis of the lower shaft.

843
25
4

Nine centimeters above the elbow-joint on the inner and anterior aspect an

exostosis is seen, having a length of 1cm. and directed downward and inward.

Presented by Dr. Mütter.

1269.17 Humerus Exostosis.

Presented by Prof George McClellan

1269.18- Left humerus. Arthritis of the elbow-
844
25
4 joint.

The callus hangs from the radial side and is seen chiefly on the external border, suggesting ossification of the lateral ligament. The articular surface is rough.

Presented by Dr. Mütter.

1269.20- Left humerus. Ostitis of the lower
845
25 end.
4

The entire lower third of the bone is involved. The surface is rough, porous, friable and thickened. The articulation is tolerably well preserved. The disease is seen on the posterior and outer surface.

Presented by Dr. Mütter.

1269.22- Right humerus. Ostitis of the lower
846
25 shaft.
4

In the lower shaft there is an area of ostitis in which is seen on the posterior surface softened bone tissue and a sequestrum in process of separation. The outer border of this area is marked

251 A-C
1049.75

by periosteal deposit.

Presented by Dr.Mütter.

1269.24- Left humerus. Ostitis of the lower
847 extremity.
25
4 The lower third of the bone is deeply involved. Its anterior and posterior surfaces are rough, fenestrated and carious.

Presented by Dr.Mütter.

1269.26- Right humerus. Ostitis of the lower
848 extremity.
25
4 The insertion of the capsular ligament is deepened; the bicipital groove is well marked. The lower fourth of the bone is marked by loss of substance toward the extremity with nearly total loss of articular cartilage. The olecranon depression is enlarged, roughened and fenestrated. The radial head and trochlear surface are well nigh obliterated.

Presented by Dr.Mütter.

1269.28- Right humerus. Arthritis of the el-
849 bow-joint.
26
4 The articular surface is rough and presents a spongy appearance. The internal condyle is marked by short osteophytes.

presented by Dr.Mütter.

1269.30- Left humerus. Periostitis of the lower shaft.

850
26
4

The disease is situated chiefly on the inner and anterior aspects of the lower shaft. The bone is rough, abounds in fine vascular channels and is considerably enlarged. The diseased area embraces about 10cm. of the shaft.

Presented by pr.Mütter.

1269.31- Right humerus. Hypertrophic ostitis.

851
25
5

Presented by Dr.Mütter.

1269.32- Right humerus. Ostitis, necrosis, periostitis.

852
25
5

The inner portion of the lower extremity is involved. The articular surface is intact. The internal condyle is small and above it for a space of 9cm. the bone is rough, presenting numerous vascular openings and deep irregular channels. Posteriorly and below layers of periosteal deposit, there is a sequestrum in process of separation.

Presented by Dr.Mütter.

1269.34- Right humerus. Hypertrophic ostitis.
& 1263

853
25
5

The bone is heavy and its surface

Cross index no. should not be on specimen

251 A-C
1049.75

rough and marked by shallow vascular channels on the posterior surface and inner border.

Vertical section shows great hypertrophy of the compact tissue and spongy tissue of normal character occupying the medullary canal.

Presented by Dr.Mütter.

1269.36- H.41. Right humerus, Hypertrophic
& Cross index no. & should not be on specimen
1263.10 ostitis.

854
26
5

The bone is heavy, its surface is irregular and rough, and is marked chiefly in its lower half by shallow vascular channels coursing in all directions over the inner and posterior aspects of the bone. The olecranon depression is nearly filled with osteophytes. The coronoid depression is small and its surface is rough.

Vertical section shows hypertrophy of the compact tissue and the upper medullary cavity free.

Presented by Dr.Mütter.

1269.38- H.42. Left humerus, Hypertrophic os-
&
1263.20 titis. Central necrosis, Retained sequestrum.

855
26
5

The shaft is greatly enlarged and

Cross index no. and should not be on specimen

its weight increased. The surface is rough and marked by vascular channels. The olecranon depression and coronoid and radial depressions are encroached upon by the overgrowth of bone. Above the radial head, there is a sinus 5 mm. in diameter. The head of the bone looks small in comparison with the thick shaft.

vertical section reveals the beautiful appearance of general necrosis. The original compact wall has died, has been completely enclosed by the new thick compact walls and itself incloses healthy spongy tissue. The sequestrum is partly loose. It has been sawn vertically.

H.H.S.

Purchased.

1269.40- Right humerus. General ostitis and periostitis.

856
25
5

The surface of the bone is rough and the walls are thickened by periosteal deposit upon the posterior and inner sides of the bone.

Vertical section shows the superposition of periosteal layers. The medullary cavity is free.

Presented by Dr. Mutter.

251 A-C
1049.75

1269.42- Left humerus,radius and ulna. Arth-
857 ritis.
25
5

The articulation is not so extensively affected as in the preceding cases,but the radial head of the humerus is atrophied and roughened and the head of the radius is fringed with callus and its extremity flattened.

Purchased.

835

251 A-C
1049.75

dius and ulna. Arthritis.

The articulating surfaces are rough and the borders are thickened. There has been a thick deposit of callus over the entire joint. This renders the greater sigmoid cavity of the ulna large and the coronoid process prominent.
H.H.S.

Purchased.

1269.46- Adjacent ends of right humerus, radius and ulna. Arthritis.
859
26
5

The joint has been only slightly involved; the deposit is seen chiefly at the margins of the articulation. The olecranon and coronoid fossae are separated by a thin membrane.
H.H.S.

Purchased.

1269.47- Humerus and ulna. Hypertrophic ostitis; syphilitic.
860
25
5

This is probably syphilitic. The ulna is particularly round and thickened.

Presented.

1269.48- Adjacent ends of the right humerus, radius and ulna. Arthritis.
861
26
5

The articular surfaces are rough and the margins are thickened with a moderate

amount of callus.
W.H.S.

Purchased.

1269.50- Lower third of right humerus with
862 the radius and ulna. Arthritis.
25
6

The callus is exuberant;a large mass slightly eburnated covers the lower end of the humerus;another mass extends from the coronoid process of the ulna;another fringes the head of the radius. The interosseous ligament has been preserved.

It is possible that in this case the callus is the result of fracture of one or both of the bones of the forearm at the elbow-joint.
H.H.S.

Purchased.

1269.52- Adjacent ends of the left humerus,
863 ulna and radius. Caries of the elbow-joint
25 with periostitis.
6

The expanded portion of the humerus has been lost by caries,so that the inferior extremity of the humerus is the lower shaft. The medullary canal is not open,but it and the adjacent compact tissue are covered with periosteal deposit. The ulna is changed so that there is no greater sigmoid cavity and only a rough surface for the head of the radius.

251 A-C
1049.75

There is no coronoid fossa. The ends of the bones are covered with periosteal deposit.

Presented.

1269.56- Adjacent ends of the left humerus, radius and ulna. Arthritis.

864
25
6

The bones are small and the compact tissue is thin. The articular surfaces are rough. The greater sigmoid cavity is marked by a prominent ridge and thin borders. The head of the radius is atrophied. H.H.S.

Purchased.

1269.58- Adjacent ends of the left humerus, ulna and radius. Ostitis. Arthritis.

865
25
6

The bones are thickened, rough, porous and friable. The disease extends from seven to nine centimeters above and below the joint. The articular surfaces are devoid of cartilage and spongy tissue is seen.

Presented by Dr. Mütter.

1269.60- Adjacent ends of the left humerus, radius and ulna. Arthritis.

866
26
6

The bones are well developed and the arthritis is not extensive. There is de-

251 A-C
1049.75

posit of callus in the olecranon fossa and over the whole extent of the articular surfaces of the joint. The deposit is 5 cm. in thickness. The coronoid process is large. The head of the radius is nearly normal.
W.H.S.

Purchased.

missing

1269.62- Adjacent ends of left humerus, radius and ulna. Arthritis.

867
26
6

The articular surfaces are covered with a rough arthritic deposit.
W.H.S.

Purchased.

1269.64- Specimens from a case of excision of the elbow-joint for caries and arthritis.

868
26
6

There is an area of caries having a diameter of nearly 1cm. situated on the inner side of the greater sigmoid cavity. The specimen from the humerus is 1cm. thick on the outer side and 5cm. thick on the inner side; that from forearm embraces both sigmoid cavities and 5cm. of the diaphysis of theradius.

Removed by Dr. John Ashhurst, from a patient aet, 4 years in the Children's Hospital, Philadelphia.

Presented by Dr. Ashhurst.

1269.66- Adjacent ends of the right humerus, radius and ulna. Arthritis.

869 26 25 6

The articular surfaces of the humerus and ulna are comparatively smooth not withstanding considerable thickening by callus. The coronoid process of the ulna is prominent.
H.H.S.

Purchased.

1269.68- Adjacent ends of the right humerus and ulna. Arthritis.

870 25 6

The surfaces of the joint are rough and from the margins numerous spiculated osteophytes spring. The greater sigmoid cavity is long. Motion was meagre. Above the condyles there is some thickening of the margin of the humerus.
H.H.S.

Purchased.

1269.70- Left humerus and ulna. Anchylosis at the elbow.

871 25 6

The bones are firmly co-ossified at an angle of 95°. Thecallus is smooth and of long standing.

Presented by Dr.Mütter.

1269.72- Right humerus, radius and ulna. Anchylosis.

872 26 6

The joint is obliterated and the bones are co-ossified. The union was not

in case with bullet fractures

so strong, however, as to have presented an accidental fracture after mounting. The callus is rough and brittle. The radius and ulna are united for the space of 3cm. near the joint. The forearm is fixed at an angle of 130°.

Presented by Dr. Mütter.

1269.74- Adjacent ends of the left humerus and ulna. Anchylosis.

The two bones are co-ossified at an angle of 80° and with a slight inward displacement of the ulna. The surface over the joint is perfectly smooth. There is a depression in the humerus for the head of the radius, but near the outer border of this depression, there is an eminence of callus.

H.H.S.

Purchased.

1269.76- Adjacent ends of right humerus, radius and ulna. Anchylosis of humerus and ulna.

The forearm was fixed at a right angle. A certain amount of rotation was doubtless preserved. The radial head of the humerus has been changed into a deep pit for the radius. This cavity presents

numerous osteophytes at its outer border.
H.H.S.

Purchased.

1269.78- Adjacent ends of the right humerus and ulna. Anchylosis of the elbow-joint.

874
26
6

A layer of bone deposit has been extended from the margins of the articulation over it. This is noticeable anteriorly where this thin deposit rises from the coronoid process upward to the coronoid fossa. Some fragments have been broken away and it is possible to see the smooth articular surface below. The lesser sigmoid cavity of the ulna and the radial head of the humerus are rough. The bones are fixed at an angle of 130°.

1269.80- Adjacent ends of left humerus, radius and ulna. Anchylosis of elbow-joint following traumatic arthritis.

875
25
6

The humerus and ulna are co-ossified; the radius can rotate. The lower end of the humerus is thickened, its surfaces are rough, especially so above the condyles. The olecranon fossa is large and its walls are rough. The coronoid fossa is obliterated. The radial head of the humerus is

251 A-C
1049.75

smooth. The olecranon is massive;there is rough irregular bone at the most prominent portion of the elbow.

Case of Michael C.,aet.50,a coal miner. In 1867 he was struck on the left elbow by coal from a blast. Anchylosis followed and the olecranon was exposed on a level with the skin for about 1 sq.c.m. Six months later there was inflammation followed by abscess. In December 1875,the same arm was squeezed between a coal wagon and heavy timber. Diffuse inflammation followed from the elbow,down,with swelling and abscess. The patient enteredSt.Mary's Hospital Philadelphia,October 18th 1876. No dead bone was detected on probing. Slight power of pronation existed,but no flexion. A short effort was made to save the limb,but amputation at the middle of the humerus was resorted to. The ligature of the brachial artery remained forty days and was then removed in two days by attaching a bag of shot.

The remainder of the member,exhibiting diffuse cellulitis of the forearm and hand,is mounted in alcohol and is labeled. #6095.00

Presented by Dr.W.W.Keen.

851

251 A-C
1049.75

? Missing

1269.82- Adjacent ends of the left humerus, radius and ulna. Anchylosis of the three bones.

The joint is totally obliterated. The forearm was fixed midway between pronation and supination and in a position of full extension.

Purchased.

1269.84- Adjacent ends of the right elbow-
876 joint. Caries and anchylosis.

The specimen has been preserved with a number of the ligaments of the joint. The humerus, above the condyles, is rough. The head of the radius is missing and has probably been destroyed by caries, allowing the shaft to ride up and point toward the coronoid fossa. Viewed through an opening in the bursa of the olecranon, the articulation seems to be in a state of caries.

Presented by Dr. Mütter.

1269.85- Adjacent ends of left humerus, radius
877 and ulna; necrosis.

Both condyles of the humerus and the head of the radius are necrosed.

Presented by Dr. A. Sydney Roberts.

1270- Right humerus. Curvature.
878

The bone is only 9cm. long. It bows outward at the middle, giving a deviation of 30°. The epiphyses are partly preserved.

Presented by Dr. John Neill.

1273- Left humerus. Osteo-sarcoma.
879

The disease involves the head and

1274. Humerus, - child - non union of the epiphysis Presented by Dr. John H. Brinton

1274.05 " " " " " " " " " " " "

1274.10 Resection of humerus " " " " " " " " " " " "

1274.15 Humerus. - False joint. Excised by Dr. Brinton, 1885. Cure. Presented by Dr. John H. Brinton

upper shaft, which present a diameter of about 15cm. The greater portion of the articular surface of the head remains intact. The growth has been laid open on the inner side and is held within a fibrous envelope. The tumor is a firm, solid, structureless mass, bearing no gross resemblance to either compact or spongy tissue. The lower two thirds of the shaft is intact.

Presented by Dr. Mütter.

1277- 888 87 2 Radius 1. Bones of the right upper extremity. Fracture of the radius. Union. Anchylosis with the ulna. in case with bullet fractures

The humerus was sawn at its middle and all the ligaments of the part have been preserved. The fracture occurred just above the middle of the radius. Callus was thrown out toward the ulna, uniting the two bones. The lower fragment projects slightly in front of the upper.

Presented.

1277.05- 978 28 3 Radius 2. Adjacent ends of the right humerus, radius and ulna. Gunshot fracture of the radius. in case with bullet fractures

The radius was comminuted at its upper end by a conoidal musket ball, which

251 A-C
1049.75

has been distorted and is hung in pos tion. The head and neck of the humerus were shattered, the anterior portion of the head having been carried away. Vertical lines of fracture run along the anterior and posterior surfaces of the shaft. The surfaces of all the bones are of a gray color due to consequent inflammation.

From a soldier who underwent secondary amputation of the arm.

Presented by the Surgeon General U.S.A.

1277.10- Radius 3. Left humerus, radius and ulna. Fracture of the neck of the radius. Union.

976
27
3

This is a rare fracture. It occurred immediately below the head of the radius and has united with posterior displacement of the head, permitting its anterior margin to articulate with the radial head of the humerus, forming in the radius a new articular surface, smooth and of slight concavity. The displacement backward produces a slight angle at and above the tubercle. A small exostosis is seen on the anterior margin of the lower articular surface of the ulna.

Presented by Dr. Mütter.

859

251 A-C
1049.75

1277.15- Upper third of left radius. Oblique fracture of the neck. Union.

The fracture extended from the anterior surface midway between the tubercle and the superior articular surface of the head, downward and backward to a point in the posterior aspect 5cm. from the upper extremity. Union has occurred in good position, but with atrophy of the head. The superior articular surface contains a large depression and the lateral surface for rotation on the ulna is atrophied and practically a mere ridge.
H.H.S.

Purchased.

1277.20- Left radius. Double fracture of the neck and lower end. Recent.

The upper fragment has a length of from 1cm. to 1.3cm., the line having passed transversely below the epiphyseal junction, the latter being ossified in this specimen. The lower end was crushed immediately above the junction of the apiphysis which has not united and which is intact. The lower fragment is regular and is fractured transversely.
H.H.S.

Purchased.

251 A-C
1049.75

1277.24- Radius; oblique fracture above the
890 middle. Union.
27
1

Picked up in an ancient graveyard, Honolulu, Sandwich Islands by Dr. J.M. Whitney.

Presented by Dr. Mears.

1277.25- Left radius. Oblique fracture above
891 the middle. Union.
27
1

The shaft was fractured above the middle. Union has occurred with outward displacement of the fractured ends and anterior overlapping of the lower fragment. The latter presents a sharp joint directed upward. The uniting callus is smooth and firm. The upper fragment has been rotated slightly outwards.

1277.30- Right radius and ulna. Oblique fracture of the lower shaft of the radius.
892 Union.
27
1

The fracture started from a point on the inner border 7cm. from the wrist-joint and passed obliquely downward and to the outer side 6cm. from the styloid process. Union has occurred in good position with a minimum amount of smooth, strong callus.

Presented by Dr. Mütter.

1277.35- Left radius, Transverse fracture of
893 the lower end. Union. (Colles')
27
1

The fracture passed from a point on the outer side 3cm. above the styloid process to the inner margin 1.5cm. above the joint. Anteriorly a small but well defined transverse ridge marks the union. Posteriorly there is a slight exostosis.

Presented by Dr. Mütter.

1277.40- Left radius, Transverse fracture of
894 the lower end. Union. (Colles'.)
27
1

The fracture approached within 1cm. of the outer portion, and within 1.5cm. of the inner portion of the joint. The lower fragment was displaced slightly posteriorly and has united in that position with a slight amount of permanent callus.

Presented.

1277.45- Comminuted fracture of the lower end of radius
983 involving the joint. Union.
27
4

The fracturepassed from a point 3cm. above the styloid process to a point on the inner side 1.5cm. from the end. The lower end was also fractured into three pieces, viz., the two lateral portions of the articular surface and the posterior lip. The fractures have all united. Below

984
27
4
1397.03211

Head of left femur, showing muscular (?) fracture of greater trochanter! Union

See Pg. 1012 Vol. I.

the anterior transverse fracture line, there is a depression due partly to a slight posterior displacement of the lower fragment and to absorption from contact with the bursa. The fractures of the facettes and posterior lip of the articular surface are marked by slight elevations of bone.

Dissecting room specimen.

Purchased.

1277.50- Left radius. Comminuted fracture of the lower end involving the joint. Union.

-912
28
2

The lower end of the bone has been greatly changed. There was doubtless a transverse fracture close to the joint and subdivision of the articular surface by one or more vertical lines. Union has occurred with slight absorption of the fragments. The lower end is marked by a deep and narrow fissure dividing it into a smaller ulna and larger external portion. The line of the transverse fracture is marked by a slight elevation of bone.

Is it not possible that portions of the carpal bones are anchylosed to lower end of radius?

Vertical section shows induration of the spongy tissue about the joint, but no definite line.

Dissecting room specimen.

Purchased.

251 A-C
1049.75

1277.55- Rad.10. Lower end of right radius
987 and ulna. Transverse fracture of the lower
28
4 end of the radius. Union.

The fracture passed close to the joint. Measuring the fragment which has been sawn vertically in the antero-posterior line, it is seen to vary from .5cm. to 1cm. in thickness and the fracture is well-defined by a distinct band of indurated spongy tissue.

Dissecting room specimen.
H.H.S.

Purchased.

1277.60- Rad.11. Lower end of right radius and
981 ulna. Transverse fracture of the lower end
~~28~~
27
4 of the radius, Union.

The fracture passed, on the posterior surface, within 1.7cm. of the joint. Anteriorly it probably passed a little closer. Union has occurred with a slight anterior displacement of the lower fragment.

Vertical section shows induration of the spongy tissue of the lower end.
H.H.S.

Purchased.

1277.65- Bones of right forearm and hand. Ob-
979 lique fracture of the lower end of the ra-
28
3 dius, involving the joint. Union. Barton's

251 A-C
1049.75

fracture(?)

The lower fragment embraces the styloid process, the outer portion of the articular surface and 1.5cm. of the external border. Absorption and upward displacement of the lower fragment allowed the hand to be carried away from the ulna. Union has occurred with a slight amount of callus; the bone is smooth anteriorly, but is marked by an oblique groove posteriorly.
H.H.S.

Purchased.

1277.70- Bones of right forearm and hand. Transverse fracture of the lower end of the radius involving the joint. Union. Barton's fracture.

The lower fragment has a length, upon the posterior surface, of 2cm. and embraces about one third of the posterior portion of the articular surface of the radius. Anteriorly the bone is bent backward but not fractured and there is slight roughening as though from the action of the bursa. The uniting callus presents a somewhat irregular appearance on the posterior portion and the deformity was doubtless of the "silver fork" character, owing to the posterior displacement.
H.H.S.

Purchased.

251 A-C
1049.75

1277.75- Rad.14. Lower end of the left radius.
899 Comminuted gunshot fracture of the lower
28 end involving the joint. Recent.

The specimen consists of three fragments. The upper one, a small portion of the shaft shows an oblique fracture. The lower end was split vertically between the two facettes, the bone being divided exactly in the median line. Between the shaft and the lower end many comminuted fragments have doubtless been lost.

From a soldier, aet.24, wounded in the battle of Antietam 1862, and admitted to the Patent Office Hospital, Washington under the care of Dr.C H.Boardman. The ball had laid open the joint, stripped the periosteum from the fractured extremities of the radius and disclosed the vertical fracture in the articular surface. The patient, a well-made, powerful man, refused to undergo amputation. Pus soon burrowed freely through the surrounding tissues and drainage was provided for profuse discharge. The general health soon becoming greatly impaired, he consented to an exsection, but would not allow an amputation, the only operation at that time which would have availed. The removal of the bones produced only temporary relief. The arm was subsequently amputated by Dr.Jamar and the

251 A-C
1049.75

patient finally died.

Presented by Dr.C.H.Boardman.

1277.78- Lower end of the left radius and ul-
989 na. Oblique fracture of the lower end in-
28 4 volving the joint. Recent.

The lower fragment embraces the styloid process, 2.5cm. of the external border and all of the articular surface except a narrow strip upon the ulnar side.

The fracture was produced in the dead subject by extreme extension of the hand.

Presented by Dr.John H.Packard.

1277.80- Lower end of the left radius. Oblique
988 fracture of the lower end involving the
28 4 joint. Recent.

The lower fragment embraces the styloid process, 1.5cm. of the outer margin of the bone, the outer facette of the articular surface and the anterior border of the latter.

The fracture was produced in the dead subject by extreme extension of the hand.

Presented by Dr.John H.Packard.

1277.82- Radius 17. Lower half of left radius.
969 Comminuted fracture of the lower end in-
28 2

875

251 A-C
1049.75

volving the joint. Recent.

This and the following specimen are from the same subject, a young man. The epiphysis was separated from the diaphysis. The former was broken into five fragments, each forming a portion of the articulation. One comprises the posterior lip; two others the outer border; another the styloid process and outer half of the anterior border; and the fifth the anterior portion of the inner facette. The styloid process was fractured vertically.

From a youngpainter who fell while painting the outside of a window and died at St. Joseph's Hospital within forty-eight hours of concussion of the brain and spinal cord. Previous to the removal of the specimen, the fractures of the articular surface were not suspected, but from the sensation conveyed through the anterior radio-carpal ligament, transverse fracture of the shaft, low down but not involving the joint, was suspected. The fracture was doubtless produced by receiving the blow directly on the carpus.
H.H.S.

Purchased.

1277.84- Lower end ofthe right radius. Comminuted fracture of the lower end involving

990
28
2

251 A-C
1049.75

the joint. Recent.

This is from the same subject as was the preceding specimen. The diaphysis was separated from the epiphysis. The latter was extensively comminuted and many of the anterior fragments were lost. The styloid process was fractured transversely.

The fracture was doubtless caused by receiving the force in the same way as in the preceding case.
H.H.S.

Purchased.

1277.86- Lower end of the left radius. Comminuted fracture of the lower end involving the joint. Union.

990
28
4

The line of fracturepasses on the anterior surface from a point 2cm. from the styloid process, transversely across to the ulnar side within .5cm. of the end of the bone; it then transverses the facette for the ulna divides the posterior and ulnar position ofthe articular surface, reaching the posterior lip where its direction is lost in the callus. Posteriorly there is a line of fracture crossing at about 1.5cm. from the joint, being the point of a re-entrant angle formed by the posterior displacement of the fragments. Anteriorly the deformity is an abrupt one.

251 A-C
1049.75

Union has occurred with little superabundant callus.

Presented.

1277.88- Bones of left forearm and carpus.
895
27
1

Gunshot fracture of the lower end of the radius. Union with anchylosis of the wrist-joint.

The battered form of what was probably a round ball lies embedded in the ulnar side of the lower end of the radius. The lower end of this bone was fractured obliquely;one of the fragments embracing the styloid process had a length of 7cm; two other fragments embraced portions of the posterior lip,they are separated from each other by fenestrations. The scaphoid semilunar,magnum and cuneiform are cohossified with the forearm and with each other. The forearm was fixed midway between pronation and supination.
H.H.S.

Purchased.

1282- Left radius. caries of the head and
900
27
2

hyperostosis of the upper shaft.

The head has been nearly destroyed. The entire upper shaft isthickened and its surface is irregular and finely porous. There has been periostitis. The lower

251 A-C
1049.75

shaft is unaffected.

Presented by Dr.Mütter.

1282.05- Right radius. Caries of both extremities with exostosis of the shaft.

The spongy substance of the head is visible on all sides and on the superior surface there is a cavity. On the ulnar side of the articular surface there is a small carious opening. Along the insertion of the interosseous ligament there are osteophytes.

Presented by Dr.Mütter.

1282.10- Left radius. Caries of the lower end.

The lower end of the bone is rough and the seat of superficial caries, chiefly noticeable posteriorly.

Presented by Dr.Mütter.

1283- Left radius. Necrosis and hyperostosis of the shaft.

The upper shaft is thickened, its surface is rough and porous; on the ulnar side there is a cavity leading toward the center of the bone, and through an opening in the posterior surface a sequestrum is seen firmly embedded in the interior.

Presented by Dr.Mütter.

251 A-C
1049.75

1283.10- Left radius. Central necrosis.
904
27
2

The shaft is enlarged; its surface is rough, covered with minute openings and traversed by vascular grooves; the compact wall is thick, especially in the middle shaft.

Vertical section reveals a large sequestrum consisting of the original compact tissue, having a length of 9cm. and occupying a central position. It has no communication with the surface. The lower epiphysis is missing and the surface of the lower end of the bone would suggest that the epiphysis had not yet united with the diaphysis.
H.H.S.

Purchased.

1283.20- Left radius. Necrosis.
905
27
2

The shaft is slightly thickened. On the anterior surface just below the middle there is a cavity having a longitudinal diameter of one centimeter, in the bottom of which is seen a small sequestrum adherent to the bone below. On the outer side and above this point the bone is roughened as from periosteal irritation.
H.H.S.

Purchased.

251 A-C
1049.75

1283.30- Bones of left upper extremity. General necrosis of the radius, caries of the humerus, ulna and carpus.

907
27
2

The specimens were removed by amputation below the middle of the humerus. The radius is in an advanced stage of necrosis. The involucrum is large, friable, fenestrated and open at both ends. The sequestrum is small and is in several pieces; one is seen in the lower end and others may be seen through cloacae. The head has been destroyed by caries. Caries has also attacked the lower end of the humerus including its articular surface, the extremities of the ulna, the scaphoid and semilunar bones. There is some periosteal deposit above the outer condyle of the humerus.

Presented by Dr.T.H.Bache.

1284- Left radius. Arthritis of the head.

911
28
2

The articular surface is roughened and its lateral portion is upon the posterior side more of the nature of a ridge.

Presented by Dr.Mütter.

1284.05- Left radius. Arthritis of the head.

908
27
2

251 A-C
1049.75

The head is atrophied, its surface is rough and shows a cavity on the ulnar side; its lateral surface is narrow.

Presented by Dr. Mütter.

1284.10- Left radius. Exostosis of the head.

896 27 1

The head of the bone is much deformed. Its longest diameter is 3cm., owing to a prolongation upon the external side. The articular surface is rough and on the anterior surface of the neck there is a depression.

Presented by Dr. Mütter.

1284.15- Right radius. Arthritis. Exostosis.

909 28 2

The head of the bone is atrophied, its upper surface is rough and porous and its lateral surface reduced to a sharp ridge. The lower articular surface is rough. The facette for the ulna is very large and has a prominent margin.

1284.20- Right radius. Arthritis of the lower end.

914 28 2

The margins of the articulation are prominent. The facette for the ulna is bounded by a prominent border.

Presented by Dr. Mütter.

251 A-C
1049.75

1284.25- Left radius;hyperostosis.

910
28
2

Presented.

1289- Left radius and ulna. Bending of the lower end of the radius.

971
28
2

The lower epiphyses of the bones have not united with the diaphyses, although they are nearly adult. The lower end of the radius is abruptly bent backward about 20°.

Vertical section shows no evidence of gross rupture of the bony fibres.

H.H.S.

Purchased.

1292- Left humerus, ulna and radius. Fracture of the upper shaft of the ulna. Union with anchylosis of the elbow-joint.

913
28
2

in case with bullet fracture

The ulna was fractured about 7cm. from the elbow-joint. Union has occurred with slight thickening of the bone. The callus is smooth and strong. The broken ends were allowed to bend inward toward the radius and almost touch it. The anchylosis was probably secondary to the fracture and is complete. The callus over the joint is not so compact as that uniting the fracture. The forearm and arm

form an angle of 115°; the forearm being in supination.

Dissecting room specimen.
W.S.F.

Purchased.

1292.05- Left humerus, ulna and radius. Oblique fracture of the lower shaft of the ulna. Union with anchylosis of the elbow-joint.

982
27
4

The ulna was fractured obliquely at the junction of the middle and lower thirds. The plane passed from the anterior surface, downwards, forward and backwards. Union has occurred with strong smooth callus and with slight anterior displacement of the lower fragment. The fractured ends were inclined toward the radius.

Secondary anchylosis with complete obliteration of the elbow-joint has occurred, the forearm being fixed at an angle of 130o with the humerus and half way between pronation and supination. The internal condyle is flat and rough.

From a man who died of typhoid fever four years after a fracture of the ulna. "This specimen shows the result of bad treatment. For his fractured ulna an internal angular splint was put on and allowed to remain too long. The proximity of the fracture to the joint and the pres-

251 A-C
1049.75

251 A-C
— 1049.75

sure of the splint on the inner condyle of the humerus has caused ulceration and inflammation attacking the joint. A coalescence of the three bones forming it has taken place."
W.S.F.

Purchased.

1292.10- Adjacent ends of left humerus, ulna and radius. Fracture of the upper shaft of the ulna. Union with anchylosis of the elbow-joint.

915 ~~28~~ 27 2

in case with bullet fracture.

The fracture of the ulna occurred 7cm. from the olecranon. Union has occurred with displacement of the fractured ends toward the radial side. The tubercle of the radius is slightly adherent to the ulna. The callus is not excessive, is smooth and strong.

Anchylosis with complete obliteration of the elbow-joint has occurred. The internal condyle is normal. Slight osteophytes point upward from the tubercle of the radius.

Dissecting room specimen.
W.S.F.

Purchased.

1299.45 ~~1292.11.~~ Adjacent ends of the humerus, ulna and radius. Anchylosis of the elbow-joint.

887 ~~874~~ 25 ~~20~~ 6

Presented.

251 A-C
— 1049.75

1292.15- Left ulna. Fracture of the upper shaft. Union.

The fracture occurred 9cm. from the olecranon. Union has occurred with displacement of the fractured ends to the radial side, and with excessive callus. The union is strong and the callus is grooved by vascular channels. The olecranon and coronoid processes are thick and deformed. The joint is rough.

Presented by Dr.Mütter.

1292.20- Right ulna. Oblique fracture of the middle shaft. Union.

The ulna was broken at the middle. The plane passed from the posterior surface downwards and backwards. Union has occurred in excellent position with moderate but strong callus.

Purchased.

1292.25- Right ulna. Fracture of the lower shaft. Union.

The fracture occurred 5cm.from the styloid process. The fractured ends have united in good position with slight thickening;the surface is slightly rough but strong.

Presented by Dr.Mütter.

1292.30- Left ulna. Oblique fracture of the lower end. Union.

919
27
2

The fracture occurred about 4cm. from the styloid process. The plane passed from the posterior edge obliquely downwards and forwards. Union has occurred in good position, but considerable thickening is present due to excessive callus.

Presented by Dr. Mütter.

1292.31- Left ulna. Fracture of the lower extremity; union.

972
28
2

(932)

Presented by Dr. Guy Hinsdale.

1292.35- Right ulna. Transverse fracture of the lower end. Union.

920
27
2

The fracture occurred about 4cm. from the styloid process. Union has occurred with slight posterior displacement of the lower fragment. The callus is not strong and the spongy tissue is exposed. The extremity of the bone has been accidentally broken off.

Presented by Dr. Mütter.

1297 & 1302- Left ulna. Caries of the upper end. Probably syphilitic.

921
27
2

251 A-C
— 1049.75

The disease occupised 7cm. of the upper end of the bone. The articular cartilage is destroyed and the friable spongy tissue, exposed. The bone at this end is thickened, the surface is rough, freely covered with vascular openings and is of a gray color. At the olecranon and below it there are deep fissures. 5mm. broad running in a vertical direction. The lower end of the bone is not involved.

Dissecting room specimen.

W.S.F.

Purchased.

1297.10- Right ulna. caries and arthritis.
922
27
2

The upper end is greatly changed. The articular surface is destroyed and the surface is rough and carious. The coronoid process is excavated and is fragile. The curve of the greater sigmoid cavity amounts to about one third of a circle. Numerous broad grooves are seen in the surface of the bone upon the radial side. No proper articulation for the radius is seen at the upper end.

Presented by Dr. Mütter.

1297.15- Left ulna. Caries.
923
27
2

The extremities of the bone are

251 A-C
— 1049.75

slightly involved in caries. The outer border of the sigmoid cavity and of the lower articular surface are affected. The styloid process is not present. The head inclines upward and its articular surface is rough.

Presented by Dr.Mütter.

1299- Right ulna. Arthritis. Fenestration
929 of the greater sigmoid cavity.
28
2.

The upper articular surface is irregular;its margins are thick. In the deepest part of the sigmoid cavity near the radial side there is a fenestration having a diameter of 2mm. The bone at this situation is thick.

Presented by Dr.Mütter.

1299.05- Right ulna. Arthritis and exostosis
924 of the upper extremity.
27.
2.

The greater sigmoid cavity is rough and pitted. It is broadened by an arthritic deposit which renders the borders of this cavity prominent and irregular,especially upon the outer side. Viewed laterally, the cavity comprises two-thirds of a circle,owing to the extreme prominence of the coronoid process. Below this process the bone presents numerous osteophytes.

251 A-C
— 1049.75

The lower articular surface shows, also, slight traces of arthritis. The groove for the tendon of the extensor carpi ulnaris is unusually deep and has a wall of bone comprising two-thirds of a circle, the vacancy being left upon the radial side.

Presented by Dr. Mütter.

1299.15- Left ulna. Ostitis and exostosis of the upper extremity.

897
98
1

The upper extremity of the bone is thickened; its surface is rough and the greater sigmoid cavity presents numerous irregular pits. The outer border of the cavity is sharp and spiculated. On the radial side of the upper shaft there is a shallow depression apparently caused by the rotation of the radius.

Purchased.

1299.20- Left ulna. Arthritis.

925
28
2

The upper end is only slightly involved. The articular surface is roughened, but not to an extreme degree. The head is deformed by a fringe of callus. The styloid process is deeply grooved on the posterior side by the tendon of the extensor carpi ulnaris. This groove com-

prises about two-thirds of a circle and its vacancy is directed to the radial and posterior surface.

Presented by Dr.Mütter.

See Vol. 1 - Pg. 14

1299.25- Left ulna. Hypertrophic condensing ostitis.

926
28
2

The bone is enlarged, heavy and rough. This roughness is chiefly about the insertion of the interosseous membrane, Vascular channels are seen crossing the surface of the shaft, but few openings occur. The head is deformed and the styloid process is rough and small.

Presented.

1299.30- Right ulna. Hypertrophic condensing ostitis,

927
28
2

The shaft and upper end of the bone is very much thickened. Its surface is rough and marked, especially upon the radial side by vascular grooves. The coronoid process is rough. The outer portion of the articular surface was devoid of cartilage.

Presented by Dr.Mütter.

1299.35- Right ulna. Hypertrophic condensing ostitis.

973
28
2

This is a fine specimen. The bone is greatly thickened throughout. The diameter of the upper shaft is3.5cm. The surface is very rough, especially upon the radial side, and is marked in every direction by vascular channels which may be usually traced to nutrient foramina. Many osteophytes are seen below the coronoid process. Below the lesser sigmoid cavity the bone presents a hollow for the rotation of the radius.

Presented by Dr.Mütter.

1299.40- Left ulna. Arthritis.
928-
28
2

Both articular surfaces are affected. A fringe of callus renders prominent the margin of the greater sigmoid cavity. The head of the bone is only slightly affected near the styloid process.

Dissecting room specimen.
W.S.F.

1299.45 see vol I page 893 Purchased.
1302- see Vol-1-Page 897

1304- Left ulna. Peculiar marking of the junction of the upper epiphysis.
949
28
2

There is a depressed line running from the upper and inner portion of the greater sigmoid cavity downward and around the olecranon in the line of the epiphyseal

251 A-C
— 1049.75

junction, This line is not deep; it resembles a line of absorption seen in the separation of a sequestrum.

The shaft of the bone is very slightly thickened, but otherwise healthy. The lower epiphysis has united well to the shaft.

Presented.

1307-932 27 2 Lower half of left humerus with the radius and ulna. Incomplete double fracture of the radius and ulna. Transverse fracture of the humerus.

The fracture of the humerus occurred at the middle. The radius sustained an incomplete fracture both at the middle and at 4cm. from the wrist-joint.

The ulna sustained incomplete fractures at the lower third; at 7cm. and at 4cm. from the end. In the ulna the rupture took place on the posterior side and extended more than half way through the bone. The anterior wall of the ulna is less involved than that of the radius; the lower fracture of the latter was nearly complete. In the radius the rupture of bone took place in the anterior surface while the forearm was in a position of forced pronation, thus having rotated the

radius 180°. The tubercle of the radius may be seen on the outer side of the border of the ulna.

From a boy aet.14 whose arm was torn off by machinery.

~~Trans.Phils.Pathological Soc'y~~ and Phila. Med.Times,May 1st,1872. — cannot locate this reference

Presented by Dr.A.F.Müller.

1307.02- Bones of the right upper extremity. Fracture of ulna and radius. Union with cotossification.

944 27 8

in case with shell fracture

The fracture occurred above the middle of the forearm. The uniting callus is smooth but exuberant and firmly binds the radius and ulna together. The forearm is fixed midway between pronation and supination. It is difficult to state in the radius the precise location of the fracture.

Presented by Dr.Mütter.

1307.05- Right radius and ulna. Fracture of both bones in the upper third.

880 26 6

The fracture of the ulna occurred about 9cm. from the olecranon. Union has occurred in good line with smooth strong callus. The radius was fractured 1cm. below the tubercle. The lower fragment

passed slightly upward and in front of the upper fragment. The callus is smooth and strong.

Presented.

1307.10- Left radius and ulna. Fracture of both bones in the lower third. Union.

The lower fragment of the radius was 6cm. long. It passed upward and behind the upper fragment. The extremity of the latter is prominent. The uniting callus is smooth and strong. The lower fragment of the ulna was 4cm. long and passed to the radial side where it is firmly united.
H.H.S.

Purchased.

1307.15- Right radius and ulna, Fracture of both bones below the middle. Union.

The Fracture of the radius occurred below the middle. The lower fragment passed upward and anteriorly and forms a prominence on the anterior surface. The fracture of the ulna occurred at the junction of the middle and lower third. Union occurred without deformity. The callus in both fractures is smooth and firm.

Presented by Dr. Mütter.

destroyed

1307.20- Right radius and ulna. Fracture in the lower third. Union. (Plaster cast.)

The lower fragment of the radius was 4cm. long and is well united to the shaft. The fragment of the ulna is 4.5cm. long and has united allowing approximation of the upper fragments.

H.B.Tuson, London, fecit.

1307.21 Radius and ulna. Gunshot fracture. Purchased. see Vol I Page 444

1307.22 " " " " " . see Vol I Page 446

1307.25- Adjacent ends of right humerus, radius and ulna. Gunshot fracture of radius and ulna. Recent.

The bones are greatly comminuted; the radius having received the ball just below the tubercle and the ulna at a slightly higher level. The lines of fracture are chiefly vertical. In mounting, the radius has been rotated.

From a soldier who underwent primary amputation.

Presented by the Surgeon General U.S.A.

1307.30- Adjacent ends of right humerus, ulna and radius. Gunshot fracture of radius and ulna.

The bones were shattered in the upper third of the shaft. The specimen shows the result of inflammation following the

1307.35 Right elbow joint; Gunshot fracture. See Vol I Page 447

1307.40 Right elbow joint; Gunshot fracture. See Vol I Page 447

1307.45 Right elbow joint; Gunshot fracture. See Vol I Page 444

1307.56- Comminuted fracture of radius & ulna-

injury. The surface of bone is rough and where the superficial lamina of bone has been abraded, there is a white and chalky appearance.

Presented by the Surgeon General, U.S.A.

1313- Gangrene of the left forearm and hand.

The specimen was dried after amputation in the upper forearm. Shriveled tissues invest the forearm. The bones of the hand are bare. The radius and ulna at their middle are grooved, presenting a worm-eaten appearance at the same level; below this point the bone is smooth.

From a man aet. 24 years, whose radial and ulnar arteries were divided and the soft parts torn by a circular saw. He would not allow his arm to be amputated. Gangrene supervened and after some days the line of demarcation appeared and the parts well separated. The man then allowed the bones to be divided just above the point of their ulcerated surface, seen in the specimen and made a good recovery.

1314- Left radius and ulna. Anchylosis.

The two bones are anchylosed through-

251 A-C
1049.75

out 6cm. in their upper extremities. The radius seems to have gently merged itself with the ulna, presenting a smooth, homogeneous appearance as of one bone. The bones are fixed in extreme pronation.
H.H.S.

Purchased.

1314.10- Left radius and ulna. Hypertrophic
933 ostitis.
27
2 The ulna is particularly involved. The specimens are possibly syphilitic.

Presented.

1314.15- Left radius and ulna. Anchylosis.
~~934~~ 934
27 The bones are 10cm. long and from a
2 very young child. Their lower extremities have been lost. The upper extremity of the ulna presents no sigmoid cavity but only a thickened end. Upon its outer side rests the upper end of the radius, having no head and ~~ana~~ankylosed with the ulna in a position of extreme pronation. The union is smooth.

Presented by Dr. Mütter.

1314.20- Right radius and ulna. Arthritis.
942 The elbow and wrist joints are both
27 involved. The greater sigmoid cavity com-
2

prises two-thirds of a circle. The olecranon and coronoid fossae are prominent and their borders are marked by excess of callus. In the depth of the cavity there is a transverse ridge of callus. The head of the radius has a distorted appearance and is slightly eburnated. Its fringe of callus is abundant and gives the head an apparent inclination toward the ulna. The callus overhangs, but does not involve the neck.

The wrist also was the seat of arthritis. The ulna presents a slight growth of callus at its articulation with the radius. The articular surface of the radius is plainly marked by facettes for the scaphoid and semi-lunar bones.

Dissecting room specimen.
W.S.F.

Purchased.

1319- Adjacent ends of left humerus, radius and ulna. Stump of forearm after amputation.

939
27
a

Amputation was performed just below the tubercle of the radius. The ends are now closed by compact tissue, are smooth and broad and of the normal thickness of the shaft. The joint is intact and motion

was free.

Dissecting room specimen.

Presented by Dr.John H.Packard.

1319.10- Right humerus with upper ends of radius and ulna. Stump after amputation.

940
27
2

Amputation of the forearm was performed just below the tubercle of the radius. The ends of both bones are conical, the ulna terminating in an especially sharp point; there is, however, smooth compact tissue over the entire end. Anchylosis has occurred in moderate extension. The lower portion of the shaft of the humerus presents an irregularity as of an old fracture. The line of the bone is perfectly straight.

Presented by Dr.Mütter.

1319.20- Left upper extremity of a child. Mummied.

941
27
2

The specimen is shriveled, black and almost unrecognizable.

Presented by Dr.Mütter.

1321- Lower end of the left humerus with bones of the left forearm and hand. Dislocation of the carpus.

943
27
2

in case with shell fractures.

251 A-C
1049.75

The specimen was obtained by amputation at the lower third of the humerus. The bones of the carpus are greatly displaced. The first row of carpal bones are seen only on the palmar side and their surfaces for articulation with the forearm are plainly visible; the radius and ulna are incontact with their dorsal surface. On the palmar surface, the unciform is barely seen, its process not being visible. The osmmagnum is seen at the bottom of a deep hollow. The bases of the metacarpal bones are visible.

Posteriorly the os magnum and the unciform are prominent objects; the hook-like process of the latter lies over the base of the fifth metacarpal.
H.H.S.

Purchased.

1322-945 27 2 Part of the right forearm with the hand. Compound comminuted fracture at the wrist-joint. Recent.

The specimen was obtained by amputation in the middle of the forearm; it has been partly dissected and dried. The wrist-joint has been disintegrated; the lower ends of the radius and ulna have been crushed, their fragments remaining adherent to various ligaments. The semi-

lunar, cuneiform and pisiform, unciform and os magnum are not recognizable. From below the scaphoid it is seen to be fissured. The fourth and fifth meta~~tarsals~~carpals are fractured obliquely near their bases. The ligaments of the extensors of the fingers are torn.

Presented.

1322.10- Part of the left forearm with the hand. Compound comminuted fracture of the carpus, metacarpus and phalanges; separation of the epiphysis of the radius. Recent.

The specimen was evidently removed from a child of about ten years by amputation at the lower end of the forearm; the dorsal surface has been dissected and the specimen dried. The epiphysis of the radius has been separated from the shaft. The greater part has been entirely dislodged and lies exposed to full view upon the dorsal surface, hanging by the radiocarpal ligament. A slight portion of the epiphysis, on the ulnar side, remains attached to the shaft. The ulna was apparently not injured. The carpus is crushed. The first and second metacarpals are intact; of the third nothing but the head remains; the fourth is fractured transverse-

251 A-C
1049.75

ly near the base; the fifth is fractured obliquely through the base. The first phalanx of the index finger is transversely fractured at the distal end; the first phalanx of the middle finger is obliquely fractured through the base.

Presented.

1322.20- Lower end of the right forearm with the bones of the hand. Comminuted gunshot fracture of the carpus and metacarpus.

946
28
2

The scaphoid, semilunar, magnum, trapezoid and trapez~~ins~~ium and first, second and third metacarpals are comminuted. The hand was amputated secondarily.

Presented by the Sur eon General U.S.A.

1339. ~~1335.~~ Bones of the left forearm and hand with the lower end of the humerus. Deformity of the hand with atrophy.

948
28
2

deformity 2

The epiphyses have not yet united with the shaft. The radius and ulna are short and the radius is pronated and curved with the convexity above. The carpas is extremely flexed and displaced from the articulation so that its dorsal surface is nearly in the same plane with the articular surface of the radius, lying on the ulnar side. Three atrophied meta-

carpals and one or two atrophied stumps of phalanges remain. The metacarpals point backward toward the elbow.
H.H.S.

Purchased.

One specimen with two numbers.

1336 & 1337- 974 28 2.

Lower end of the radius and ulna with the bones of the hand. Old backward dislocation of the second, and fracture of the third and fourth metacarpals. Union with deformity.

The dislocation of the second metacarpal produces a great prominence on the dorsum of the hand. The third metacarpal was obliquely fractured at the middle; the fourth, near the base. Union has occurred with prominence of the proximal fragment and depression of the head of the third metacarpal. There is partial backward dislocation of the first metacarpal.

This accident rendered the little finger nearly as long as any and allowed the head of the metacarpal to project further than any of its fellows.
H.H.S.

Purchased.

1336.10- 930 28 2

Hand 19. Metacarpals and phalanges of the left thumb and index-finger. Dislocation of the second metacarpo-phalan-

geal joint. Anchylosis.

The bones are large. The metacarpo-phalangeal and the phalangeal joints are obliterated. The first phalanx of the index-finger is rotated with its palmar surface inwards 90° and is anchylosed in that position.

Presented by Dr.Mütter.

1337.10- Hand 13. Bones of the right hand.
947
28
2

Gunshot fracture of the fourth metacarpal and its adjacent phalanx. Recent.

The distal portion of the metacarpal and the adjacent end of the phalanx are missing. The fractures were oblique. The hand was amputated secondarily.

Presented by the Surgeon General U.S.A.

1339 see Vol. I page 929.

1357 ~~1342-~~ Caries of phalanges.
975
28
2

The second and third phalanges of two fingers are deeply involved in caries.

Purchased.

1343- Missing Fourth right metacarpal. Necrosis. Missing
935
27
2

The entire bone is involved. The shaft consists of the involucrum, porous and friable. The remainder of the sequestrum is seen at the distal end part-

ly adherent to the head.
H.H.S.

Purchased.

1344- Hand 14. Second, third ~~and~~ fourth & 5th
937 right metacarpals. Ostitis.
27
2

The second and third bones are chiefly affected. Their dorsal surface is flattened and the distal portion of the shaft is thickened by ostitis.

Purchased.

1344.10- Hand 15. First metacarpal ~~s~~ bones Arthritis.
936 The bones ~~is~~ are short and stout and
27
2 curved. ~~Its~~ The articular surfaces are rough and the borders are prominent as the result of arthritis.

Presented by Dr.Mütter.

1350- Right carpus, metacarpus and phalanges. Deformity and atrophy of the phalanges.
931
27 ~~25~~
2

The bones are small but adult. The heads of the metacarpals are flattened; the phalanges of the first row are bent backward on the metacarpus and are atrophied, only the proximal portion of the shaft remaining. The process of the unciform bone is prominent.

Presented.

1354 Avulsion of the thumb

1354. 50. Avulsion of a finger. In Dec. 1879 Dr. Charles Baum was on duty at the Pennsylvania Hospital when a young man was admitted to the receiving ward. His finger was caught in a machine, in an effort to withdraw the finger, the enclosed specimen occurred.

Presented by Dr. Chas. Baum.

1357 - see Vol I Page 933

1365- Pelvis of a child. Deformity.

1014
31
1

The fourth and fifth lumbar vertebrae are attached to the pelvis. There is a depression in the left half of the pelvis, so that the ilium nearly touches the sacrum.

From a child aet. two years.

H.H.S.

Purchased.

See 17 - Shelf 5

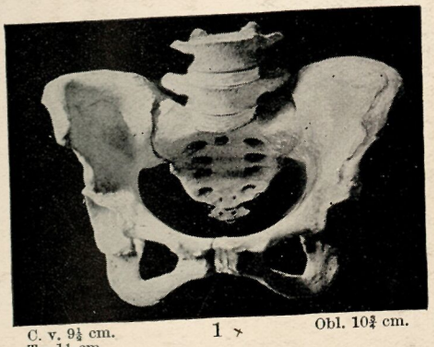

C. v. 9½ cm.
Tr. 11 cm.
1
Obl. 10¾ cm.

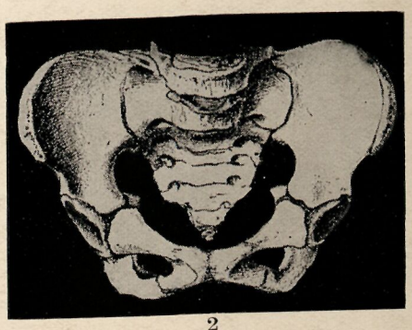

2

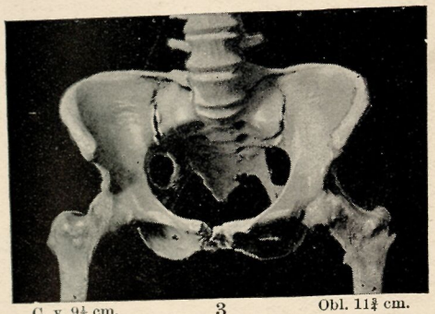

C. v. 9½ cm.
Tr. 12½ cm.
3
Obl. 11¾ cm.

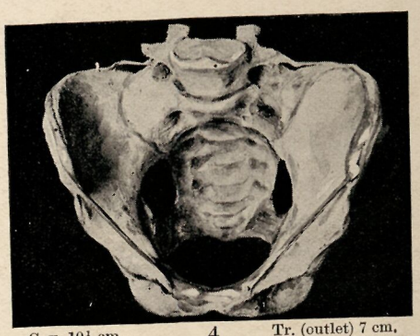

C. v. 10½ cm.
Tr. (inlet) 8¾ cm.
4
Tr. (outlet) 7 cm.
Ant. post. out'et 7½ cm.

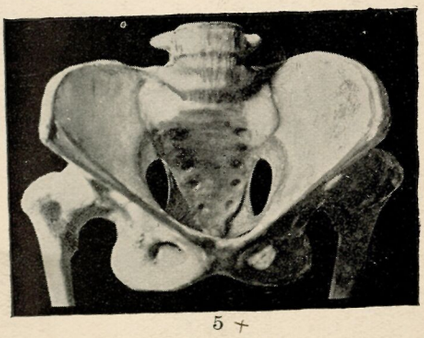

5

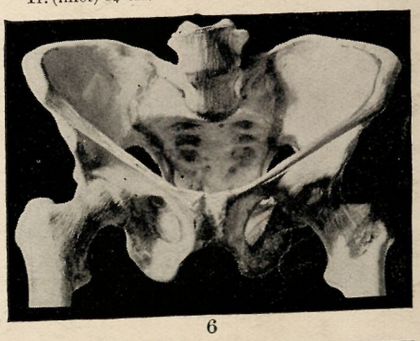

6

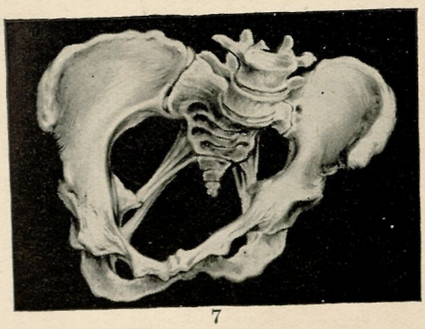

7

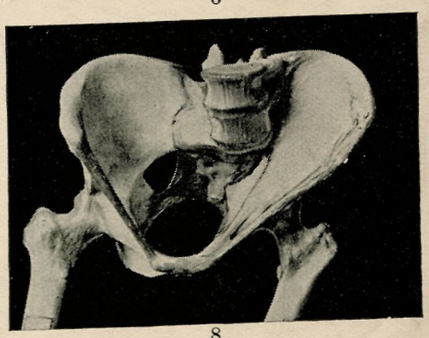

8

1. Justo-minor pelvis (Mütter Museum, College of Physicians, Philadelphia), inlet a perfectly symmetrical ovoid. 2. Dwarf pelvis. 3. Justo-minor pelvis with ruptured pelvic joints, following forceps application (Hirst Collection, University of Pennsylvania). 4. Narrow, funnel-shaped pelvis (specimen in the Hirst Collection, University of Pennsylvania). 5. Fetal ill-developed pelvis, probably an arrested development from rachitis (Mütter Museum, College of Physicians). 6. Minor grade of narrow, funnel-shaped pelvis with contracted pubic arch. 7. Obliquely-contracted pelvis (Naegele). 8. Obliquely-contracted pelvis (photographed from a plaster cast).

939
1365.01
1365.17
1023
1365.27
1030
p. 251 A-C
15 — 1049.75
009

941

P. 251 A-C
5 — 1049.75
09

MÜTTER MUSEUM,

College of Physicians of Philadelphia,

Thirteenth and Locust Streets.

.....190

Plate 20 – Fig 7 = Flat Rachitic Pelvis
new no. 1018, 31, 1.

Cannot find in Hirst Coll.

1365.40

tion of the sacrum, and lordosis (Mütter Museum, College of Physicians).

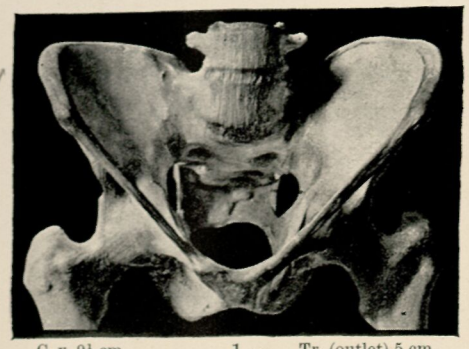

C. v. 9¼ cm.
Tr. (inlet) 8 cm.
1 Tr. (outlet) 5 cm.

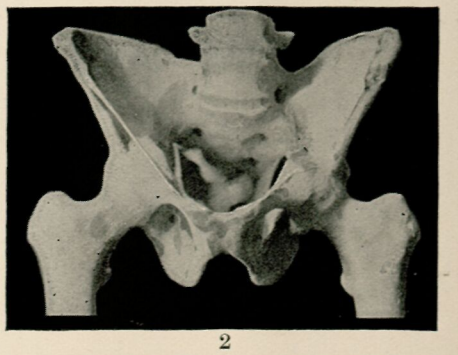

2

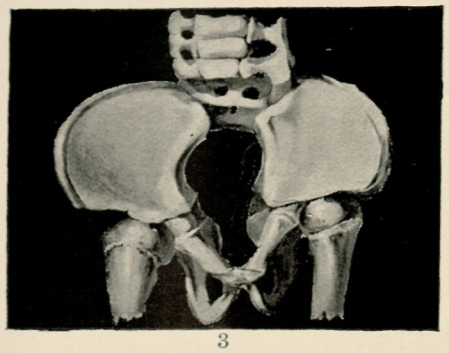

3

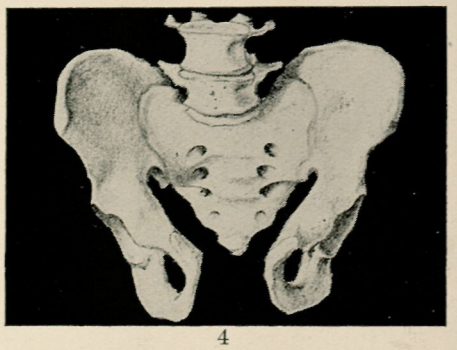

4

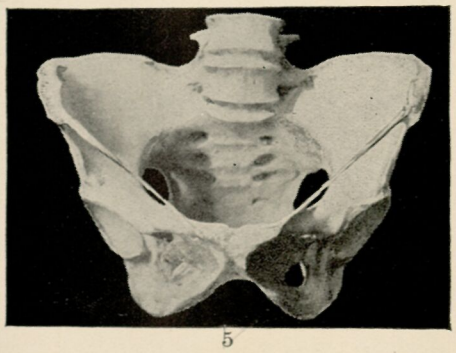

5

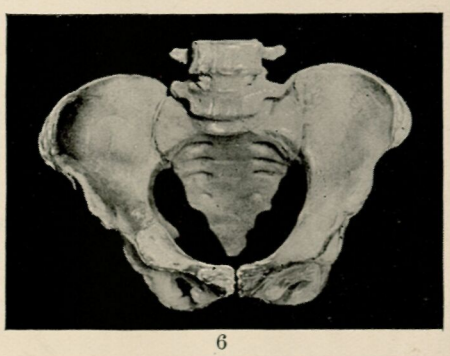

6

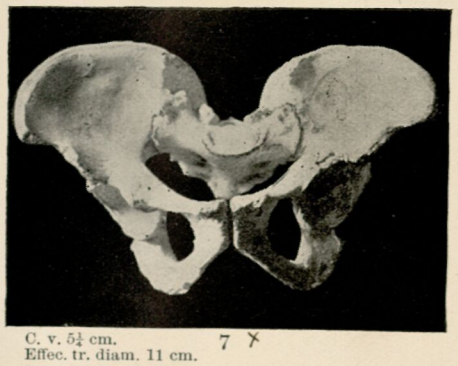

C. v. 5½ cm.
Effec. tr. diam. 11 cm.
7

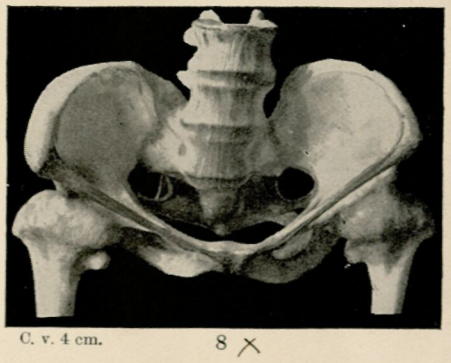

C. v. 4 cm.
8

1. Transversely-contracted pelvis (Robert; model in Mütter Museum, College of Physicians, Philadelphia). 2. Transversely-contracted pelvis, showing contraction at outlet (model in the Hirst Collection, University of Pennsylvania). 3. Transversely-contracted pelvis, with absence of sacrum (Hohl). 4. Split pelvis (Schauta). 5. Generally equally-contracted rachitic pelvis (Hirst Collection, University of Pennsylvania). 6. Generally-contracted rachitic pelvis (Hirst Collection, University of Pennsylvania). 7. Typical flat rachitic pelvis (Mütter Museum, College of Physicians). The promontory of the sacrum projects so far forward that the true transverse diameter is bisected by it. 8. Flat rachitic pelvis, with unusual descent of the promontory, rotation of the sacrum, and lordosis (Mütter Museum, College of Physicians).

943

P. 251 A-C
5 — 1049.75
09

p. 943 A

65.22

65.02

65.34

365.41

MÜTTER MUSEUM,

College of Physicians of Philadelphia.

Thirteenth and Locust Streets.

.....190

Plate 31 — Fig. 7. = 1019 - 320-1

943
P. 251 A-C
5 — 1049.75
09

1365.034
1047
1365.22
1365.02
1365.36
1365.34
1365.44

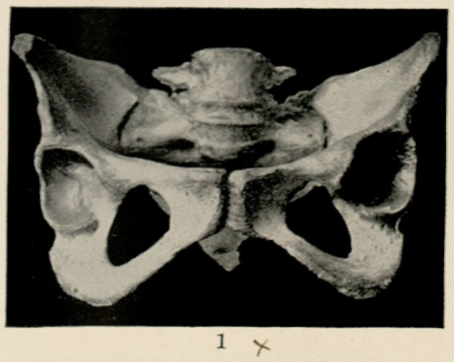

1

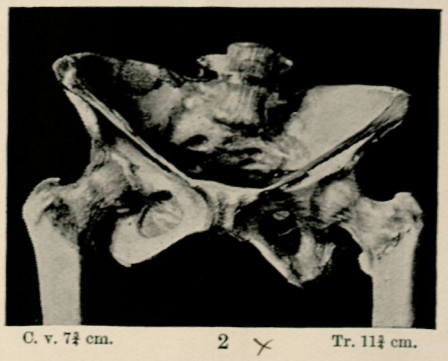

C. v. 7¾ cm. 2 Tr. 11¾ cm.

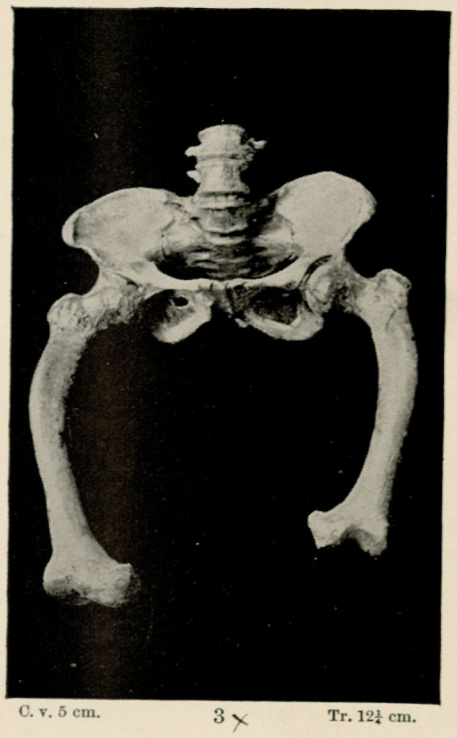

C. v. 5 cm. 3 Tr. 12¼ cm.

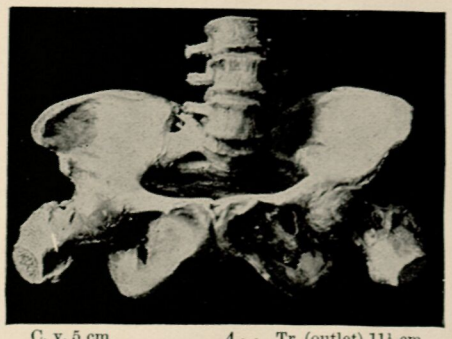

C. v. 5 cm.
Tr. (inlet) 11 cm. 4 Tr. (outlet) 11½ cm.

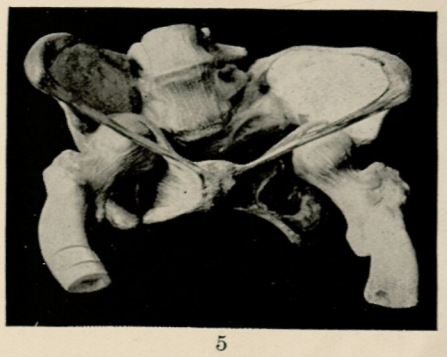

5

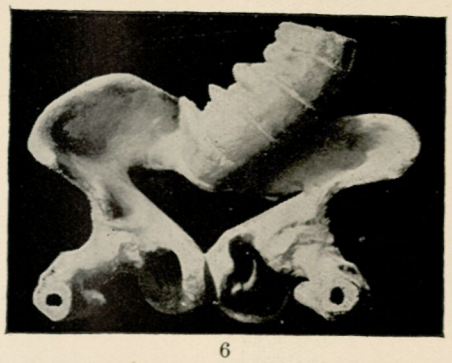

6

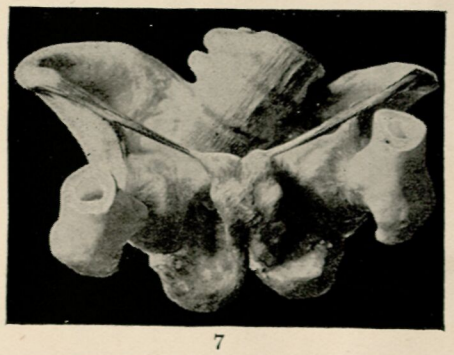

7

1. Flat rachitic pelvis, showing anterior position of acetabula (Mütter Museum, College of Physicians, Philadelphia). 2. Flat rachitic pelvis, showing relative measurements of antero-posterior and transverse diameters at inlet (Mütter Museum, College of Physicians). 3. Flat rachitic pelvis with bowed femora (Mütter Museum, College of Physicians). 4. Flat rachitic pelvis, showing relative measurements of inlet and outlet (Mütter Museum, College of Physicians). 5–7. Pseudo-osteomalacia.

1

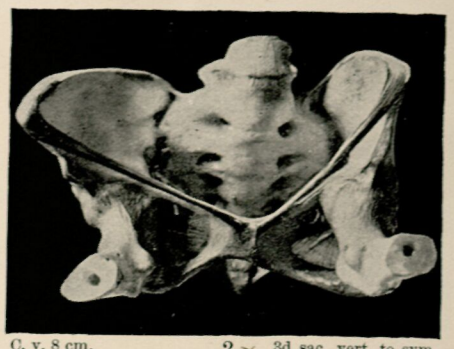

C. v. 8 cm. 2d sac. vert. to sym. 5½ cm. 2 3d sac. vert. to sym. 4½ cm. Tr. 11½ cm.

3

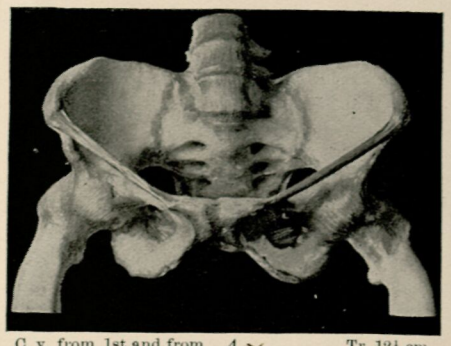

C. v. from 1st and from 2d sac. vert. 6½ cm. 4 Tr. 12½ cm.

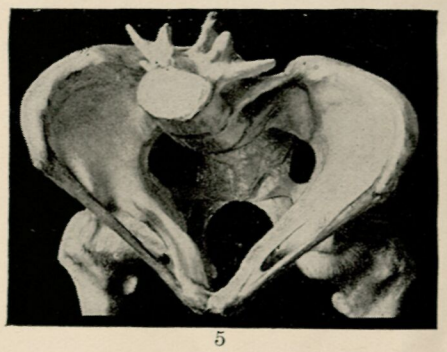

5

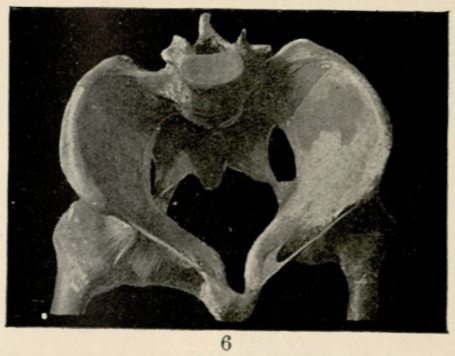

6

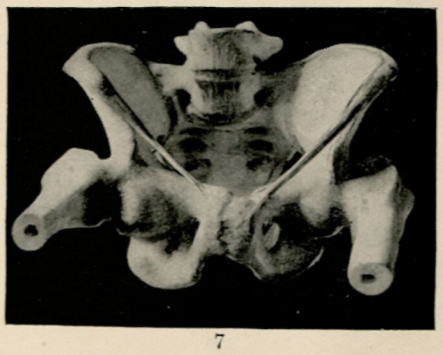

7

1. Pseudo-osteomalacia. 2. Rachitic pelvis with contracted antero-posterior diameter throughout the pelvic canal (Mütter Museum, College of Physicians, Philadelphia). 3. Pendulous belly of rachitis (Charpentier). 4. Rachitic pelvis with double promontory (Mütter Museum, College of Physicians). 5, 6. Minor grades of osteomalacic pelves. 7. Osteomalacia, showing asymmetrical contraction at outlet.

947

p. 251 A-C
5 — 1049.75
009

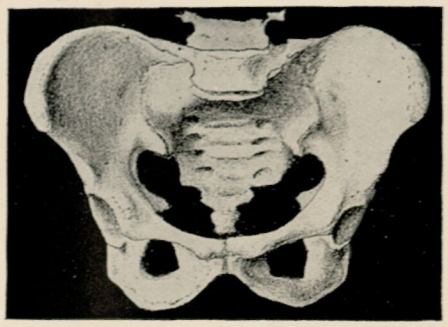

1

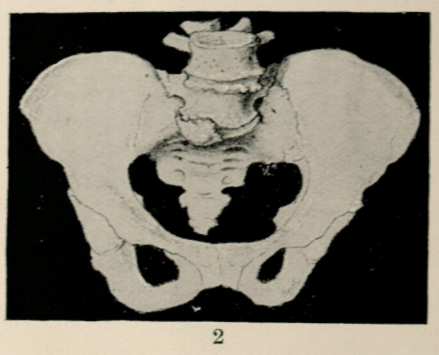

2

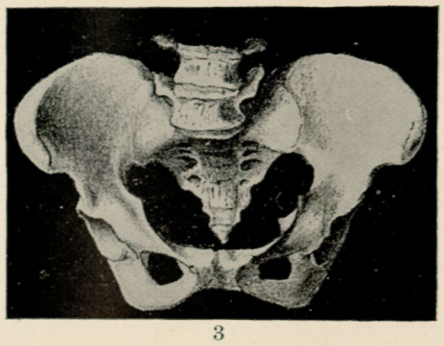

3

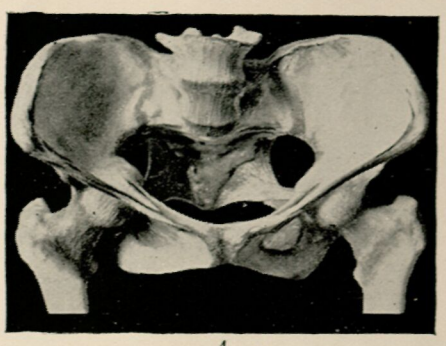

4

1365.14 4
1022

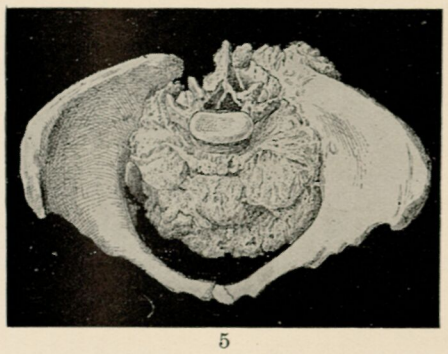

5

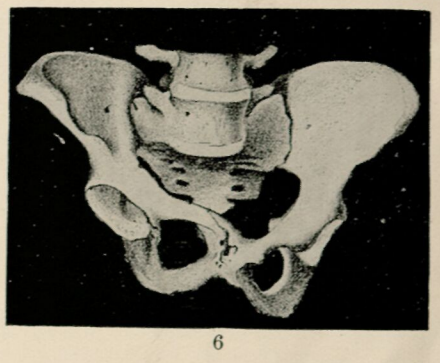

6

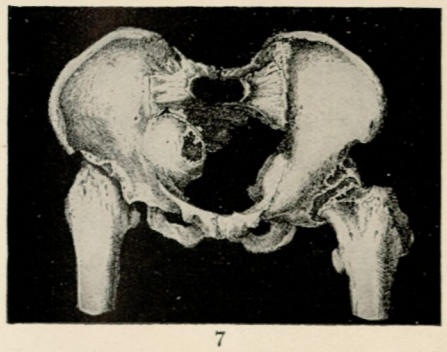

7

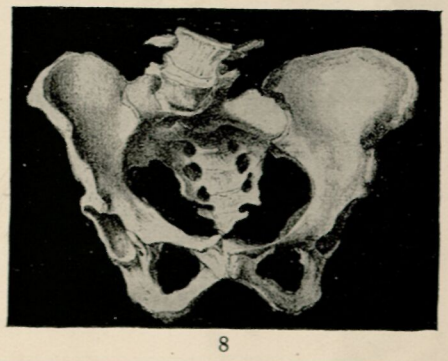

8

1. Exostoses at the sacro-iliac junctions. 2. Knob-like exostosis on the promontory (Schauta). 3. Acanthopelys. 4. Rachitic pelvis with abnormal but blunt projection of ileo-pectineal eminences (Mütter Museum, College of Physicians, Philadelphia). 5. Enchondroma (Behm). 6. Fracture of the pelvis (Otto). 7. Fracture of the acetabula in consequence of coxalgia (Otto). 8. Fracture of the right ala of the sacrum (Fritsch).

949

P. 251 A-C
5 — 1049.75
09

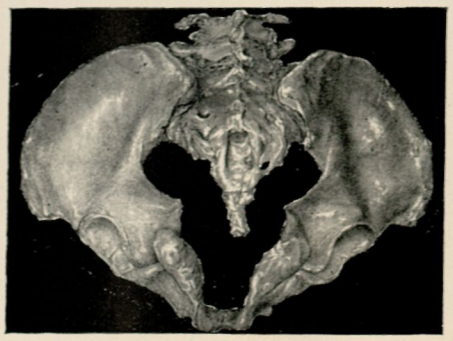

1

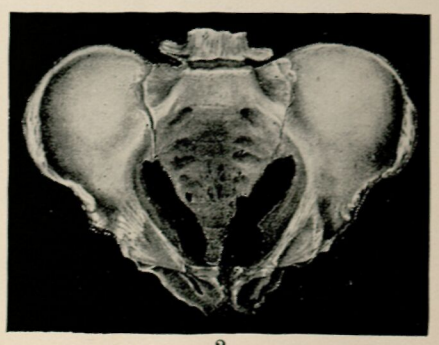

2

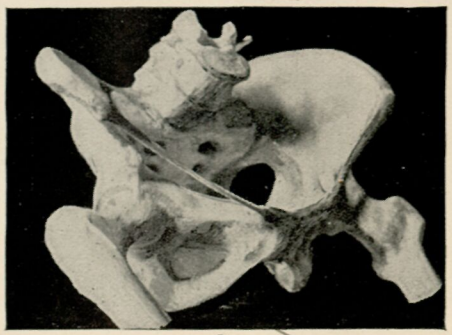

3

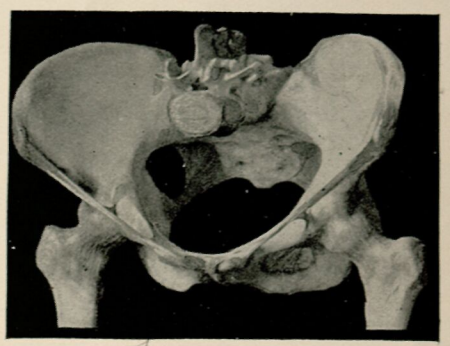

4

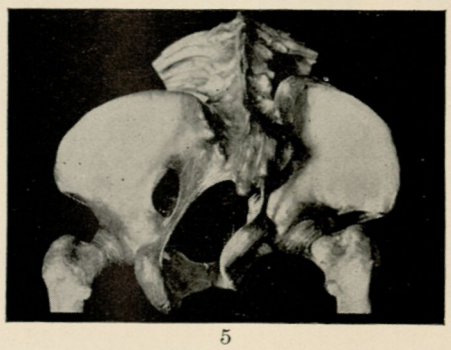

5

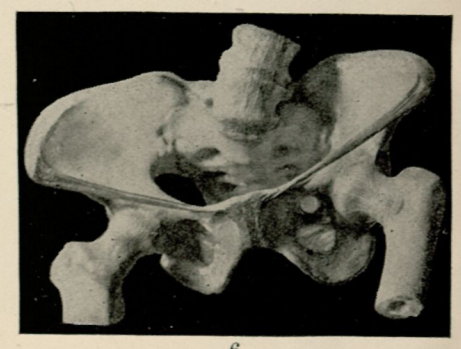

6

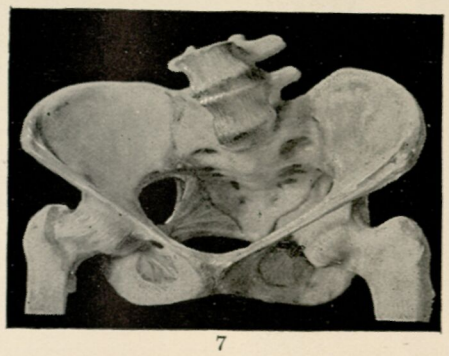

7

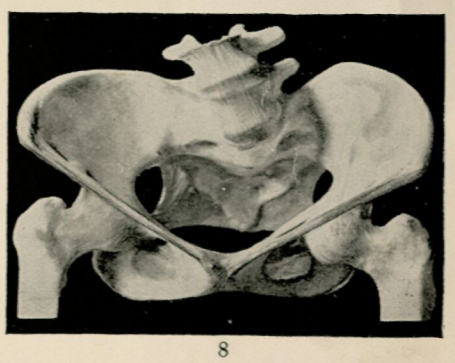

8

1365.37

1365.26 4
1029

not numbered
32
1

1. Contracted outlet of a kyphotic pelvis (Barbour). 2. Kyphotic pelvis from above (Barbour). 3, 4. Lumbo-sacral kyphosis (pelvis obtecta). 5. Asymmetrical contraction of the outlet from kyphoscoliosis. 6–8. Types of scoliotic rachitic pelves.

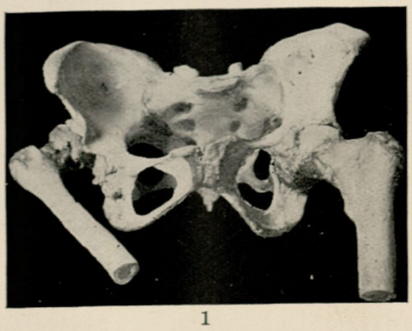

1

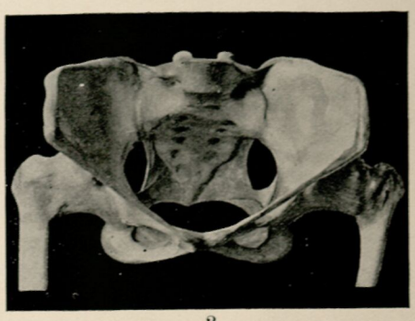

2

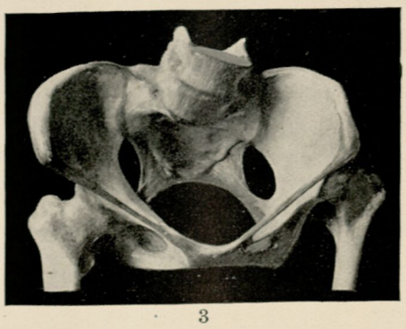

3

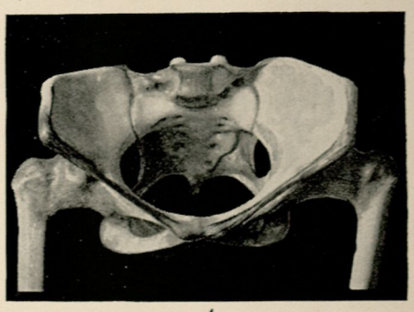

4

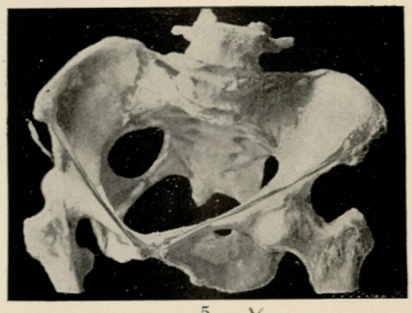

5

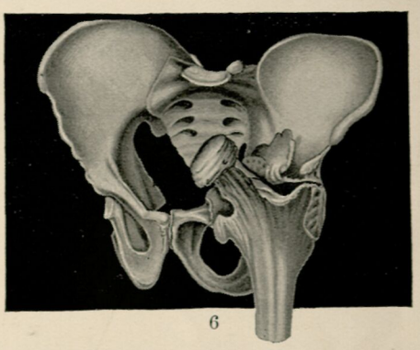

6

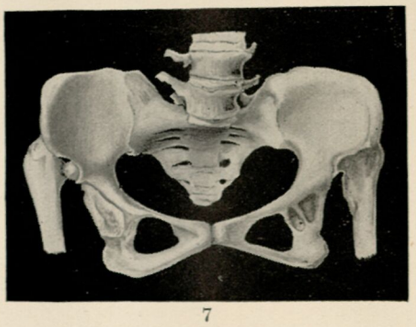

7

8

1. Luxation of right femur. 2. Congenital luxation of both femora. 3. Luxation of left femur on dorsum of ilium, with false joint above acetabulum. 4. Congenital luxation of both femora (photograph of model). 5. Coxalgic pelvis (Mütter Museum, College of Physicians, Philadelphia). 6. Anterior dislocation of femur. 7. Congenital dislocation of the femora. 8. Pelvic deformity, the result of double club-foot (Meyer).

p. 251 A-C
15 — 1049.75
009

I. Flat Rachitic Pelvis: conjugata vera, 2 1-2 in.

II. Generally contracted Flat Rachitic.

C.V. 2 1-2 in. (Transv. narrowing and slight).

III. Generally contracted Flat Rachitic.

(Lumbar hordosis).

IV. Irregular Rachitic or Pseudo osteomalachic Pelvis.

V. Scolio-Rachitic Pelvis.

C.V. 3 in. (Rachitic features marked).

VI. Scolio-Rachitic Pelvis.

C.V. 1 1-2 in.

VII. Scoliosis.

C.V. 3 in.

(Simple flat pelvis complicated by scoliosis).

VIII. Scoliosis: Rachitic features slightly marked.

C.V. 4 1-4.

IX. Scoliosis.

Right oblique diam., 5 in.
Left " " 5 1-2 in.

Funnel-shape narrowing.

X. Kyphotic Pelvis.

Diameter of outlet narrowed.
Trans., 2 1-4; cont., 3 3-4.

XI. Oblique ovale, or Naegele Pelvis,

Anchylosis of left sacro-iliac Synchondrosis.

XII. Double anchylosed or Robert Pelvis.

XIV. Osteo-malacia.

XV. " "

XVI. Infantile Pelvis.

*SK - means that particular pelvis is on a skeleton

MEASUREMENTS OF PELVES
in the Collection of
THE COLLEGE OF PHYSICIANS OF
PHILADELPHIA.

Made by H.T.Pershing,M.D.
Measurements in Centimeters.

Mark on specimen.	Conj. vera.	Conj. diag.	Conj. externa.	Height of symph.	Sac. cot. dex.	Sac. cot. sin.	Diag. dex.	Diag. sin.	Transverse.	Sp. Il.	Cr. Il.	Tub. Isch.	
1365.01- U.Pa.Diss. Room.42	10	11.2	16.8	3.4	8	8	11.5	11	10.8	19	23	11.5	1
1365.02- Purchased. 43	5	7	12.3	3.7	5.3	5	10	10	11	26	28	9	2
1365.03- Ces.sec. R.G.C.44	6	9.9	14.2	3.2	6	5.5	10.7	11	12.5	20.6	21.6	12.3	3
1365.04- a.	5	7.5	13.2	4.4	6.5	4.8	10.4	11	11.4	25	26	11	4
1365.05 F.82	8	9.5	17	3.5	5.7	7.4	11.5	10.2	12	23.5	25.5	9.5	5
1409 SK.* Pres.by	10 11.6												6
1365.06 Dr.Mutter.	11.4	13.5	17.2	3.5	8.2	8.2	11.8	11.7	13	24.5	26.6	11	
sec 8 1145.45 or 1365.07- SK. 1228	10.5	12.3	18.9	3.5	8.2	8.2	10.7	10.5	11	21.5	24	9	7
sec 9 1145.50 or 1365.08- SK 1229	10.7	13	19.3	4	8.3	8.3	11	11	11.6	22.5	26	9.4	8
sec 10 1145.60 or 1365.09- SK 1231	13	14.5	16.3	3	10	9	11.8	11.8	11.5	21.5	23.5	8.5	9
1145.65 or 1365.10- SK 1232	12.5	14.5	17.8	4	10	9.5	10.5	10.5	10.5	24	26	6.3	10
sec 9 1145.55 or 1365.11- SK 1230	9.5 10.4 10.5	12	16.2	3	6.8	7.5	10.5	10	11	19.5	21	10.5	11
sec 9 1636.50 or 1365.12- SK. J.Fem.30	9.5	11.2	—	4.	9	7	11.3	12.7	12.6	23.5	26	10	12
1636.30 or 1365.13- J.Fem.15	9	9.8	17.5	4.5	6.8	8.4	13	12	13.8	25.2	26.5	12.5	13
1194.40 or sec 6 1365.14- V 18	12.5	14.5	—	3.5	9	9	11	11	11	22	25.4	9	14
1365.15- Cast 1	6.4	8.7	16	5	6	7	11.6	11.8	13	26	27	11.4	15
1365.16- Cast II 31.2	7	9.	14.3	4.5	6.7	7	11.5	11	12.8	24	24	9	16
1365.17- " III 31.2	4	6	12.4	4.5	5.5	6	11.2	10.5	11.5	22.5	22.7	10	17
1365.18- " IV 32.2	5	7	14.7	—	1.9	1.5	—	—	11	21.5	26.5	4.5	18
1365.19- " V	7.5	10.4	15.2	4	7.2	4.5	9.8	11.8	12.5	23.8	25.5	11.5	19
1365.20- 31-2 " VI	8.5	11.5	12.5	3	9	7	10.5	11.5	12.4	22	21.5	11.5	20
1365.21- 31.3 " VII	7.8	10	16.7	4	7.2	7	11.3	10.8	12	24	27	12	21
1365.22- 31.3 " VIII	11.5	13	17.7	5	7	10	14	11	14	24	25.5	11.4	22
1365.23- " IX	13	15	21.3	5	11.5	10.5	13	14	14.7	26	28	10	23
1365.24- 31.3 X	12	13.4	20.3	4.5	5.6	9	13	12.5	14	26	28.6	11	24
1365.25- 31.3 XI	10.5	11.6	19.2	5	8	7.7	13	12.7	13.8	24	28.5	6.5	25
1365.26- 31.3 XII	10.5	11.8	20.3	5.5	10.4	5.1	8.3	12.2	10	20	26	6.5	26
1365.27- 32.3 XIII	9.5	10.3	—	4.6	5.5	5.5	8.8	8.3	8.8	19	23	4.8	27
1365.28- 32.3 XIV	9	9.7	18	4.5	4.5		10	10	10	20	23	4	

Sections - 17 and 18

O.N. = Old Museum No.

Dr. Douglas P. Murphy's identification of pelves. on pgs. 955-957, 959-961

Sept. 27 - 1940

Shelf Position	Catalogue Number	Type of Pelvis
		Shelf 3
1	1365.31 X 10330.n	Normal Pelvis
2	1365.02 X 10160.n.	Flat Rachitic Pelvis
3	1365.03 X 10170.n	Flat Rachitic Pelvis
4	1365.16 X 10220.n.	Flat Rachitic Pelvis
5	1365.36 X 1037.0.n.	Flat Rachitic Pelvis
		Shelf 4.
1	1365.24 X 1020-0.n.	Flat Rachitic Pelvis
2	1365.19 X 10270.n	Flat Rachitic Pelvis
3	1365.17 X 10230.n	Rachitic Pelvis of a child
4	1365.04 X 10180.n	Generally Contracted Flat Rachitic Pelvis
5	1365.01 X 1015-0.n.	Generally Contracted Pelvis
6	1365.40 X 1067-0.n.	Obliquely Contracted Rachitic Pelvis
7	1365.22 X 1026-0.n.	Obliquely Contracted Pelvis
8	1365.35 X 1036-0.n	Obliquely Contracted Pelvis

V. 1 p. 251 A-C
9.15 — 1049.75
9.009

Lig. arc. Sac. Coc. ju.	Lig. arc. Coccyx.	Symph. Mid. Sac.	Sp. Il. post.	Trochanters.	Type.	
10.5	—	11.6	8.3	—	G.C. (mostly in transverse)	Plate 29 - #1 (~~justo minor~~)
10	—	10	4.5	—	Fl. G.C. Rachitic.	~~Showing lateral measurements under outlet~~ Plate 31 - #4
10.5	8.6	9.8	8.5	—	Fl. G.C. Rachitic.	~~showing anterior position of~~ acetabula - Plate 31 - #1
9.7	9	9.5	6	28	Fl. G.C. Rachitic	Typical - Plate 30 - #7
11.5	9	11.5	6	28	Fl. G.C.	Missing
11	7.5	10.6	6.5	—	Slight flattening from double pressure	Specimen number 1409 (1365.06 X index no.)
12	—	10.3	7.5	24.5	Tr. Cont.	Skeleton # 1145.45
12	8.7	12.2	6	28	Tr. Cont.	Skeleton # 1145.50
10	8.8	11	5.5	24	Kyphotic?	Skeleton # 1145.60
10.5	7.5	11.3	6.5	23	Kyphotic?	Skeleton # 1145.65
10.3	8	10.4	7.5	24.5	Tr. Con. Kyphotic?	Skeleton # 1145.55
10.4	8.2	12.7	6	31	Fl. oblique.	Spec. # 1636.50
11	8.1	12.8	5.6	—	Fl. Oblique.	Specimen # 1636.30
9.5	7	11.5	7	—	Kyphotic?	Specimen # 1194.40
9.7	7.8	9.7	6.7	28	Flat. Rach.	Flat Rachitic see card Plate 33 - #7
8.2	6.7	7.5	5.	26	Flat. Rach.	Gelatinous - see card Plate 39 - #5
9.3	7.8	7.8	4.5	27	Gen. Con. Flat.	Osteomalacia - Hirst 1476 Plate 32 - #7
—	6	—	5.	22	Pseud. ost.	Missing
10	7.6	9.7	7.3	26.3	Fl. G. Con. obl.	Marry quite osteomalacia Hirst 1476 - Plate 32 - #5
5.4	5	4.1	7.2	18	Fl. G. con.	?
13.5	14.3	10.6	7	28.5	Fl. G. con.	Missing
11.6	9.8	13.2	8.5	31	Oblique.	Rachitic - bad double - crown. Plate 32 - #4 Hirst 1473
11	8	13.6	8.5	31	Justo major.	
10	11.8	—	10	24.5	Obtecta.	
12.5	9.2	14.2	7	27	Pseud. ost. early stage.	
11	9.5	11.8	3	26.5	Naegele.	Naegele - Plate 29 - #8 Hirst 1.13 - Plate 30 - #1 + Hirst
12.8	12	11	8	24	~~Robert.~~ Oblq. Cont.	+ Bonk - Plate 29 - #3
10	8	13.5	6.5	22.7	~~Pseud. ost.~~ Robert	

Dr. Douglas P. Murphy's identification of Pelves on pgs. 955-957, 959-961
Sections 17 and 18 -
Sept. 27, 1940
Shelf 5.

Shelf Position	Catalogue number	Type Pelvis
1	1365.27 1030 O.N.	Obliquely Contracted Pelvis (Naegele)
2	1365.26 1029-O.N	Obliquely Contracted Pelvis (Naegele)
3	1365.00 1014 O.N.	Obliquely Contra
4	1365.39 1066 O.N	Obliqu
5	1365.29 1032-O.N	Oblig
6	1365.13 —	Oblig
7	1365.12 (1636.50 spec number 1331 ?)	Oblig
1	1365.28 1031 O.N.	Trans (Robe
2	1365.38 1065-O.N.	Transv
3	1365.21 1025 O.N.	Osteom
4	1365.18 1024 O.N	Osteom
5	1365.41 1019-O.N.	Osteom
6	1365.34 1035-O.N	Osteom
7	1365.25 1028-O.N.	Osteomalacic Pelvis

1059.009 Egyptian Mummy p. 289 (p. 279)
But in the case in his letter [illegible]
He's labeling it is supposedly fine
to find a dead a "mummy"
"pucella Smith-Minter"
Asked Dr. Murphy, letter posted (pamphlet Sony)

Copied from badly torn page in the Catalogue.

1029.15 Sternum Presented by Dr. John H. Brinton.
1029.20 Sternum " " " "
1031.05 A thorax Presented by Dr. George McClellan.
1032.16 (A&B) Clavicle (verticle section) Presented by Dr. John H. Brinton.
1032.36 Clavicle Presented by Dr. John H. Brinton.
1032.37 " " " " "
1032.38 " " " " "
1032.39 " " " " "
1032.40 " " " " "
1032.41 " " " " "
1032.42 " " " " "
1033.21 Scapula (left) " " " "
1033.22 " (right) " " "
1033.23 " " " " " "
1033.24 " " " " " "
1033.25 " " " " "
1033.26 Portion of right scapula. Presented by Dr. John Brinton.
1033.30 Scapula and clavicle (right) " " "
1033.31 " " " " " " "
1035.10 Scapula, clavicle and upper portion of the humerus. Presented by Dr. John H. Brinton.
1035.15 Shoulder joint. Scapula, clavicle and humerus. Presented by Dr. John H. Brinton.
1036.05 (417) Humerus radius and ulna. Presented by Dr. John H. Brinton.
1036.00 Elbow joint. Presented by Dr. John H. Brinton.

Dr. Douglas P. Murphy's
identification of Pelves on pp. 955-957
959-961
Sections 17 and 18 -
Sept. 27 1940
Shelf 5.

Shelf Position	Catalogue Number	Type of Pelvis
1	1365.27 X 1030 6.n.	Obliquely Contracted Pelvis (Naegele)
2	1365.26 X 1029-6.n	Obliquely Contracted Pelvis (Naegele)
3	1365.00 X 1014 6.n.	Obliquely Contracted Infantile Pelvis
4	1365.39 X 1066 6 n	Obliquely Contracted Pelvis
5	1365.29 X 1032-6.n	Obliquely Contracted Pelvis
6	1365.13 X —	Obliquely Contracted Pelvis
7	1365.12 X (1636.50 Shelf number) 1331 ?	Obliquely Contracted Pelvis
		Shelf 6
1	1365.28 X 1031 6.n.	Transversely Contracted Pelvis (Robert)
2	1365.38 X 1065-6.n.	Transversely Contracted Pelvis
3	1365.21 X 1025 6.n.	Osteomalacic Pelvis
4	1365.18 X 1024 6.n	Osteomalacic Pelvis
5	1365.41 X 1019-6.n.	Osteomalacic Pelvis
6	1365.34 X 1035-6.n	Osteomalacic Pelvis
7	1365.25 X 1028-6.n.	Osteomalacic Pelvis

p. 25 b

1046.51 ✓ Femur, upper half, vertical section of the condyle Presented by Dr. John H.Brinton.

1046.52 ✓ Femur, vertical section Presented by Dr. John H. Brinton

1046.53 ✓ Femur, vertical section " " "

1046.54 ✓ (A&B) Femur, vertical section." " " "

1046.55 ✓ (A,B,C) Transverse section. Vertical section of the condyle. Presented by Dr. John H. Brinton.

1046.56 ✓ Vertical section of condyles. " " "

1046.57 ✓ " " " " " " "

1046.58 ✓ Transverse section of shaft. " " "

1046.59 ✓ Transverse section of condyle " " "

1046.60 ✓ Portion of Femur. Presented by Dr. John H. Brinton.

1046.61 ✓ Femur. Transverse section. " " "

1046.63 ✓ Femur. Presented by Dr. John H. Brinton.

1046.64 ✓ " " " " "

1046.65 ✓ " " " " "

1046.62 ✓ " " " " "

1046.66 ✓ Upper two thirds of the femur. Presented by Dr. John.H Brinton.

1046.67 ✓ Lower third of femur. " " "

1046.68 ✓ " " " " " "

1046.69 ✓ (260) Lower three fourths of femur. " "W " "

1046.70 ✓ (264) Upper third of femur Presented by Dr. JOhn H. Brinton.

1046.71 ✓ (265) Lower third of femur. " " " "

1049.41 X (A,B,C,D) Tibia, (Vertical section) " " "

1049.42 X (A,B,C,D) " " "

1049.65 X Tibia. Presented by Dr. John H: Brinton.

1049.70 X " " " " "

1049.75 ✓ " " " " "

Dr. Douglas P. Murphy's
identification of Pelves on pgs. 955-957, 959-961
Sections 17 and 18 -
Sept. 27 1940
Shelf 5.

Shelf Position	Catalogue Number	Type of Pelvis
1	1365.27 X 1030 O.N.	Obliquely Contracted Pelvis (Naegele)
2	1365.26 X 1029-O.N	Obliquely Contracted Pelvis (Naegele)
3	1365.00 X 1014 O.N	Obliquely Contracted Infantile Pelvis
4	1365.39 X 1066 O.N	Obliquely Contracted Pelvis
5	1365.29 X 1032-O.N	Obliquely Contracted Pelvis
6	1365.13 X —	Obliquely Contracted Pelvis
7	1365.12 X (1636.50 Spec. number) 1331 ?	Obliquely Contracted Pelvis
		Shelf 6.
1	1365.28 X 1031 O.N.	Transversely Contracted Pelvis (Robert)
2	1365.38 X 1065-O.N.	Transversely Contracted Pelvis
3	1365.21 X 1025 O.N.	Osteomalacic Pelvis
4	1365.18 X 1024 O.N	Osteomalacic Pelvis.
5	1365.41 X 1019-O.N.	Osteomalacic Pelvis
6	1365.34 X 1035-O.N	Osteomalacic Pelvis
7	1365.25 X 1028-O.N.	Osteomalacic Pelvis

		32-4													
1032	1365.29 X	Cast XV 31	12.5	13.6	—	5	7.2	8	11	10.5	10.5	17.5	23	6.7	29
	1365.30 missing	" XVI	8.5	10	12.8	3.6	6.2	7	8	7.5	7.2	17.5	18	6.8	30
1033	1365.31 X	31 "4 5	11.7	13.2	18.5	4.5	9.4	10	12.5	12.8	13.5	26	27.5	12.5	31
	1365.32 missing	11	4.4	8	12.5	4	6.2	5.5	11	11.5	13	27	28	8.8	32
1034	1365.33 X	31 "4 15	10.5	12	19	4	9	8.6	11.8	12.5	13	23	27.5	12.5	33
1035	1365.34 X	32 "4 22	3.5	5.8	15	4.5	2.3	5	10	9.3	12	23	21.5	10.5	34
1036	1365.35 X	R.G.C. 32.4 40	9	10.2	15.4	4	7.4	6	10.3	11.5	11.5	20.5	22	9.5	35
1037	1365.36 X	Jos. Scott 32.4 41	5	6.5	12.3	4	6	5.6	11.4	11	12.5	23.8	24	9.5	36

1365.37 X
1064. Case 32 Shelf 1. Pelv. models. no old no. - needs classification.

1365.38 X
1065 Case 32 Shelf 1 " " " " "

1365.39 X
1066. Case 31 Shelf 2. " " " " "

1365.40 X
1067 Case 31 Shelf 2 " " "

1365.41 - (Cast 21) Number given pelvis as it does not
1019 seem to fit the description of any of the pelves
casts that are missing.
Diagnosed as Osteomalacic by
Dr. Douglas P. Murphy - Sept. 27, 1940

Dr. Douglas P. Murphy's identification
of Pelves in Sections 17 and 18. Sept. 27, 1940

Shelf Position	Catalogue Number	Shelf 7. Type of Pelvis
1	1365.37 X 1064-O.N.	Pelvis with forward angulation of lumbar vertebrae.
2	1365.33 X 1034-O.N	Pelvis with outlet contraction
3	1374.00 X 1039-O.N.	Pelvis with extensive exostoses and with sacro-iliac ankylosis
4	1365.15 X —	Unknown (cast) Not Kyphotic.

12.5	10	16	11	25	Prend. ost.	29 Plate 35-#3
6.5	4.8	7.8	4	21	Infantile.	30
11.2	9	12.5	8	35	Normal.	31
10.2	11	8	5.3	27	Flat. Rach.	32
10	7	12.7	7.2	30.5	Nearly normal.	33
9.5	7.3	8.8	7	23.4	Prend. ost.	34
10.5	7	11.3	7.5	23.1	Gen. Cont.	35
8.5	7.5	8	7	26		36

1367- Pelvis. Fracture of the sacrum and
1038. left innominate.
32.
4. The first and second sacral vertebrae are crushed and the body of the pubes and ramus of the ischium are fractured.

1372- Pelvis; caries of the sacrum Presented by Dr. Mütter.
1372a05 Pelvis; caries of the sacrum Presented by Prof. George McClellan
Presented by " " "

1374- Pelvis. Exostosis. Anchylosis.
1039
31
5 The pelvis is large and all its margins are rough and prominent. The pectineal line is sharp and the margins of the acetabula pout. There is anchylosis of the sacro-iliac junction.

Purchased.

1374.10- Pelvis. Exostoses.
1040
31
5 Exostoses are seen on the left ischium and pubes. A large sulcus is seen in the left pubes 3 cm. from the symphysis. The pelvis is large and strong and there is ossification of the sacro-iliac articulation.

Purchased.

1382- Portion of left innominate bone. Multiple fracture. Recent.
1041
31
5 All the fractures lined communicate with

obturator foramen. The ramus of the ischium is fractured in its transverse diameter at the lowest portion of the obturator foramen. The ramus of the pubes is fractured in a line running from the angle downward and to the left. The acetabulum is fractured vertically and transversely at its inner half. The vertical line runs from the ileo-pectineal groove to the cotyloid notch.
H.H.S.

Purchased.

1382.08- Ilium of right side. Multiple fracture. (Pelvis)

1382.10- Ilium of the left side. Comminuted fracture. Recent.
1042
31
5

The bone has been separated nearly vertically and also transversely forming an inverted T shaped fracture. The longer fracture runs from a point just posterior to the highest point of the crest of the ilium downwards and forwards just posterior to the posterior edge of the acetabulum.

The transverse fracture skirts the lower border of the acetabulum.

For Fig. See Int. Encl. Surgery, Vol. IV, p. 94.

Presented by Dr. Mütter.

1006
1382.15 Pelvis. Fracture. see Vol. I Page 444

1382.20- Pelvis with fourth and fifth lumbar vertebrae.
1043
31
5

Fractures of the symphysis, body and r ramus of the pubes, of the ramus of the ischium; with sacro-iliac separation and fracture of the fourth body of the sacrum.
H.H.S.

Purchased.

1382.30- Portions of the innominated bone.
1044 Fracture of both ischii and pubes.
32
5

The body of the left pubes was fractured close to the acetabulum and is missing. The rami of both ischii were fractured at their middle; nothing remains on the left side and portions of the rami of the ischium and pubes of the right side are also missing.
H.H.S.

Purchased.

1382.40- Left innominate. Fracture of the body
1045 of the pubes, ramus of the ischium and
32 body of the ilium.
5

The body of the pubes was fractured at the middle, the ramus of the ischium close to the tuberosity and the ilium in a short line which enters the anterior portion of the greater sacro-sciatic notch.
H.H.S.

Purchased.

1382.45- Right innominate. Fracture of the
1046 ischium and pubes. Recent.
32
5

The body of the pubes and the inner lip of the acetabulum are fractured in a vertical line. Immediately below this fracture, in the same line, the ramus of the ischium is fractured.

Presented by Dr.W.S.Halsey.

1382.48- Right innominate. Fracture of the
1047 acetabulum and pubes.
32
5

Presented by Dr.A.S.Roberts.

1382.50- Left innominate. Old fracture. Ex-
1048 ostosis.
32
5

It has been doubtless an old fracture of the crest of the ilium. On both sides of the seat of fracture, especially the outer, there are exostoses. They point in a downward direction. There is also an exostosis of the pubes pointing outward.

Purchased.

1382.52- Left innominate. Fissure in the ace-
1049 tabulum.
32
5

There is a fissure in the superior portion of the acetabulum running toward the centre for a distance of 3cm.

presented by Dr.W.S.Halsey.

1389.25
~~1382.55~~-
1050
31
6

Right innominate. Coxitis.

The acetabulum is deformed and its capacity diminished by the inflammatory deposit.
H.H.S.

Purchased.

1394.05
~~1385~~-
1051
31
6

Left innominate. Eburnation.

The outer rim of the acetabulum is worn and eburnated as though by a subluxation of the femoral head.

Presented by Dr. Mütter.

1389.30
~~1387~~
1052
31
6

Left innominate. Coxitis.

The rim of the acetabulum is hypertrophied. The cotyloid notch is large, owing to the bone deposit at the margin.
H.H.S.

Purchased.

1387.10-
1053
31
6

Left innominate. Caries.

Between the spinous processes and the acetabulum, there is a large opening leading to a cavity involving a large portion of the cancellous tissue of the ilium.
Presented by Dr. W.S. Halsey.

1389- Left innominate. Exostosis.
1054
31
6

The anterior inferior spinous process is prolonged as an exostosis 3 cm. long. The acetabulum is large and shallow.

Presented by Dr. Mütter.

1389.05- Left innominate. Coxitis.
1055
31
6

The acetabulum is greatly changed. The margins are prominent and enfold the head of the femur so as to close tightly around the neck. The cavity is eburnated in places.

Presented by Dr. Mütter.

1389.10- Left innominate. Exostosis.
1056
31
6

The bone is heavy. The pubic portion is the seat of a large exostosis of irregular shape, 4.5 cm. long, projecting directly forward.

Presented by Dr. Mütter.

1389.15- Right innominate. Exostoses of the ischium.
1057
32
4

Presented by Dr. Mütter.

1389.20- Right innominate. Deformity of the acetabulum. Cast.
1058
32
4

The acetabulum is greatly altered.

Owing to inflammatory changes, it has a lateral measurement of 13, and a vertical measurement of 10 cm. Its cavity is irregular and arched bony deposits overhang it.

Presented by Dr. Mütter.

1389.25 see Vol I page 971
1389.30 see Vol I page 971

1393.05- Left innominate. Osteo-sarcoma.
1059
32
6

A large mass 20 x 13 x10 cm. lies on the external surface of the ilium. It is comparatively light, rough and vascular. The acetabulum is slightly roughened. The inner surface of the bone is intact.

Presented by Dr. Mütter.

1394- Fragment of the ilium. Changes in the
1060
32
6

acetabulum.

The margins are prolonged outward and upward, forming sharp prominences. The depression for the ligamentum teres is deep.
H.H.S.

1394.05 see vol I page 971 Purchased.

977

1397 Fractures of the Femur.

1397.0025 Ununited fracture of left femur
1095 through trochanters. Great exostosis
33
2
Presented by Dr A S Roberts

1397.000 Femur, Upper fifth. Left. Fracture
1061 of the neck;intracapsular.
33
C
1064
33
1

From a woman aged 73 who died on the fifth day after a fall on the ice.

Presented by Dr.T.S.K.Morton.

1397.001- Femur, Upper fifth. Left. Trans-
1065 verse fracture of the neck.
33
1

This fracture occurred close to the head and was caused by a crush. Portions of the compact substance of the neck are seen deeply imbedded in the substance of the head of the bone. No other portions of the bone are involved.

H.H.S.

Purchased.

1397.002- Upper half of left femur. Intra-
1066 capsular fracture of the neck. Ununited.
33
1

A prominent outgrowth of callus is seen pointing anteriorly below the head, but does not unite the fragments. The line of fracture passed almost vertically close to the head.
H.H.S.

Purchased.

1397.0025- Left femur, Intracapsular fracture
1094 of the neck, Ununited.
33
2

Presented by Dr.A.S.Roberts.

1397.003 - Femur;left. Intracapsular fracture of the neck.

1067
33
1

The fragments are ununited. The line of fracture is close to the head and is transverse. A portion of the capsular ligament holds the fragment in position.

Presented by Dr.R.H.Townsend.

1397.0035- Portion of femoral head. Intracapsular fracture.

1098
35
1

From a case of seven years standing.

Presented by Dr.W.G.Porter.

1397.004- Upper third of left femur. Intracapsular fracture of the neck. Ununited.

1068
33
1

The neck of the fracture has been absorbed,allowing the head of the bone to sink so as nearly to touch the trochanter minor and at its junction with the neck,to abut against the posterior intertrochanteric line. The fracture is wholly within the capsule. There is no bony union,but the fragment is held by the dried remains of the capsular ligament. A little callus has been thrown out anteriorly between the anterior intertrochanteric line and the seat of fracture.
H.H.S.

Purchased.

I397.005- Femur upper half;left. Conminuted fracture of neck and trochanter major.

1069
33
1

The head and neck forming one fragment, are depressed so as to form a right angle with the shaft,and are rotated on the axis of the neck,from above,backwards and downwards,so that the head lies against the trochanter minor. The superior portion of the trochanter major,forms a large triangular fragment. The neck is feebly joined to the shaft by recent callus, The fragment of the trochanter major is loose.

Presented by Dr.Mütter.

I397.006- Femur;right. Impacted fracture of the neck and trochanters.

1070
35
1

This specimen embraces five fragments well united. The trochanters form separate fragments. The head and neck are depressed, forming an acute angle with the shaft,in the cancellous portion of which this fragment is firmly held. The edges of the lower fragment,coincide with the spiral and intertrochanteric lines. The fifth fragment is small and lies between the trochanters, on the posterior surface.
From a man who had great shortening of the limb. Adduction was hindered by the contact of the trochanter,with the ilium.

Presented by Dr.R.H.Townsend.

1397.0065 Partial intracapsular fracture of right femur. Specimen shows partial epiphyseal separation. Donor D. H. Ellis

1072
35

I397.006- Femur;right. Impacted fracture of the neck and trochanters.

This specimen embraces five fragments well united. The trochanters form separate fragments. The head and neck are depressed, forming an acute angle with the shaft, in the cancellous portion of which this fragment is firmly held. The edges of the lower fragment, coincide with the spiral and intertrochanteric lines. The fifth fragment is small and lies between the trochanters, on the posterior surface.

From a man who had great shortening of the limb. Adduction was hindered by the contact of the trochanter, with the ilium.

Presented by Dr. R. H. Townsend.

985

I397.007- Femur;left. Upper extremity. Cast.

1071
35

Impacted fracture of the neck of the femur.

From a female aged, 84 years, who fell backward, and to the left, striking on the great trochanter. There was shortening of one inch. Rotation of the head of the bone in the socket, and of the trochanter crepitus not obtained. Foot inverted. The line of separation at the base, corresponds with the anterior and posterior ridges. The whole neck is strongly driven into the cancellated tissue of the trochanteric fragment, and forms somewhat less than a right angle with the shaft. The lesser trochanter is broken off and twisted inwards and forwards. There is a collar of bone about the head of the femur, the result of chronic arthritis.

See Columbus Med. Jour. November 1882. - 1: 197.
W. J. Conklin

Presented by Dr. Jhon B Roberts.

I397.008- Upper third of right femur. Fracture of lesser trochanter. Union.

1073
35

The neck points almost horizontally from the shaft. The fragment is triangular,

the sides measuring $2^{1}/_{4}$, 2 and $2^{1}/_{2}$ inches; it is immediately below the neck and posterior to it. Section of the bone has brought out the evidence of fracture. The fragment is well co-ossified with the shaft by compact tissue, with which the cancellated tissue of the fragment and its cavity present a strong contrast. The greater trochanter is very rough; the digital fossa is deep and shows signs of inflammatory changes.

Presented by Dr. Mütter.

I397.0081 992 Femur, upper third; right. Gunshot injury. See Vol I Page 445

I397.009- 1074 35 Femur; upper third; right. Oblique fracture of neck and trochanters. The anterior portion of the greater trochanter remains with the shaft. The posterior portion, with the trochanter minor, with the head and neck from the upper fragment. This is well united with the shaft.

Presented by Dr. Mütter.

I397.010- 1075 35 Upper extremity of left femur. Impacted and comminuted extra articular fracture of the neck and trochanters. Union.

This is a choice specimen. The upper fragment consisting of the head, after fracture has been depressed vertically and has been firmly impacted in the upper portion of the shaft. The line of fracture ran from digital fossa and superior attachment of the capsular ligament vertically, downward to the inferior attachment of the capsular ligament, close to the trochanter minor. Although following the line of attachment of the capsule, the fracture was extra-articular. Vertical section shows that the compact tissue of the under surface of the neck has been forced inwards across the medullary space, and lies abutted against the compact tissue of the shaft below the trochanter major. The medullary cavity is thus occluded at the level of the trochanter minor. The trochanter major has been crushed downward. A large fragment 9 cm. long, comprising both trochanters is united to the shaft. Its line of separation from the neck followed the posterior attachment of the capsule. The callus is rough, prominent and has not been rounded according to the custom of the bone. The fracture is apparently of long standing.
H.H.S.

Purchased.

1397.10 ✓ Pg. 1093
1397.10

✓ 1076
35
1

Left innominate and upper third of the femur. Fracture of the neck of the femur. False joint.

✓ A portion of the head remains in the accetabulum. Section of the innominate shows the femoral head in profile. The femur is straight owing to the loss of the head, and the absorption of the neck. It is quite irregular, and from being in contact with the pelvis laterally only, was made to support much weight.
H.H.S.

Purchased.

Pg. 1093 missing
1397.1015 ✓
1684
103
1

Head and neck of the femur. Fracture of the head and neck with iliac dislocation and fracture of the posterior edge of the acetabulum. The latter filled with fibrous material.

Railroad injury. Patient caught between bumpers. Excision of the head by Dr John B. Roberts at the Polyclinic May 1872. Case reported to the Surgical Section of the College of Physicians Oct. 1895 & Annals of Surgery.

Presented by Dr. Roberts.

23: 207, 208, 1896

1397.10 Pg 1093
1397.10 Left innominate and upper third of
1076 the femur. Fracture of the neck of the
35 femur. False joint.
1

A portion of the head remains in the accetabulum. Section of the innominate shows the femoral head in profile. The femur is straight owing to the loss of the head, and the absorption of the neck. It is quite irregular, and from being in contact with the pelvis laterally only, was made to support much weight.
H.H.S.

Purchased.

Pg. 1093 missing
1397.1015 Head and neck of the femur.
1684 Fracture of the head and neck with iliac
103 dislocation and fracture of the posterior
1 edge of the acetabulum. The latter filled with fibrous material.

Railroad injury. Patient caught between bumpers. Excision of the head by Dr John B. Roberts at the Polyclinic May 1872. Case reported to the Surgical Section of the College of Physicians Oct. 1895 & Annals of Surgery. Presented by Dr. Roberts.
23: 207, 208, 1896

Surg Sa Col - 1895
Annals of Surgery
Roberts

I397.0II- Femur, upper third; left. Fracture through the condyles.

1077
31
1

The upper fragment consists of the head, neck, inner portion of the great trochanter, and trochanter minor. The two fragments are firmly welded together by abundant callus, thick and prominent ridges of which are seen on the inner and posterior surfaces, about the line of fracture. The head points upward and backward and is wholly below the level of the trochanter major.

Presented by Dr. Mutter.

I397.0I2- Upper third of left femur. Comminuted fracture of the neck and trochanters. Recent.

1078
35
1

There are nine fragments in the specimen. The head and neck form one fragment, having been broken close to the line of insertion of the capsular ligament. The trochanter major was severely crushed into several pieces. Below it on the posterior side there is a large fragment whose anterior margin is the inter-trochanteric line, and whose lower tip is the trochanter minor; it has a width of 4 cm. and a length of 8 cm. Several small fragments are distributed

along the posterior inter-trochanteric line. A remnant of the capsular ligament encircles the neck of the femur.

Presented by Dr. Mütter.

I397.013- Upper fifth of left femur. Impacted comminuted fracture of neck and trochanters.

1079
35
1

The fracture is long standing. The head and neck are depressed, forming a right angle with the shaft. The greater and lesser trochanters are imbraced in one cresentic fragment, firmly united by permanent callus with the upper and lower fragments. This was doubtless an impacted fracture. A long sharp outgrowth of callus projects below the neck, inward and forward.

Presented by Dr. Mütter.

I397.014- Cast of above.

1080
35
1

I397.015- Upper third of right femur. Fracture of the neck.

1081
35
1

Presented by Dr. Mütter.

I397.015f. Left ilium and upper half of the femur. Fracture of the neck.

1081
35
1

The neck of the femur has been fractured, apparently transversely and remains in the acetabulum. The femur at the point of fracture has undergone softening and there is loss of substance of the neck.

Presented by Dr.Mütter.

Destroyed

I397.0I6- Plaster cast of united fracture of the neck of the femur.

1082
34
1

Purchased.

I397.0I7- Plaster cast of united fracture of the neck of the femur.

1083
34
1

I397.0I7- Upper third of left femur. Comminuted fracture of neck,trochanters,and shaft.

1084
34
1

This is a fine specimen with firm union. The upper fragment embraces the head,neck, trochanters and a portion of the posterior half of the shaft,terminating I5 cm. from the top of the trochanter major. The fracture is of very long standing. Union has been obtained in very good position. In the callus which is generally smooth, there are in places pockets and bridges.

Presented by Dr.Mütter.

I397.018- Upper third of right femur.
1085
34
1
The head and neck are not present. The upper surface is eburnated as though there had been a false articulation with the upper fragment, fracture possibly having taken place above the inter-trochanter line.

I397.020-(I) Right femur. Oblique fracture through the trochanters.
1086
34
1
The line of fracture is marked by thick and prominent ridges of callus. The head and neck are depressed, forming an acute angle with the shaft.

I397.021- (B) Left fracture of the neck only. Intracapsular.
1087
34
1
The head points backward. No callus is apparent.

I397.022- (C) Right comminuted fracture of neck and trochanters.
1088
34
1
The neck is depressed forming a right angle with the shaft. Lines of fracture are marked by prominent ridges of callus.

Purchased.

I397.023- Femur; right. Impacted fracture of neck.
1089
34
1

The head and neck are depressed to a right angle with the shaft, in which the neck is firmly lodged. The head lies within half an inch of the trochanter minor. The trochanter major is apparentely split, the neck lying like a wedge between the posterior and anterior portions. The line of fracture passes through the digital fossa and spiral line. Prominent exostoses are seen below the trochanter minor.

History; furnished by Dr. W.S. Forbes.

The patient was a day laborer. Six years before his death, which was caused by typhoid fever, he had fallen into a cellar and injured his hip. He afterward always walked very lame.

Purchased.

1402.35 Vol. 1 Pg 1105

~~1397.025~~- Upper extremity of right femur. Caries.

1090
35
2

The head and upper portion of the neck are missing. Whether there has been a fracture with absorption or loss of the upper fragment or whether there has been destruction of the neck by caries, it is difficult to say. The remaining portion of the neck consists of a crater-like stump, having thinwalls and a deep concavity. There is no

communication with the medullary canal; the bed of this cavity is of indurated spongy tissue. Vertical section shows a medullary cavity bounded above by loose spongy tissue, having large inter-trabecular spaces.

Presented by Dr. Mütter.

I397.0255- Right femur. Fracture of the neck.

1091
35
2

Presented by Dr. A.S. Roberts.

I397.026- Right femur. Fracture at the trochanters. Union. Exostoses of the shaft.

1092
35
2

The fracture is one of long standing, and the process of repair has rendered the exact site of fracture doubtful. It would appear that the upper fragment embraced the head, the neck, the great trochanter and about 8 cm. of the anterior shaft. The lesser trochanter probably belonged to the lower fragment. The upper fragment lies in front of the lower, and presents a slight anterior deformity. The sliding of the fragments upon each other, and the process of absorption have brought the lesser trochanter to within 8 mm. of the margin

of the head. The inter-trochanteric line is distinguished by a prominent ridge of callus, expanding as it approaches the great trochanter. Anteriorly the neck of the bone rises almost to the level of the shaft into which it is merged. This change in the neck has brought the head of the bone and the great trochanter to the same level. The bone is convex-anteriorly immediately below the great trochanter.

An exostosis is seen in the shaft anteriorly and in the upper portion of the middle third. Its greatest breadth is 2.5 cm. and its length 10 cm. Its shape is that of the proboscis of an elephant, being directed downward and re-inserted after bridging 5 cm. of the shaft. The walls of this exostosis are thin and filled with light spongy tissue.

Another exostosis is seen on the outer side of the apex of the popliteal surface. It has a broad base 3.5 cm. long, is 1.5 cm. high, and is directed backward and outward. The anterior and lateral surfaces of the shaft are marked by fine linear striations. The lower fragment is rotated outward 30°.

Presented by Dr. Mütter.

I397.027- Right femur. Fracture of the neck; intracapsular. Union.

1093
33
2

Viewed externally the anterior surface of the neck is seen to be partly covered with callus, which is rough and full of vascular openings. The head is I cm. below the top of the trochanter and between them is a thick ridge of callus rising nearly as high as the trochanter. The head of the bone lies close to the lesser trochanter, a fissure of from one to two millimeters separating them. The head is not eburnated. The digital fossa is marked by a deep central depression. Vertical section shows a line of compact tissue, from one to four millimeters broad marking the junction of the fragments. This line is 4 cm. long and runs from the fissure between the head and lesser trochanter, upward to the junction of the head and neck. The spongy tissue about this line, and in the upper portion of the head, is indurated. The same may be said of the spongy tissue of the lesser trochanter. The medullary cavity is open. An osteophyte, flat, and measuring 2 by 3 cm. lies just above the inner tuberosity.

Presented by Dr. Mütter.

1404.051 Page 1113-Vol. 1 number changed

~~1397.028~~- Femur;upper third;left. Arthritis.

1096
35
2

The head,neck and trochanters are deformed by long standing arthritis. The articular surface is rough,especially posteriorly and in its under surface;the trochanters present ridges of callus simulating permanent callus after fracture. Section of the head and neck shows cavities whose cheesy contents have escaped into the joint.

Purchased.

I397.029- Oblique fracture of the upper shaft and trochanter minor. Union with deformity.

1097
35
2

The fracture of the shaft commenced high up, close to the neck and passed from the anterior surface downwards and backwards through IO cm. of vertic~~ele~~al extent. The lesser trochanter was also broken off. The lines of callus about the fracture are smooth,but in the inter-trochanteric lines they are prominent. A small bridge of callus connects the tip of the lower fragment with the anterior inter-trochanteric line. There is the usual upward tilting of the upper fragment,but no rotation of the condyle.

Presented by Dr.Mütter.

I397.030- Right femur. Obliqe fracture of the
1099 upper shaft. Union with deformity.
35
2 The upper fragment embraces one fourth of the bone;it is tilted forwards and upwards so that,in placing the lower fragment perpendicular, the greater trochanter rises I3 cm. above the neck. ~~The lower fragment backward and upward.~~ The uniting callus forms a bridge between the fragments posteriorly and is prolonged anteriorly from the upper fragment as an exostosis. The shaft of the bone is strong and is thickened laterally.

Presented by Dr.Mütter.

I397.03I- Right femur. Fracture of the neck,
1100 trochanter major and shaft. Recent.
35
2 The injury was a severe one in which,while the trochanter was fractured by direct violence,the shaft was probably broken by twist leverage being obtained at the knee. The upper fragment consists of the head,neck trochanters and a portion of outer shaft terminating in a point. Passing from this point I3 cm.below the great trochanter we trace a line passing spirally

upward and backward below the trochanter minor, then through the anterior intertrochanteric line nearly to the top of the great trochanter; thence the line passes downward to the point of starting. Looking at the external surface of the great trochanter a Y shaped fracture is seen. The anterior horn of the Y passes along the line of insertion of the capsular ligament, through the digital fossa, passing just above the posterior intertrochanteric ridge, nearly to the trochanter minor.

Presented by Dr. Mütter.

I397.032- Right femur. Oblique fracture of the upper shaft. Union with anterior angular deformity. (Plaster cast)

1101
35
2

The plane of fracture passed from the outer side just below the great trochanter downwards and inwards below the trochanter minor. The upper fragment has been tilted upward. The fragments have united firmly but their axes deviate 30° from a straight line. The lower fragment has rotated outward 45° .

H.B.Tuson, Lon. Fecit.

Purchased.

I397.033- Right femur. Oblique fracture below
1102 the trochanters. Union with deformity.
35
2 The upper fragment embraces both trochanters.
The plane passed from a point on the outer-
side near the great trochanter downward
and inward to a point just below the tro-
chanter minor. Firm union is established.
By the action of the glutens minimus and
medius on the great trochanter the upper
fragment has been drawn up and the lesser
trochanter drawn forward. The axis of the
neck and that of the shaft ~~from~~ form an angle
of 90°. The callus posteriorly is rolled
over in the form of scrolls; anteriorly
it is smooth. The linea aspera is well
marked.

Presented by Dr.Mütter.

I397.034- Upper two thirds of left femur.
1103 Fracture of the upper shaft. Union
35 with anterior angular displacement.
2 (Plaster cast).

The lower fragment passed upward and back-
ward;the upper fragment tilted upward
and forward. The fragments have united
at a deviation of 42° from the normal line.
The callus is smooth. Vertical section
shows obliteration of the medullary cavity.
H.B.Tuson,Fecit.

Purchased.

I397.035- Right femur. Fracture of the upper shaft. Union with anterior angular deformity.

1104
35
2

The fracture occured at the junction of the middle and upper thirds, and was probably nearly transverse. The psoas magnus and the internal iliac muscles have elevated the end of the upper fragment 55° so that the bones have united with great anterior deformity. The prominence consists of the extremity of the upper fragment. This has been rounded off and the medullary cavity closed excepting for a small opening having a diameter of 5 cm. The lower fragment has passed upward and backward. Its extremity is well covered with compact tissue. There is no outward rotation of the lower fragment.

Presented by Dr. Mütter.

I397.0355- Upper extremity of left femur. Oblique fracture of the shaft below the trochanters. Necrosis.

1105
35
2

The fracture passed from a point 4 cm. below the great trochanter downward and inward. There are slender bands of callus on the anterior surface uniting the fragments.

The upper fragment was in a state of necrobiosis. Two thirds of the surface of the head is intact. The remaining third, situated posteriorly and the neck have undergone absorption and have very slender union with the greater portion of this fragment which is itself extremly frail and ready to crumble. No compact tissue remains. The spongy tissue is very light and porous, almost feathery in its structure. The lower fragment was itself undergoing a process of absorption on the inner surface.

Presented by Dr. Mütter.

I397.036- Left femur and innominate. Fracture
1106 of the neck without union; fracture
35
2 of the shaft; united.

The upper fragment consists of the head and neck. The lines of fracture passed from the digital fossa vertically downward 6 cm. curving to the inner side and emerging immediately above the trochanter minor. This fragment having a length of 10 cm. and a width of from 4 to 5 cm. has remained ununited and rests in a socket, a new articular cavity having been formed,

in which motion must have been limited. The cancellated tissue of the lower end of the upper fragment is indurated and may even be termed compact. The shaft was broken II cm. below the great trochanter. There is an outward angular deviation of 22° from a straight line. On the inner side and immediately below the upper fragment there is a mass of callus about IO cm. long, pointing forward and upward apparently springing from the trochanter minor. The apex of this prolongation is situated equidistant from the pubis and anterior inferior spine, being connected with the latter by means of a ligamentous band 6 cm. long. This band may be the remains of the tendon of the rectus femoris muscle.

I397.037- Right femur. Oblique fracture of the upper shaft. Recent. (Plaster cast).

1107 34 2

Starting from a point in the external aspect of the shaft, 3 cm. below the great trochanter, two lines of fracture diverge; one passes downward and obliquely anteriorly across the shaft to a point in the linea aspera at a level I3 cm. below the point of commencement. The other line of fracture passes obliquely downward and backward to the same point in the linea aspera. H.B.Tuson, Fecit.

Purchased .

I397.038- Left femur. Oblique fracture of the upper shaft. Union with anterior deformity.

1108
34
2

The fracture occured at the junction of the middle and upper thirds and the plane passed from behind, downwards and forwards. The iliacus internus and psoas magnus muscles have tilted the superior fragment upward presenting an angular prominence. The angular deviation from the normal line amounts to 30°; the outward rotation of the lower fragment, 22°. The callus is smooth at the seat of fracture. Vertical section made antero-posteriorly shows the deformity well. The medullary cavities of the fragments are separated by a septum of indurated compact tissue. The posterior portion of the compact tissue of the lower end of the upper fragment forms a part of this septum.

Presented by Dr. Mütter.

I397.039- Left femur. Fracture of the upper shaft. Union with anterior angular deformity. (Plaster cast).

1109
34
2

The fracture occured below the junction of the middle and lower third. The extremity

of the lower fragment is tilted forward and upward and is strongly united to the lower fragment with an angular deviation of 32° from the normal line. Vertical section shows a thick septum between the medullary cavities.

H.B .Tuson fecit.

Purchased.

I397.0395- Upper two thirds of femur. Oblique fracture of the upper shaft and of the trochanters.

1110
34
2

Presented by Dr.A.S.Roberts.

I397.040- Upper two thirds of right femur. Oblique fracture of the shaft. Union in bad position. Sequestrum in situ.

111
34
2

This is a striking specimen. The fracture occured at the junction of the upper and middle thirds and passed from before downwards and forwards. The fragments had united by slender bridges of callus presenting an external angular deformity. The lower fragment lies behind and upon the inner side of the upper fragment.

The fragments were united by two bridges of callus. The inner one is 3 cm. long 2 cm. wide and I cm. thick. These bands of callus were too frail to support the limb, there being a vacant space between the bands capable of receiving the little finger.

The medullary cavity of the upper fragment is nearly closed at a point 2 cm. from the extremity. The extremity of the lower fragment is open and in the medullary cavity a sequestrum is seen which is not yet loose, having a length of 7 cm. The upper end of the lower fragment is thickened by callus and periosteal deposit. There is a small opening on the anterior side of this fragment through which the sequestrum may be seen. The head and trochanters of the specimen are broken away by violence probably rather than disease.

Presented by Dr.Mütter.

I397.04I- Plaster cast of a specimen of fracture below the trochanters.

1112
34
2

I397.042- Plaster cast of a specimen of fracture through the trochanters.

1113
34
2

1404.50 Vol I. C. 1155

~~1397.043~~- Left femur. Exostosis.

1114
34
2

This is a striking specimen. The exostosis is exhuberant. It is 23 cm. long;has a thickness of from 4 to 6 cm. and is situated on the anterior and inner surface of the upper shaft. It was evidently of rapid growth. The outline is irregular and the deposit has a friable porous appearance resembling pumice stone. It does not progress beyond the linea aspera;it reaches a trifle higher than the trochanter minor.

Vertical section shows,that the disease is wholly on the outside of the original bone,the latter appearing perfectly healthy. The exostosis shows in section a close, spongy structure abounding in vascular channels.

H.H.S.

Purchased.

I397.044- Right femur. Fracture of the upper shaft. Union with the anterior angular deformity.

1115
34
2

The upper fragment consisted of the upper fourth of the bone. Strong union has occured with a thick but smooth and lustrous

deposit of callus. The deviation of the fragments from the natural line is 30°; the outward rotation of the lower fragment 25° .

Presented by Dr.Mütter.

I397.045-
1116
34
2

Right femur. Oblique fracture through the great trochanter and upper shaft. Union. (Plaster cast).

The upper fragment includes the head,neck, trochanter minor,the posterior half of the trochanter major and a portion of the posterior shaft. Another long fragment probably consisted of the upper and outer third of the shaft with the anterior portion of the great trochanter. This fragment broke from the upper fragment in the anterior intertrochanteric line. In the latter fragment the head and great trochanter are on the same level. The lower fragments overlap and are united with a slight anterior curvature,and with excrescences of callus posteriorly.
H.B.Tuson Lon. fecit.

Purchased.

I397.046- Left femur. Fracture of the upper shaft. Union with anterior angular deformity.

1117
34
2

The condyles have been removed from the specimen. The fracture occured at the junction of the first and second quarters. The lower fragment passed upward and backward; the extremity of the lower fragment has been tilted forward and upward and has united with an angular deviation of 33°. The union is strong and the callus smooth.

Presented by Dr. Mütter.

I397.047- Right femur. Oblique fracture of the upper shaft. Union with deformity.

1118
34
2

The fracture occured at the junction of the middle and upper third. The plane passed obliquely from the inner side downwards and inwards. The psoas magnus and internal iliac muscles have tilted the upper fragment forward and the fragments have united firmly, deviating 35° from a straight line and with an outward rotation of the lower fragment of 70°.

The callus is smooth excepting posteriorly. The bone is flattened at the anterior

prominence. Numerous superficial vascular channels are seen coursing over the bone, especially on the posterior side. There has been arthritis of the knee-joint. The borders of the articular surface are fringed with callus. The surface for the patella has been extended upward and on the outer side and is eburnated. Vertical section shows beautifully the repair. A septum of indurated spongy tissue passes obliquely downward from the outer to the inner side. The medullary cavity on either side of this septum is free.

Presented by Dr.Mütter.

I397.048- Right femur. Fracture of the upper shaft. Union with shortening and deformity. The fracture was probably oblique and perhaps comminuted judging from the appearence of the bone on the inner side of the seat of fracture. The lower fragment has passed upward and backward. The upper fragment presents a prominence anteriorly projecting 3 cm. in front of the lower fragment. A portion of the bone resembling a small

fragment 4 by I.5 cm. lies on the inner side of the seat of fracture and is united with the main fragments. The callus covering the lower fragment is comparatively smooth;that over the lower fragment is jagged but the medullary cavity is closed. The angular deviation of the fragments from a straight line amounts to 30°;the outward rotation of the lower fragment 35°.

Presented by Dr.Mütter.

I397.049- Right femur. Transverse fracture of the shaft above the middle. Union. Shortening and deformity.

1120
34
2

The bone is healthy and firm union has occurred with little permanent callus. There is,however,considerable deformity. The upper fragment lies immediately in front of the lower fragment and over laps it 5 cm. Below the end of the upper fragment there is a sudden depression. The lower fragment presents a marked prominence posteriorly;its rotation outward,amounting to I00°,is a serious deformity. The callus which covers well the broken ends,is smooth and has the lustre of the compact tissue

of the shaft. Three small spicules point upward posteriorly.

Presented by Dr.Mätter.

I397.050- Right femur. Oblique fracture of the middle shaft. Union. (Plaster cast).
1121
34
2
The lower fragment has passed upward and backward. The callus is well rounded and smooth. There is a slight outward rotation of the foot of I5°. The line of the bone is good and the union strong.
H.B.Tuson fecit.

Purchased.

I397.05I- Right femur. Oblique fracture of the upper shaft. Frail union with remarkable disposition of callus and ostitis of the upper extremity.
1122
34
2
This is the most striking specimen to be found in this collection. The fracture was very oblique passing from the outer and upper portion of the shaft downwards and inwards through about I5 cm. of vertical extent. Frail union has taken place with considerable shortening,with a wide lateral separation of the fragments and an angular

deviation from the normal line of I5°.
The upper fragment is in a state of ostitis.
The head and trochanters are friable, rough and porous. The inflammatory process in the head is seen chiefly posteriorly.
The sharp extremity of the lower fragment touches the upper fragment below the great trochanter on the outer side. This surface, 5 cm. square, is the only point where the fragments join except by means of broad and long bridges of callus. A broad, rough surface of callus lies on the anterior and outer surface of the upper fragment.
A broad bridge of callus having a length of 8 cm. above and I0 cm. below and a breadth of 3 cm. binds the fragments together anteriorly. The extremity of the upper fragment is united to the shaft of the lower fragment by a bridge of callus 8 cm. long and 3 cm. broadand having a thickness of 5 cm. The inner surface of the callus and of the fragments is rough and very irregular. The medullary cavity of the upper fragment is open and may have contained a sequestrum. The outer surfaces are comparatively smooth. The medullary cavity of the lower fragment is open but

is loosely filled with a light spongy tissue at the upper extremity. The lower extremity is broken off and shows a large free medullary cavity bounded by thin walls of compact tissue.

Presented by Dr.Mütter.

I397.052- Right femur. Oblique fracture of
1123 the middle of the shaft. Union with
33 deformity and shortening.
2

The fracture occured exactly at the middle and the plane passed from the posterior and inner side,downwards,forwards and outwards. The upper fragment lies above and on the outer side of the lower fragment. The latter forms a decided prominence on the inner side while the upper fragment is prominent on the upper and outer side.

Union is strong and the callus not superabundant. The end of the lower fragment is smooth. The end of the upper fragment is covered with porous spongy substance but in neither case is the medullary cavity exposed. The shortening probably amounts to about 5 cm. There is outward rotation of the lower fragment amounting to 40°.

Presented by Dr.Mütter.

1045

missing

I397.053- Right femur. Transverse comminuted fracture of the middle shaft. Recent.

1124
34
2

The bone was fractured just below the middle. The violence evidently acted directly;there is no splitting of the shaft. The small comminuted fragments have been lost. The outer condyle is also crushed in.
H.H.S.

Purchased.

I397.054- Left femur. Fracture of the middle shaft. Union with great shortening and deformity.

1125
34
2

The fracture occured below the middle . The lower fragment passed to the inner side and upward and backward. The fractured endsare I3 cm. distant from each other. The uniting callus forms a smooth rounded knob posteriorly;anteriorly there is a depression at the line of union. The fractured ends of the fragments have been injured by handling. The spongy tissue has a black color. The lower fragment has not rotated.

Presented by Dr.Mütter.

I397.055- Right femur. Transverse fracture of the
1158 middle shaft. Recent union.
33
4

The fracture occured just above the middle. The lower fragment passed upward to the inner side and slightly backward. The shortening amounts to 5 cm. the displacement of the lower fragment inward amounts to the thickness of the bone. The lower fragment has rotated outward 20°.

The uniting callus is recent; the bone must have been removed not long after, not many weeks after the fracture. The medullary of the upper fragment is closed; that of the lower fragment still presents a small opening. The callus is of a light brown color, friable and has the appearance of pumice stone. The vascular channels are large and numerous and give the callus in places a worm-eaten appearance. The contrast between the friable vascular callus and the compact tissue is marked.

Presented by Dr. Mütter.

1397.0555 Right Femur. Transverse Comminuted fracture of the middle shaft. Recent.
Presented by Dr. Mütter.

I397.056- Femur; left. Oblique fracture of
1126 the shaft. Union.
35
3

This is an old specimen showing firm union of long standing. The upper fragment

overlaps the anterior and external surfaces of the lower, producing a smooth and well rounded prominence on the externaland posterior aspects of the shaft. Shortening has occured without rotation.

Longitudinal section of the bone shows the original compact tissue of the fragments encased in a generous sheath of new bone made up of cancellated and compact tissue.

Purchased.

I397.057- Right femur. Fracture of the middle shaft. Union with shortening and anterior deformity.

1127
35
3

The lower fragment has passed upward and backward. The shortening probably amounted to about 4 cm. The fragments have been united with smooth firm callus which has left no openings into the medullary cavity. There has been a slight arthritis at the knee-joint. The line of the bone is good and there has been no rotation of the lower fragment.

Presented by Dr.Mütter.

I397.058- Left femur. Fracture of the middle shaft.

1128
35
3

There is great shortening and anterior angular deformity. Sharp prominence of the upper fragment.

Purchased.

I397.059-
1129
35
3

Right femur. Fracture of the middle shaft. Union. Outward deformity.

The bone is small and has been fractured in the middle of the shaft. Considering the upper fragment fixed in its proper position, the lower fragment may be said to deviate 25°, its lower extremity being carried to the inner side. Firm union has occured. The lower end of the upper fragment is open and a clear view of the medullary cavitymay be had, the trochanter having been broken off by rough handling. The fractured end of the upper fragment had evidently not been perfectly repaired. Grooves on the outer side of the bone show well the course of the vessels and are evidence of great vascular activity.

The condyles are rough, especially on the outer one, showing evidences of arthritis. The head and neck of the bone have suffered from ill usage. There is outward rotation of the lower fragment amounting to less than 10°.

Presented by Dr. Mütter.

I397.060- Upper two thirds of right femur.
1130
35
3

Oblique fracture of the middle shaft.

Union.

The fracture occured in the middle of the shaft and passed from the outer side downwards and inwards through 10cm. of vertical extent. Strong union has occured in fairly good position. There are several openings at the seat of union. The callus is smooth except posteriorly where a prominent spicule projects.

Presented by Dr. Mütter.

I397.061- Right femur. Fracture of the middle
1131
35
3

shaft. Union with outward angular deformity.

The lower fragment passed upward and backward. The extremities are well covered with smooth lustrous compact tissue. The fragments have united at an angle of 35° and with an outward rotation of the lower fragment of 30°.

Vertical section shows obliteration of the medullary cavity at the seat of fracture by two oblique bands of compact tissue having a thickness of 5 cm.

Presented by Dr. Mütter.

I397.062- Upper third of right femur. Transverse
1132 fracture of the shaft. Recent.
35
3 The bone is from a well developed adult. The fracture occured at the junction of the upper and middle thirds, and resulted probably from direct violence. Lines of fracture extend upward from one to two inches, and are marked by osteophytes one of which embraces a splintered fragment of bone. The bone was evidently removed shortly after the injury.

Purchased.

I397.0625- Femur; right; recent fracture; exostosis
1133 on upper and lower fragment.
35
2 This man died 24 hours after having been injured by a rail-road car; the wheel going over the limb. The soft parts were very much lacerated. He died from shock.

Purchased.

I397.063- Model of a specimen of fracture of
1134 the neck.
35
3

I397.064- Left femur. Oblique fracture of the
1135 middle shaft. Union.
35
3

The bone is a strong one. The fracture passed obliquely from behind downward and forward. Strong union has occured with posterior and upward displacement of the lower fragment. The callus is smooth, not superabundant, and is marked by vascular grooves. There is an opening near the extremity of the upper fragment leading to the medullary cavity. The lower fragment is perfectly sealed with compact tissue. The lower fragment points slightly inward and downward and has rotated very slightly inward. The anterior aspect of the head of the femur is slightly flattened near the junction of the head and neck.

Presented by Dr.Mütter.

I397.065- Right femur. Oblique fracture of
1136 the upper shaft. Union.
35
3

The plane of fracture was nearly verticle passing from a point 5 cm. from the top of the trochanter major to a point in the linea aspera 20 cm.from the point of starting. The bone presents at the anterior and upper portiona gentle convexity and on the inner side is slightly irregular. Verticle section shows a more

or less complete septum defining the course of the fracture. The septum is thin and mostly of a cancellous tissue.

Presented by Dr.Mütter.

I397.066- Right femur. Oblique fracture of the
1137 middle shaft. Union.
35
3 The fracture occured above the middle. The upper fragment is tilted forwards, the lower fragment passing behind. There is therefore a slight prominence anteriorly. The lower end of the lower fragment is directed to the inner side I5° and rotated outwards I0°. The callus is smooth and strong and without external openings. In the digital fossa there was a small excavation, now healed by compact tissue.

Vertical section shows beautifully the repair of fracture. The medullary cavity of both fragments are open but between them passing obliquely from the posterior side downwards and forwards is a septum of indurated spongy tissue. This septum in section has a rhomboid shape, its sides measuring 9 cm. and 4 cm. and its thickness 3 cm. There is a strong contrast

between the delicate friable spongy tissue near the condyles and that at the seat of fracture.

Presented by Dr.Mütter.

I397.067- Upper half of left femur. Gunshot fracture of the shaft.

1138
35
3

The bone is shattered at the middle and lower third. Besides the upper fragment which embraces the head,neck and upper shaft there are six long and narrow fragments from the shaft. The ball is heavy and flattened.

Presented by Dr.Mütter.

I397.068- Left femur. Fracture of the shaft below the middle. Union with shortening and deformity.

~~1139~~ 2
34
1134 3

Thelower fragment,which is slightly shorter than the upper fragment,has passed upward and backward. The fragments have united in bad position;the lower fragment points downward and inward I5°;and has rotated inward 28°. The fragments are firmly united by callus which,however fails to cover the end of the lower fragment. The end of the upper fragment is rough and porous.

Presented by Dr.Mütter.

I397.069- Left femur. Comminuted intercondy-
1140 loid fracture. Union with deformity.
34
3 (Plaster cast).

The condyles were split so that the outer fragment is the smaller. The shaft was broken obliquely immediately above the condyles, from behind downward and forward, the fragments comprising the condyles passing upward and backward. The lower portion of the shaft was split. A fragment I7 cm. long, comprising nearly the entire thickness of the shaft has united in a bad position. It points downward and outward and presents an anterior prominence. In its union with the condyles the latter have rotated outward 30°.
H.B.Tuson fecit.

Purchased.

I397.070- Right femur. Oblique fracture of
1141 the lower shaft. Union with deformity.
34
3 The fracture occured at the junction of the middle and lower thirds. The plane passed from behind downwards and forwards. The lower fragment passed upward and backward and has united with the upper fragment at an angle of 30°, and producing an external angular deformity. There is no outward

rotation. The union is strong and the callus smooth. On the inner side there is a small osteophyte and posteriorly there are several small channels leading into the interior.

The condyles show evidence of arthritis. The margins of the articular surface are prominent and curled. This is chiefly noticeable on the inner side.

Presented by Dr.Mütter.

1397.071 1142 34 3

Left femur. Fracture of the lower shaft. Union with deformity.

The fracture occured at the junction of the middle and lower thirds and was probably nearly transverse. The lower fragment points inward 10° but has not rotated. It has passed upward and backward and has united firmly. The upper fragment presents a prominence anteriorly while the lower fragment projects on the outer side. The inner side of the line of junction is grooved;anteriorly there are numerous vascular openings;posteriorly it is rough.

Presented by Dr.Mutter.

V IX
1160
35
4

I397.072- Femur;right. Comminuted oblique fracture of shaft. Union.

The bone is large and well marked; length,twenty one and a half inches. The union is in fair position and shortening, slight. A prominent feature of this specimen is a fragment of the external portion of the shaft,six inches long,which is firmly united to the upper and lower fragments. The latter are throughly co-ossified at a very slight deviation from the natural line,bowing slightly outwards and the portions of the original bone present no serious change. The lines of union are marked, especially posteriorly,by slight hyperostoses. Anteriorly the lines of union are well rounded off. Between the lower and external fragment are openings leading to the interior of the lower shaft.

Male aet. 32. Fracture caused by a cart wheel. Patient treated with long splints of Desault as modified by Physick and Hutchinson. He made an excellant recovery and had a perfectly useful limb. He died two years afterwards and the specimen was obtained.

Purchased.

I397.073- Femur; right. Transverse fracture.
1161
35
4
Union with overlapping and deformity.
The fracture is strongly united.
The upper fragment overlaps the lower by two and a half inches. A long and sharp point of callus is seen on the inner side of the line of union. Between the two fragments a canal is seen large enough to admit a pencil, which has suggested that a seton may have been used in treatment.
Given to Dr. Forbes by Lauschbeck of Berlin.

Purchased.

I397.074- Upper two thirds of right femur.
1143
34
3
Fracture of the shaft. Necrosis.
The bone is from a young man; the epiphyses have not yet wholly united. The inner layer of compact tissue seems to have been in process of separation after fracture. It is paler than the surrounding bone, rough and vascular. Its spongy tissue is scanty and the trabecular spaces are large. There is periosteal thickening of the sound shaft. The fracture was oblique from without downwards and inwards.

Presented by Dr. Mütter.

I397.075- Femur;lower threequarters;left.
1144
34
3

Oblique fracture of femur at lower third.

The fracture has been firmly united. The permanent callus presents a smooth appearenceand is of long standing. The lower fragment is displaced backward and outward and projects slightly posteriorly and to the outer side. The line of fracture runs from behind forwards, downwards and inwards.

Given by Baron Larrey to Dr.W.S.Forbes.

I397.076- Upper half of left femur. Transverse
1145 fracture. Necrosis. Recent.
34
3

The bone was fractured transversely below the middle. The medullary cavity is open. Its wall consisting of the inner layer of compact tissue was in a state of necrosis,separation not being yet complete. Periosteal inflammation is shown by deposit on the shaft at the inner side of the seat of fracture.

Presented by Dr.Mütter.

I397.077- Left femur. Fracture of the lower
FEM.151 shaft. Union.

The fracture occured at the junction of the middle and lower thirds. The lower fragment passed upward and backward. Union has occured with overlapping and prominence of the upper fragment anteriorly, while the lower fragment points upward and outward. The union is strong;the extremities of the fragments are well covered with smooth compact tissue. There is a deep depression in the upper end of the lower fragment. The bone bows outward at the seat of fracture. The lower fragment has rotated inward 35°.

Presented by Dr.Mütter.

I397.078- Left femur. Fracture of the lower shaft. Union.

1146
34
3

The bone is 44 cm. long. The fracture occured at the junction of the middle and lower thirds. The lower fragment passed upward,backward and to the outer side. Union has occured with slight overlapping but with deviation of the lower fragment downward and inward 20°. The latter has not rotated. The callus is irregular. A sinus on the inner side of the seat of

fracture leads to the medullary cavity of the upper fragment. Another sinus at the end of the lower fragment leads to its medullary cavity.

Vertical section shows well the arrangement of the original bone and callus, both of which constitute the septum between the fragments. The compact tissue of the shaft is thick.

Presented by Dr. Mütter.

I397.079- Right femur. Fracture of the lower shaft. Union with anterior deformity and shortening. (Model).

114
34
3

The fracture occured 8 cm. above the joint and was nearly transverse. The lower fragment passed backward, upward and to the outer side and union has occured in that position. There is therefore anterior deformity caused by the prominence of the end of the upper fragment and an external prominence due to the outward displacement of the lower fragment.

Presented by Dr. Mütter.

I397.080- Portion of the shaft of femur. Oblique fracture. Union.

1155
33
4

The specimen is I3 cm. long and consists of one half of the thickness of the bone. The union is strong. The section shows considerable overlapping with change of the callus in part into spongy tissue. Externally the callus is smooth.

Presented by Dr.Mütter.

I397.08I- Lower shaft of right femur. Oblique fracture. Union.
1156
33
4

The lower fragment has passed upward and forward. The fragments have united with considerable overlapping,forming an anterior prominence of the lower fragment. The extremity of the latter is open while callus covers the extremity of the upper fragment. The callus on the inner side of the seat of fracture is smooth;on the outer side it is rough.

Vertical section shows a septum of compact and spongy tissue.

Presented by Dr.Mütter.

I397.082- Femur;lower half right. Comminuted fracture of shaft;ununited;with sequestra.
1062
32
4

The upper fragment is four inches, the lower, eight inches, and the middle fragment three inches in length. In the upper fragment, on the outer side, is a coloaca, in which is seen a loose sequestrum two inches long. At the line of section at the upper end of the specimen no medullary canal is seen, compact tissue has closed the opening. The middle fragment embodies half of the thickness of the shaft. It seems to have died; its surfaces are rough, the periosteum had disappeared; it has no attachment to surrounding parts. The lower fragment overlaps the lower, at an angle. Its upper end shows evidences of caries and absorption. The epiphysis is not united to the shaft. A portion of the periosteum has been preserved.

Patient aet. I8. Fracture treated for two years. Limb amputated in I885.

Purchased.

I397.083- Lower shaft of left femur. Fracture. Union.

The specimen is I5 cm. long. The lower fragment has passed upward and in

front of the lower, and has united firmly. The callus is smooth and covers well the fractured ends.

Vertical section shows a thin septum in a verticle line. The lower part of this septum is of compact tissue, the upper part, spongy tissue.

Presented by Dr. Mütter.

I397.084- Lower half of right femur. Comminuted fracture of the lower shaft.

1157
33
4

Five fragments are present. Several small ones belonging to the inner and posterior surface are missing. The fragments are long and narrow.

Presented by Dr. Mütter.

I397.085- Lower two thirds of left femur. Comminuted gunshot fracture of the shaft.

1148
34
3

Recent.

The shaft was shattered at the junction of the middle and lower thirds, by a conoidal ball which struck the anterior surface in the middle line. Nine fragments remain. The lines of fracture extend in all directions. Several pass obliquely

toward the condyles.

From a soldier who underwent primary amputation in the upper third of the thigh.

Presented by the Surgeon General U.S.A.

I397.086- Lower two thirds of the right femur.
1063
32
6
Comminuted gunshot fracture of the middle shaft. Conoidal ball in situ.

The ball struck the outer and anterior aspect of the shaft at the middle, and lies in situ. The lines of fracture run nearly vertically. Seven fragments remain.

From a soldier who underwent amputation at the upper third.

Presented by the Surgeon General U.S.A.

I397.087- Femur; lower half; right. Comminuted
1150
33
4
gunshot fracture of shaft.

This specimen comprises seven fragments; others belonging to the posterior surface have been lost.

Presented by the Surgeon General U.S.A.

Missing
I397.088- Portion of the shaft of femur.
1149
34
3
Oblique fracture. Recent.

The specimen is I8 cm. long. The fracture is very oblique, passing through I0 cm. of vertical extent.
H.H.S.

Purchased.

I397.089- Femur;left;lower fourth. Oblique fracture of the shaft.

1151
33
4

The line of fracture is nearly transverse,passing from behind downwards and forwards. The bone is small and light.
D.R.S.

Purchased.

I397.090- Lower third of right femur. Comminuted oblique fracture of both condyles. Union. (Plaster cast).

1152
33
4

The fracture , after passing through the intercondyloid notch,passed from the anterior surface,upward in two lines obliquely above the tuberosities to the middle of the popliteal surface. The lower fragments have passed upward posteriorly. The pointed extremity of the shaft projects in front of the joint,occupying the position of the patella.

From a man who jumped from the third story of the Almshouse. There was neither crepitation,nor twisting of the part,nor increased breadth of the knee,nor difficulty in making passive extension or flexion of the leg. The deformity simulated that of a partial dislocation of the tibia

posteriorly; the leg was thrown backward and the patella was very prominent. The case was treated by Drs Benedict and Page and in six weeks the patient was discharged, able to walk with but little deformity and stiffness. The patient died one year later of typhus fever.

Presented by Dr. Neill.

I397.09I- Lower half of left femur. Inter - condyloid fracture and separation of the epiphysis. Necrosis.

1153
33
4

The epiphysis is detached and is entire. The fracture extends from the middle of the epiphyseal junction upward, and to the inner side and has a length of 7 cm. Necrosis has commenced in the lower IO cm. of the shaft. The line of demarcation is distinct. The sequestrum retains its glossy, smooth surface. Its margins are extremely irregular and have a worm eaten appearance. The absorption of living bone has not progressed far and is shown by a depression about a millimeter wide. On the sound side of this line there is a deposit of bone showing attempted repair.

Callus of recent deposition is seen in the smaller fragment, but no union is present. H.H.S.

Purchased.

I397.092- Lower shaft of right femur. Oblique fracture above the condyles. Recent.

1154
33
4

The fracture passed from behind, near the apex of the popliteal surface, downward and forward. The edges of the fractured bone are smoothed.

Presented by Dr. Mütter.

I397.093- Femur; lower third. Left. Oblique fracture of the shaft. Union with deformity.

1162
35
4

The lower epiphysis is still distinct from the shaft. The union is strong but evidences of extensive disease are seen in the lower fragment. The cancellous as well as compact tissue are invaded. The articulating surface is rough and irregular. The internal condyle is much lower than the right. The breadth of the bone at the condyles is in contrast with the narrow and frail shaft.

Presented by Dr. Mütter.

I397.094- Lower half of right femur. Oblique fracture above the condyles. Recent.

1159
33
4

The epiphysis is united, but the line of its junction with the shaft is distinctly seen. The shaft bows to the outer side. The fracture passes from the outer side obliquely downward and to the inner side terminating 4 cm. above the inner tuberosity. No union has occured. The walls of compact tissue are thin. The popliteal surface is rough and presents numerous exostoses.

Presented by Dr. Mütter.

I397.095- Right femur. Oblique fracture above the condyles with splitting. Recent.

1163
35
4

Only the upper fragment remains. The plane of fracture passed from the inner side obliquely downwards and to the outer side terminating just above the outer tuberosity. A line of fracture I6 cm. long is seen passing from the inner side directly upward inclining anteriorly.

Presented by Dr. Mütter.

I397.096- Femur; lower half; right. Oblique fracture of shaft.

1164
35
4

Great shortening in bad position and frail union are noticeable features of this specimen. The shortening amounts to nearly four inches. The lower epiphysis has separated from the shaft in the process of preparation.

I397.097 - Right Knee; Gunshot fracture. See Vol I Page 447

I397.098 - Left " " " See Vol. I Page 447

I397.099 Femur; upper portion fracture—united — vertical section. Presented by Dr. John H. Brinton.

I397.100 Femur; condyle; - fracture united; — vertical section. Presented by Dr. John H. Brinton.

I397.101 Femur; fracture of shaft; - united with overlapping. Presented by Dr. John H. Brinton.

I397.102 Femur; fracture of the shaft in two places. United in bad position. Presented by Dr. John H. Brinton

I397.103 Femur; Gunshot fracture; - ununited but with signs of repair.
From a man, member of 16th N.Y. Cavalry, black-smith by occupation. Wounded in 2nd day battle of Gettysburg — not mounted when wounded. Admitted to hospital Nov. 5, 1881. Was suffering with Diarrhea which could not be checked. Thigh bone was removed. Died Nov. 21, 1881.
Presented by Dr. John H. Brinton

I397.104 Femur; fracture. United " " " " " "

I397.105 Femur; lower half. Gunshot fracture ununited. Presented by Dr. John H. Brinton.

~~I397.106, Femur; stump; — amputation at the middle Presented by Dr. John H. Brinton.~~

I397.10 Page 991 - Vol. 1

I397.1015 - Page 991 Vol. 1 - Spec. missing

~~1398. Femur, ununited epiphysis. from a child~~
~~Presented by Dr John H Brinton.~~

Diseases of the Femur.

1401

to

1405

I40I- Femur upper fourth. Absorption of neck and exostoses of trochanters and shaft.

1181
34
4

The head has sunk to within one fourth of an inch of the trochanter minor. Section shows the compact tissue of the inferior surface of the neck between which and the trochanter minor a thick wall of additional compact tissue is seen. The exostoses are strong and irregular and prominent, and are seen only on the inner aspect of the thigh.

Purchased.

I40I.05- Femur; upper extremity; left. Absorption of the neck.

1182
34
4

The neck of this bone has undergone considerable shortening. Externally it is seen to be rough and deformed by osteophytes which spring from the margin of the head. There are numerous points on the upper surface of the head where the contents of cavities in the cancellated tissue have escaped. The head, by pressure has gradually approached the trochanters, the neck having undergone absorption;

especially is this noticeable on its inferior surface.

A vertical section shows the changes in the cancellated tissue and the tuberculous cavities. These are distributed near the surface of the head. They are sinuous and enclosed in thickened walls reminding one of the boundaries of abscesses in pulmonary tissue;this process of thickening and induration being an attempt on the part of nature to restrict the process ofdisintegration. Some of the contained tuberculous material has remained encysted; the fatty matter being decomposed and absorbed. The cancellous tissue especially about the circumference of the head is solidified. At the lower surface of the neck the section reveals a line of compact tissue which resembles possibly the original boundary of the neck. This line lies from one fourth to one half an inchfrom the surface,curving with its convexity upwards reaching the surface of the head one and a quarter inches above the new formed junction of the head and neck. This leads one to suppose that owing to the undermining of the head

during a process of softening, the head of the bone has gradually undergone a process of telescoping or has been imposed upon the old limits of the neck, so that the head now involves the neck overhanging it and at the lower part shutting it out from view.

Trans. Amer. Med. Assn. 1878 Dr. H. H. Smith.
29: Ol. 5 - Fig. 2

Purchased.

1402- Upper two thirds of left femur. Caries of the head.
1165
35
4

Almost the entire upper half of the head of the bone has been absorbed. The remainder is rough and marked by osteophytes. The lower end of the shaft is very much thickened and was the seat of chronic periostitis. Transverse section of the lower shaft shows the medullary canal surrounded by four layers of bone; first the cancellated tissue; then the compact; then the cancellated again, and finally a thin but well marked sheath of compact tissue. These layers are one centimeter thick posteriorly, one half, anteriorly.

Presented by Dr. Mütter.

1402.05 Femur. Caries of the head
Presented by Prof. George McClellan

I402.I0- Left femur. Caries of the head.

1166
35
4

The specimen is from a young subject; it is 33 cm.longand the epiphyses are not united. No trace of the head is visible and the neck is rough and presents numerous prominences near its upper margin.

Presented by Dr.Mütter.

I402.I5- Right femur. Caries of the shaft; healed. Anterior bowing.

1169
35
4

The bone is large. On the posterior surface 8 cm. from the knee-joint there is a sinus having a diameter of I cm. Its edges are smooth and was doubtless quiescent when the specimen was removed. Vertical section shows well the repair. The entire thickness of spongy tissue in this situation is consolidated and has an ivory like hardness. The walls of the sinus are still rough. There is decided anterior bowing of the bone.

Presented by Dr.Mütter.

I402.20- Upper two thirds of left femur. Caries of the head and neck.

1175
34
4

The head and upper part of the neck are missing. The adjacent surfaces of the bone are rough,and show more or less periosteal deposit. In the remains of the

neck there is a cavity I.5 cm. deep but not showing any sinus.

Vertical section shows a healthy shaft, and healthy spongy tissue of the trochanter major.

Presented by Dr.Mutter.

I402.25- Portion of the shaft of a femur.
1180
34
4

Caries.

The specimen is I6 cm. long. One extremity is extensively involved in caries. There is also in the shaft, apart from the disease in the extremity a carious excavation.
H.H.S.

Purchased.

I402.30 Femur; caries.
I402.35 see vol I page 1001 Presented by Prof. George McClellan

I403- Femur; upper third; right. Necrosis
1167
35
4

of trochanter major.

The posterior portion of the trochanter major is destroyed. A sequestrum I by 1/2 inches is seen lying behind and below the digital fossa. It is adherent.

Purchased.

I403.I0- Femur; left. Necrosis of middle
1183
34
4

and lower shaft and condyles.

The specimen is from a young person about I6 years of age. The lower shaft is wholly destroyed. Numerous sequestra show the outline of the bone. One large sequestrum is four and a half inches long and represents the entire circumference of the shaft. The section at the middle shows that the original shaft has been enveloped by bony deposit, chiefly of cancellous substance and increased posteriorly to twice its original thickness.

Presented by Dr.John H Packard.

I403.20- Left femur. Necrosis. Exostosis.
1176
34
4

The disease is confined to the lower two thirds of the bone. The surface anteriorly is rough and marked by deeply sunken vascular channels passing in all directions,8 cm. from the knee-joint there is a sinus having a diameter of I cm. leading through thin walls into a large medullary cavity. On the posterior surface the exostoses have had full opportunity for growth. They are most prominent toward the inner side,resembling a cocks comb or coral. In the intercondyloid notch and at points

6 and 9 cm. above it are sinuses. The upper one is two centimeters long and is bridged over by an osteophyte. This openingdoubtless afforded exit to a sequestrum.

Vertical section shows indurated spongy tissue obliterating the medullary cavity in the middle third. Below this is a large irregular cavity 9 by 3 cm. Its walls are of spongy tissue, indurated, and having large intertrabecular spaces.
H.H.S.

Purchased.

I404.01- Femur; upper half; right. Arthritis
1571- deformity of head.
41
6

The head is flattened, rough and marked superiorly by a prominent bony ridge, between which and the remainder of the head is a deep groove.

Presented by Dr. Mütter.

I404.02- Upper third of left femur. Arthritis
1173- with deformity.
34
4

The head has been greatly changed in shape by arthritis. Its surface is rough and the margins are irregular. Its diameter is long in a line parallel to the

trochanters. The neck is short and rough. Posteriorly it amounts to nothing but a narrow sulcus. The trochanter minor is atrophied. There is no depression from the ligamentum teres.

Presented by Dr.Mütter.

I404.025- Right femur. Arthritis and deformity of the head. Exostosis. Eburnation.
1171
35
4
Presented by Dr.A.S.Roberts.

I404.03- Femur;upper half;left. Arthritis. Exostosis of head.
1168
35
4
There is no malformation except at the junction of the head and neck,which is marked by a thick and prominent overhanging ridge of bone. At the inner side of the head this ridge is prolonged to the pit for the ligamentum teres.

Presented by Dr.Mütter.

I404.04- Femur; upper two thirds;left. Arthritis.. Exostosis of head.
1177
34
4
This specimen resembles femur I09, being marked at the head and junction of the headand neck by a similar over hanging

bony ridge. The depression for the ligamentum teres is large and deep.

Presented by Dr.Mütter.

I404.05- Upper two thirds of right femur.
1225
35
6
Arthritis of the hip-joint. Absorption of the head with deformity.

The head is rough, flattened and prolonged downwards and backwards; it curls over upon the neck. The surface of the head contains numerous depressions. The neck is rough and marked by callus. The head has sunk.

1404.03 14 see vol I page 1009
Old No. 1096

I404.06- Femur; left. Ostitis of upper half.
1170
35
4
The upper half of the bone is thickened. Transverse section shows the increase of the thickness of the compact tissue.

Dissecting-room specimen.

Purchased.

I404.07- Upper two thirds of left femur.
1220
35
6
Arthritis; flattening of the head; eburnation.

The head resembles the head of certain mushrooms; it is flattened, having a height of 3 cm. and a breadth of 7 cm. Its borders are prominent and rough. The compact tissue of the head is irregular, eburnated and dotted all over with numerous openings one of which has a diameter of I.5 cm. The neck is short and allows the head to approach within two centimeters of the lesser trochanter. The anterior inter-trochanteric line is well marked.

Presented by Dr. Mütter.

I404.I0- Femur; upper extremity; right. Exostosis and eburnation of the head; with cavities.

1184
34
4

This bone is large. The spherical form of the head is greatly changed; the epiphyseal line is hypertrophied and marked by several deep notches and over hanging osteophytes. Large ulcers of the surface of the head indicate cavities existing in the cancellae of the neck, the contents having been evacuated into the joint, causing acute arthritis. Numerous similar ulcerated points are seen in the trochanteric portion of the neck. No effort for repair

by means of ossifying periostitis has taken place. The shaft of the bone is apparently free from disease.

Vertical section reveals numerous cavities in the cancellated tissue. Many of these cavities have openings by which their contents have escaped into the joint; their walls are hypertrophied owing to the increased vascularity about the inflammatory centre. The morbid product first having encroached upon the normal tissue in which it is developed, the capillaries becoming gradually obliterated in the process of its growth and new vessels have not been formed sufficently for its repair. Boundaries have howeverin many instances been established. The mass has remained encysted, drying up and undergoing calcareous transformation. The calcareous matter is well seen not only occupying a small portion of these cavities but distributed more or less about the periphery of the bone.
Plate 3.Fig.4.

Trans.Amer.Med.Assn. 1878 Dr.H.H.Smith.

✓ Missing?

I404.II- Femur;upper extremity;right. Osteophytes of the head and neck.

1185
34
4

The head of this bone shows broad osteophytes around the origin of the round ligament, on the inferior anterior portion of the head and around the epiphyseal junction of the head with the neck, this portion of the bone being more rough and more solid than is usual in health. The lower edge of the great trochanter is provided with a hook for muscular attachment.

Longitudinal section shows the marked thickening of the bony trabeculae, this induration in some places amounting almost to solidification increases the weight of the specimen.

Dr. H. H. Smith. Trans. Amer. Med. Assn. 1878.

Purchased.

1404.12- Femur; upper extremity; right. Deformity of head; eburnation; cavities.

1178
34
4

This is an example of the changes produced in the head and articular cartilage of the femur in the course of tuberculous disease. The head has lost its spherical shape and is much distorted. It is flattened superiorly and eburnated, due to fatty degeneration, softening of

the bone corpuscles and the gradual attrition of the old bone. There is a bony ridge of compact tissue encircling the neck and enlarging its circumference to the extent of eight inches. The depression for the ligamentum teres situated posteriorly and above the centre. Numerous perforations of the surface of the head of the bone exhibts the points through which the softened tubercles have escaped into the articulation. The largest ulceration on the surface of the head communicates with a cavity in the cancellated tissue seen on section to be of the size of a cherry stone. There are several smaller cavities. Their contents at first wholly enclosed have discharged through numerous small perforations on the surface of the head of the bone after inducing loss of vitality, softening and destruction of the articular cartilage. The cancellated tissue about these cavities is indurated and solidified, a condition due to congestion and increased local circulation as in any other inflammatory focus. Plate II. Fig. 1

Trans. Amer. Med. Assn. 1878 Dr. H. H. Smith.

Purchased.

1404.134 Femur; deformity of the head
Presented by Prof. George McClellan. 1123

I404.I5- Femur;upper extremity;left. Arthritis.
1179 Spec
34
4

Exostosis of neck. Eburnation of head.

The anterior portion of the neck is covered with warty exostoses. Eburnation is seen about the depression for the ligamentum teres.
H.H.S.

Purchased.

I404.I6- Femur;upper fifth;right. Deformity
1186
34
4

of head and neck.

The neck is long. Its verticle diameter is one and three eights inches. The head is broad and flattened. The depression for the ligamentum teres is deep and in the cavity are seen four large vascular channels.

Dissecting room specimen.

Purchased.

I404.I7- Femur;right. Exostosis of trochanters.
1187
34
4

The exostosis is seen chiefly posteriorly,involving both trochanters,the anterior and posterior spiral lines and occupying the digital fossa.

The head of the femur is half an inch

below the crest of the trochanter major. There is decided outward bowing of the shaft, especially in the upper two-thirds; this is caused by the eversion of the lower end of the bone, the rotation amounting to 90°.

Longitudinal section of the upper extremity has been made without giving evidence of fracture.

Dissecting room specimen.

Purchased.

I404.I8- Right femur. Exostosis of shaft and tuberosities.

1188
34
4

The surface of the lower two thirds of the bone is not smooth. Numerous shallow grooves for vessels are seen coursing over the bone. Fine vertical fissures are seen in the upper portion. The linea aspera is unusually broad and rough. The tuberosities, popliteal surface and the shaft above and in front of the condyles are marked by low exostoses. The articular surface is eroded; that for the patella is deeply involved. The shaft of the bone is not thickened.

Presented by Dr. Mütter.

I404.I9- Femur;left. Ostitis of shaft.
1189
34
4

The disease involves the middle of the shaft in its circumference,but is seen chiefly posteriorly involving the whole linea aspera. The surface is rough,the bone thickened,and compact tissue increased in quantity. There are the same appearances just below the neck and in the spiral line.

Dissecting room specimen.

Purchased.

I404.20- Femur;right. Condensing osteitis of the shaft. Caries of articulating
1190
34
4

surface of the internal condyle.

The compact substance of the bone is hypertrophied. Its diameter at the upper fourth is one half inch.

I404.2I- Right femur;periostitis.
1211
34
5

The upper two thirds are involved. There is decided thickening of the bone with roughness,especially of the posterior portion.

Presented by Dr.J.M.Corse.

I404.23- Left femur. Exostoses of the upper shaft and neck. Periostitis.

1212
34
5

The surface of the upper three fourths of the bone is rough. On the posterior surface below the trochanters there is an exostosis with low, irregular borders. The posterior surface of the neck and intertrochanteric line give evidence of decided periosteal excitation. The anterior surface of the neck is smooth.

Vertical section shows decided hypertrophy of the compact tissue of the upper shaft.

Presented by Dr.Mütter.

I404.24- Right femur. Exostosis of the shaft.

1213
34
5

The exostosis is I9.5 cm.long, is spindle shaped, and has a thickness of 3 cm. It is attached to XI cm. of the anterior and inner side of the shaft above the middle. It terminates abruptly below but tapers gently to a point above which nearly touches the lower portion of the anterior intertrochanteric ridge. The exostosis is hollow, containing a little

light spongy tissue and having a thin shell of compact substance. It is marked by vascular grooves on the inner aspect. There are no fine vertical fissures. A number of vascular openings and a sinus at the lower end of the exostosis lead to its cavity.

Presented by Dr.Mütter.

I404.245- Left femur. Exostosis of the shaft.
#1191
33.
5.

An extensive osteophyte,20 cm. extends downward and outward from the anterior portion of the upper shaft.

Presented by Dr.Guy.Hinsdale.

I404.25- Right femur. Ostitis and periostitis of the shaft.
1214
34
3

The disease is situated in the lower three fourths of the shaft.and involves the entire circumference of the bone. The surface is rough,extremly vascular and fissured. Near the borders of the diseased area narrow verticle fissures are seen.

Vertical section shows great thickening of the bone due to periosteal

inflammation. This is chiefly seen posteriorly where the deposit has a thickness of 2 cm. The original wall of compact tissue can be easily traced below this mass excepting in the middle where the compact tissue for a space of 10 cm. probably necrosed. The new deposit is reparative. The spongy tissue in this situation is thickened, and the medullary cavity encroached upon.

Presented by Dr. Mütter.

I404.26- Right femur. Periostitis.
1215
34
5
This bone is probably syphilitic. The surface of the lower half is rough and near the junction of the middle and lower thirds is covered with osteophytes, having broad bases. Grooves run obliquely and transversely and afford passage to vessels. In the intercondyloid notch and above it are two sinuses both of which lead upward into the medullary cavity.

Presented by Dr. Mütter.

I404.27- Left femur. Hypertrophic ostitis.
1216
34
5
The bone is greatly thickened. Anteriorly

it bows forward. Its surface is rough, covered with irregular pits and channels. The latter are well seen above the internal condyle. Fine longitudinal fissures are not seen in the surface of the compact tissue.

Vetical section shows comparatively thin compact walls having an average thickness of I mm. The narrow cavity is of its usual size, the increase of thickness of the bone being due to a thick wall of spongy tissue. The intertrabecular spaces are large. The spongy tissue of the condyles is healthy.

Presented by Dr. Mütter.

I404.28- Left femur. Condensing hypertrophic ostitis. Periostitis.

1217
34
5

The disease is confined to the shaft which is thickened and which presents on the inner side an irregular surface marked by deep vascular grooves. These channels dip into the bone through numerous circular openings. On the outer side these grooves are finer and pass almost transversely. Two or three may be seen run-

ning together toward one opening.

Vertical section shows condensation of the upper shaft. The medullary cavity exists only in the lower portion. The original compact tissue may be traced and, outside of it, the periosteal deposit increasing in thickness up to one centimeter.
H.H.S.

Purchased.

I404.29- Right femur. Exostosis.
1218
34
J

The bone is short and strong. In the linea aspera below the middle is an exostosis having a length of 2 cm. and rising I cm. above the true level of the shaft. The linea aspera is unusually rough.
H.H.S.

I404.295 Femur; Exostosis Purchased.
I404.296 Femur; Exostosis. Presented by Prof. George McClellan
Presented by " " "

I404.30- Right femur. Hypertrophic ostitis.
1198
35
J

Periostitis.

The bone is heavy. Its shaft is uniformly enlarged, measuring from XI to I2 cm. in circumference. Besides the hypertrophy which both forms of bone share, there is a certain amount of periosteal deposit situate upon the outer and anterior surface of the upper shaft and the

internal surface of the lower shaft. In compact tissue and, to a greater degree, in the periosteal deposit minute openings are seen. Grooves for blood-vessels coursing over the bone are seen anteriorly in the lower two thirds of the shaft and on the inner side I2 cm. above the knee-joint where vessels have passed transversely.
H.H.S.

Purchased.

I404.305- Right femur. Hypertrophic ostitis.
1226
34
6

Presented by Dr.A.S.Roberts.

I404.3I- Osteomyelitis of femur after amputation. Internal ossific deposit. Vol. 1-Pg. 14
1199
35
3

The specimens were removed by Dr.John H Packard; November 2I' I865, several months after a previous amputation below the middle of the femur on account of osteomyelitis. They consist first of 75 mm. (3in.) of the involucrum, within which was found, second, the sequestrum, section being made 90 mm. (3.5in.) above the previous line. Within the latter there is, third, a very delicate and vascular tube of new bone. From the

pelvic portion of the femur was taken, fourth, the remainder of the sequestrum 90mm. long, being an incomplete cylinder.

The specimens have the ordinary appearances although the central ossific deposit is not always seen in specimens. It is formed by the endosteum or medullary membrane resulting from the actual ossification of this fibrous expansion or from a deposit of bone corpuscles on its interior surface or from a deposit on its outer side.

Amer. Jour. Med. Sciences. July 1868 Dr. John. H. Packard. 56: 128

Presented by Dr. Packard.

I404.32- Right femur. Ostitis of lower shaft and condyles.
1200
35
5

There is a cavity in the lower shaft with a sinus on the outer side.

Purchased.

I404.33- Right femur. Ostitis; with a cavity and deformity.
1201
35
5

The upper third of the bone is normal; the middle is somewhat thickened, prominent,

and shows on its inner side periostitis. The lower third is greatly thickened; the bone is rough and presents in the popliteal region a cavity extending upwards and inwards. The condyles are also roughened.

I404.34- Right femur. Hypertrophic condensing ostitis. Periostitis of shaft.

The disease is situated exactly in the middle of the shaft, chiefly on the inner side, and has an extent of I0 cm. The surface is rough. Fine vertical fissures are seen in the compact tissue of the shaft in and about the diseased area. These fissures are seen chiefly posteriorly and on the inner side. They are about 5 mm. broad and may be 3 cm. long. The periosteal deposit is considerable, increasing the circumference from 9 cm. to I2.5 cm.

Horizontal section shows an open medullary cavity having a diameter of I cm. the compact tissue greatly hypertrophied having a thickness of 2 cm. on the inner side.

Presented by Dr. Mütter.

I404.35- Lower third of right femur. Periostitis.

1203
3J
5

The popliteal surface, the tuberosities and the adjacent surface of the shaft are rough and show a periosteal deposit. The articular cartilage is also destroyed.

Purchased.

I404.36- Upper half of right femur. Stump with exostosis.

1204
3J
5

The thigh has been amputated at the middle. The extremity is nearly covered with compact tissue. A few openings still remain at the centre of the section. Osteophytes have sprung especially posteriorly. One resembling a spur, has a length of 5 cm. There is no depression for the ligamentum teres. At this point there is a slightly roughened deposit of compact tissue.

Presented by Dr. Mütter.

I404.37- Upper half of left femur. Stump after amputation. Ostitis.

1205
3J
5

Amputation was done at the middle of the thigh. The surface of the shaft

is irregular. On the inner side it is rough. On the posterior side there is a large depression 5 by I.5 cm. Below the trochanters the circumference of the bone is small;toward the seat of amputation it increases in size. There is a sinus in the anterior surface close to the extremity communicating with the open end of the stump. The wall of the shaft is thickened at the extremity but there is no complete closure of the end. The entire shaft was involved in ostitis.

Presented by Dr.Mutter.

I404.38- Femur;lower half;left. Osteomyelitis and exostosis of condyles.

1206
35-
3

The specimen has been sawn longitudinally. The medullary cavity was the seat of osteomyelitis. Compact tissue is thickened posteriorly and is seen extending across the condyles. Externally the latter present osteophytes with cavities. These are seen chiefly about the inner condyle. The extreme lower surface is rough,porous,deprived of cartilage and compact tissue. The popliteal space is also rough and covered with osteophytes.

Presented by Dr.Mütter.

1404.39- Lower half of left femur. Osteophyte.
1207
35
5 An osteophyte resembling the claw of a large bird is situated on the outer border of the popliteal surface near the apex. It points upward.

Presented by Dr.Mütter.

1404.40- Femur; lower third. Condensing ostitis of the shaft.
1208
35
5 The medullary canal at the point of cross-section is obliterated. No cancellated tissue is seen. The bone is very heavy,prominently marked but not otherwise abnormal.

Purchased.

1404.41- Femur;lower half;right. Spinous exostosis of condyle.
1209
35
5 On the inner condyle,from the internal tuberosity there is a triangular exostosis pointing downwards and backwards affording a strong attachment for the inner head of the gastrocnemius.

Purchased.

1404.42- Femur; left. Lower fourth. Arthritis of condyles.
1192
33
5

The articular surface is roughened especially at the borders and at the posterior lips where the edges are very prominent and overhanging. The articulating surfaces of the inner and outer tuberosities so nearly approach each other as leave little space for the crucial ligament.
D.R.S.

Purchased.

1404.43- Femur;lower third;right. Osteitis of condyles.
1193
33
5

The disease is situated chiefly in the outer condyle. The articulating surface is destroyed,the cancellous tissue visible. The external tuberosity is rough and prominent.

Purchased.

1404.435- Femur;lower third. Tubercular arthritis.
1194
33
5

Presented by Dr.A.S.Roberts.

1404.44- Femur;lower third. Exostoses of condyles.

1210
33
5

The popliteal space,the condyles and the articulating surface are rough and irregular. The anterior surface is smooth.

Presented by Dr.Mütter.

1404.45- Femur;lower half;right. Exostosis and caries of shaft.

1195
33
5

This is a striking specimen. Four inches above the trochlear surface the shaft is four inches broad. The posterior surface is comparatively smooth. Anteriorly the exostoses radiate outwards. The surfaces are ragged and porous. The medullary canal is not exposed.

Presented by Dr.Mütter.

1404.46- Lower third of left femur. Osteophyte.

1196
33
5

In the linea aspera at the junction of the middle and lower third there is an osteophyte having a base 2 cm. long and a height of 1 cm. pointing toward the inner side.
H.H.S.

Purchased.

1155

1404.47 Lower extremity of left femur. Arthritis.

1219
35
6

The borders of the articular surface are prominent. The articular facette for the patella has been prolonged upward terminating in a point inthe anterior and outer surface of the shaft.

Presented by Dr.Mütter.

1404.48 Marked I on base. Femur;upper third. Deformity of head.

1197
33
5

The internal aspect of the head is flattened. The fossa for the ligamentum teres has no defined boundaries. There is no eburnation. The neck is very short and is at a right angle to the shaft. The specimen is probably from an old person. Dissecting room subject.

Purchased.

1404.49 Femur;- exostosis. Transverse section of lower end.
Presented by Dr. John H. Brinton.

1404.50 see vol I page 1029

1405 Right femur. Antero-posterior curvature of the upper shaft.

1225
35
6

The lower shaft deviates from the upper shaft 30°. The anterior prominence is in the upper third of the shaft. There

is outward rotation of the condyles 15°.

Vertical section reveals no evidence of fracture. Indurated spongy tissue is seen at the point of greatest bending; below this is the medullary cavity and above it a small free space. The compact layer has a thickness posteriorly of i.2 cm.

Purchased.

1405.05- Right femur. Antero-posterior curvature of the shaft. Periostitis.

1227
34
6

This disease is confined to the lower half of the shaft. The surface is slightly roughened; there are several grooves running laterally around the shaft; and is near the junction of the normal compact tissue, ~~and~~ the area of periosteal excitement ~~the bone~~ is marked by fine vertical fissures. They are ~~invairably~~ invariably parallel to each other and are not deep. The curvature is slight. The shaft is prominent below the middle.

Vertical section shows a normal medullary cavity with comparatively thick compact walls.

Presented by Dr.Mütter.

1405.20- Left femur. Anterior curvature.
1224
35
6 At the upper third there is a slight anterior convexity. There is no rotation. Longitudinal section shows no change in the medullary cavity.

Presented by Dr.Mütter.

1405.30- Left femur. Anterior curvature of the upper shaft.
1222
35
6 At the junction of the middle and upper thirds there is a prominence anteriorly due to the bending of the bone. The angular deviation from the normal line amounts to 30°. The antero-posterior diameter of the bone is increased so that the linea-aspera is nearly straight.

Presented by Dr.Mütter.

1405.40- Left femur . Anterior curvature.
1228
34
6 There is a deviation of 30° at the upper third. Slight rotation has occured to the inner-side. Above the trochanter minor is a distinct sulcus .5 cm. deep. Posteriorly 5 cm. below the trochanter major is a bony eminence about the size of a pea.
H.H.S.

Purchased.

1405.55-1 Left femur Rickets
1231
34
6

Dr A S Roberts

1405.30- Left femur. Anterior curvature.

At the upper third there is a slight anterior convexity. There is no rotation. Longitudinal section shows no change in the medullary cavity.

Presented by Dr.Mütter.

1405.30- Left femur. Anterior curvature of the upper shaft.

At the junction of the middle and upper thirds there is a prominence anteriorly due to the bending of the bone. The angular deviation from the normal line amounts to 30°. The ante-posterior diameter of the bone is increased so that the linea-aspera is nearly straight.

Two specimens with same number.

1408.15- Coxalgia. Excision of right hip Boy six years old, numerous sinuses, hectic temperature; pathologic fracture of the cervix femoris. Recovered. By Dr. A. P. C. Ashhurst July 13, 1906. Children's Hospital.

Coxalgia. Excision of right hip Boy six years, numerous sinuses, hectic temperature, chills and sweats. Acetabulum perforated and ischiopelric abscess. Died in two months of meningitis. By Dr. A. P. C. Ashhurst July 20, 1907. Orthopaedic Hospital

1405.50- Left femur. Rickets. Anterior curvature.
1229
34
6

The bone is adult but has a length of only 31 cm. There is anterior and outward bowing of the upper portionof the shaft. The angular deviation amounts to 50°.

Vertical section shows a thick compact wall posteriorly while the anterior wall is extremely thin. The medullary canal has a normal appearance below. In the upper portion of the shaft there is indurated spongy tissue. The lateral diameter of the shaft is 2 cm.the anterior posterior, 4.3 cm.

Presented by Dr.Mütter.

1405.55- Right femur. Rickets.
1230
34
6

Presented by Dr.A.S.Roberts.

1407- Femur;right. Syphilitic periostitis.
1223
35
6

The disease involves the middle of the shaft for the space of five inches and in the entire circumference of the bone.

The surface is rough and porous especially about the linea aspera. Dissecting room specimen.

Purchased.

← 1408.15

1409.10 Femur; - Separation of lower epiphysis.
With "An Inaugural Dissertation," presented to the Faculty of the Jefferson Medical College for the degree of Doctor of Medicine by Willis T. Davison.
Presented by Dr. John H. Brinton.

1409.15 Femur; from a child; non union of epiphysis.
Presented by Dr. John H. Brinton.

1409.20 Femur; from a child; non union of epiphysis.
Presented by Dr. John H. Brinton.

1409- Pelvis and femurs. Deformity of the femur; shortening.

R32
34
6

The right femur is normal; its length is 44 cm.; the left measures 28 cm. The shortening does not seem to be the result of any fracture. The great trochanter is large and prominent. Below it is the head pointing downwards and adjoining the shaft without the intervention of a neck. The acetabulum lies a little more posteriorly than normal.

For pelvic measurements see #1365.06

Presented by Dr. Mütter.

1409.05 Stump of femur. Amputation at the middle
Presented by Dr. John H. Brinton.

1409.25 Femur and tibia — separation of the epiphysis
Missing
Presented by Prof. George McClellan.

1168

1412-
P241
37
1

Right patella. Oblique fracture of the outer angle; ununited.

The line of fracture runs from the outer side of the superior angle of the patella downwards terminating in the outer border. The line is 3 cm. in length. No union of any sort is seen although the fracture was not recent. The fracture of so small a fragment, 2.5 by 1.5 mm. did not interfere with the function of the patella.

Fractures of the Patella.

1412

1412.00-
P240
37
1

Left patella. Oblique fracture. Osseous union.

The patella was fractured obliquely. The line passes from the junction of the superior inner borders downwards and outwards to the middle of the outer lateral border. The superior fragment is nearly twice the size of the lower fragment. Both are well united by bone. The line of union is smooth and slightly depressed in front. Behind it is marked by a slight ridge of callus which has not been absorbed. The entire length of the patella is 5 cm. The fragments were very closely opposed. H.H.S.

Purchased.

1412- Right patella. Oblique fracture of
1241 the outer angle; ununited.
37
1

The line of fracture runs from the outer side of the superior angle of the patella downwards terminating in the outer border. The line is 3 cm. in length. No union of any sort is seen although the fracture was not recent. The fracture of so small a fragment, 2.5 by 1.5 mm. did not interfere with the function of the patella.

Presented.

1412.05- Left patella. Oblique fracture.
1240 Osseous union.
37
1

The patella was fractured obliquely. The line passes from the junction of the superior inner borders downwards and outwards to the middle of the outer lateral border. The superior fragment is nearly twice the size of the lower fragment. Both are well united by bone. The lines of union ~~is~~ are smooth and slightly depressed in front. Behind it is marked by a slight ridge of callus which has not been absorbed. The entire length of the patella is 5 cm. The fragments were kept closely opposed.
H.H.S.

Purchased.

1412.10- Left patella. Transverse fracture.
1242 Osseous union.
37
1

The line of fracture ran transversely above the middle, reaching a little in the posterior surface that is in front. Posteriorly it is seen to dip down toward the centre of the bone and rise again. The upper fragment was therefore smaller than the lower. There is a slight concavity in front inthe line of union. Posteriorly the line of union is marked by a smooth ridge of callus which at three points shows some tendency to absorption. The length of the patella is 4.75 cm.

Presented.

1412.15- Right patella. Fracture of the lower
1243 third. Osseous union.
37
1

The fracture was transverse separating the angle and the inferior portion of the patella. Union by bone is complete. Anteriorly there is scarcely any trace of fracture. Posteriorly the line is seen curving with its convexity upwards where there is a slight depression due to absorption. The length of the patella is 5.3 cm.

Presented by Dr. Mütter.

1412.20- Right patella. Fracture of the
1244 superior external angle.
37
1 The small fragment is not present.
It consisted of a small portion (one sixth) of the bone. No union occured, but the fractured surface of the remaining fragment is healed with a rough covering of compact tissue. The inner half of the base was left for the attachment of the tendon of the quadriceps extensor muscle.

1412.25- Right patella. Fracture of the
1245 superior external angle.
37
1 This specimen is the exact duplicate of the preceding except that the fragment was slightly smaller. It, also, is lost. In this case two thirds of the base remains for the attachment of the tendon of the quadriceps extensor.

1412.30- Left patella. Transverse fracture
1246 of the articular surface.
37
1 The outer surface is intact; the inner, articular surface presents an irregular transverse depression extending across the bone with numerous small openings into the cancellated tissue. The articular surface

was probably driven inward by sudden pressure against the condyles of the femur in flexion of the leg.

Vertical section shows a normal condition of the cancellated tissue. There is no sign of fracture.

Presented.

1412.35- Right patella. Vertical fracture
1247 through the outer facette. Comminuted.
37
1 One half of the outer facette is broken by a transverse fissure in which lies a small third fragment. Union by a slight ligamentous band has occured in the anterior surface. The breadth of the bone is 6 cm. Length 4.5 cm.
H.H.S.

Purchased.

1412.40- Right patella. Transverse fracture.
1248 Ligamentous union.
37
1 The line of fracture is curved with its convexity downward separating a crescentic lower fragment, the extremities of which correspond to the middle of the lateral borders. Ligamentous union has occured, the fragments remaining from 1.5 cm. to 2 cm. apart.
H.H.S.

Purchased.

1412.45- Left patella. Transverse fracture.
1249
37
1 Ligamentous union.

The upper fragment is slightly the larger. The uniting band is attached to the posterior surface of each causing eversion of the fractured surfaces. At the posterior ridge the fragments are in contact;anteriorly the fractured surfaces are 3 cm. apart. The ligamentous band consists of two triangles with the bases outward;the larger triangle is adjacent to the outer facette.

Presented.

1412.50- Right patella. Stellate fracture.
1236
36
1 (Model).

The model represents a stellate fracture. The largest fragment comprises the base and a little more than one third of the bone. A second,the outer border;a third the apex; and the fourth a small portion of the inner border. It would not be safe to draw any inference from the model as to the nature of union.

H.B. Tuson,Lon.fecit.

Purchased.

1412.55- Transverse fracture;model. Ligamentous union.
1237
36
1

The model represents a transverse fracture through the middle. The fragments are of equal size and are connected by a ligamentous band 1 cm. long which is attached to the posterior surface.
H.B.Tuson,Lon.fecit.

Purchased.

1412.60- Transverse fracture. Ligamentous union. Great separation. Model.
1238
36
1

The fracture was transverse and comminuted. The upper and lower fragments are about equal. They are united by a ligamentous band 8.5 cm. long containing at its middle a small fragment of bone 2.5 by 1 cm.
H.B.Tuson,Lon.fecit.

Purchased.

1412.65- Transverse fracture. Ligamentous union. Model.
1239
36
1

The fragments are of equal size. The ligamentous band measures from 1.2 to 1.5 cm.

Purchased.

1179

1412.70- Fracture of patella and external condyle of the femur.

1235
36
1

The specimen shows the result of a crushing force applied directly to the patella and external condyle of the femur. The femur is crushed superficially the anterior surface above the external condyle being lost to the depth of a quarter to a third of an inch, and the cancellated tissue exposed over a surface as large as a silver dollar. Of the patella scarcely anything remains excepting numerous small comminuted fragments hanging to the ligamentum patellae.

Presented.

1412.75- Fracture of patella. Ligamentous union.

1234

Portions of all the bones involved in the right knee-joint are present. The line of fracture was oblique, passing from a point on the outer and upper edge of the patella downwards and inwards separating a crescentic fragment equal to one fourth of the bone. The lower fragment is held in position by the ligamentum patella.

1412.70- Fracture of patella and external condyle of the femur.

The specimen shows the result of a crushing force applied directly to the patella and external condyle of the femur. The femur is crushed superficially the anterior surface above the external condyle being lost to the depth of a quarter to a third of an inch, and the cancellated tissue being exposed as a silver "dollar". Of the patella, scarcely anything remains excepting numerous small comminuted fragments hanging to the ligamentum patellae.

Presented.

1412.75- Fracture of patella. Ligamentous union.

Portions of all the bones involved in the right knee-joint are present. The line of fracture was oblique, passing from a point on the outer and upper edge of the patella downwards and inwards separating a crescentic fragment equal to one fourth of the bone. The lower fragment is held in position by the ligamentum patellae.

1412.85 Fracture of Patella see page 446 vol I
1412.90
1412.91 Patella; fracture. Presented by Dr. John H. Brinton
1412.92 " "

The upper fragment has been drawn upward by the quadriceps, leaving a space between the fragments of one and a half inches in the middle line. This space is occupied by a thin ligamentous band attached to both surfaces of the lower fragment, but as seen in the specimen, attached to only the under surface of the upper fragment. The lower margin of the upper fragment is bare, rough, the cancellated tissue being exposed and its ligamentous covering having been probably dissected away. The lateral and crucial ligaments and the tendon of the quadriceps have been preserved.

Purchased in Paris by Dr. W.S. Forbes.

Purchased.

1412.80- Patella. Transverse fracture; ligamentous union.

The patient, male, was treated by Dr. R.J. Lewis with malgaigne's hooks, and was supposed to have bony union. An autopsy made several years afterward showed close ligamentous union.

Presented by Dr. J.B. Roberts.

1057.35 ~~1413. Patella~~ ~~Presented by Dr. Drysdale.~~
See page 307

1425 Right tibia fibula and foot, - arthritis of the knee joint Presented by Dr. John H. Brinton. 1183
Rheumatic Arthritis
From negro Jean who died before 1861

Fractures of the Tibia

and Fibula.

1427

IX

1427.101 - Tibia and Fibula: Fracture of the shaft of the tibia and two fractures of the shaft of the fibula. Ununited.

1427- Upper extremity of left tibia and fibula. Gunshot fracture; comminuted.

1340
38
1

These bones were fractured by a conoidal ball which struck the tubercle of the tibia. A portion of the shaft on the fibular side of the tubercle was carried away. From this point lines of fracture radiate; one follows the crest of the tibia downwards; another runs upwards; another curves under the head and runs down the inner side of the shaft. This line is met by a line running transversely 6 cm. from the head which crossed the posterior surface to the opening on the fibular side. Another line is seen on the fibular side of the shaft running vertically. The fibula is fractured 6 cm. from the styloid process. A detached fragment 4 cm. long lies on the outer side.

Presented by the Surgeon General U.S.A.

1427.04- Portion of left tibia and fibula and conoidal ball. comminuted fracture of both bones.

1341
38
1

Only the shaft of the tibia is present and consists of ten fragments. Of the

fibula only the upper portion of the shaft remains and shows an oblique fracture below the head. The ball is flattened and lies on the fibular side of the shaft of the tibia. The lines of fracture run in all directions.

From a soldier who succumbed after partial excision and removal of the fragments.

Presented by the Surgeon General U.S.A.

1427.06- Portions of the left tibia and fibula
1342 with astragalus. Comminuted fracture
38 of the three bones. conoidal ball
1 attached.

The ball struck the fibular side of the leg 5 cm. above the ankle. Ten fragments of the shattered tibia are present; all belong close to the joint. The ball passed through the ankle and fractured the astragalus longitudinally. The inner malleolus is fractured transversely and the small fragment is itself fractured vertically. The lines of fracture do not extend in the tibia more than 5.5 cm. from the ankle-joint. The fibula is shattered

about 3 cm. are lacking at this level.

Case resulted fatally.

Presented by the Surgeon General U.S.A.

1427.08- Lower three-fourths of left tibia and fibular. Gunshot fracture of both bones. Comminution.

1343
38
1

The fracture is in the shafts of both bones below the middle. Of the tibia seven fragments remain. Of the fibula only the extreme fragments are present. Secondary amputation.

Presented by the Surgeon General U.S.A.

1427.10- Upper three-fourths of right tibia and fibula. Gunshot fracture of both bones. Comminution.

1344
38
1

The tibia was struck by a conoidal ball about 11 cm. below the head in its subcutaneous portion, and probably passed through the bone. Ten fragments are present; several are wanting at the points of entrance and emergence of the ball. The tibia presents longitudinal lines of fracture running far down the shaft. The

1427.101- Pg. 1184 - Vol. 1

fibula is broken nearly transversely 13 cm. from the styloid process.

From a soldier who underwent amputation of the thigh.

Presented by the Surgeon General U.S.A.

1427.12- 1345. 39 1

Comminuted transverse fracture of tibia, fibula and calcaneum.

The fracture was caused by a car-wheel passing over the middle of the right leg; the outer side of the leg probably having been directed upwards failed to support the weight, the inner side of the tibia breaking by extension. The fibula is fractured in two places; first just below the middle where it is comminuted; second, at an inch below the styloid process, the shaft being displaced backwards. The tibia is fractured transversely, just below the middle. Two of the smaller fragments are preserved in their relation to the shaft. One of these is situated anteriorly, filling a gap in the crest one and one fourth inches in length and appearing as a perfect isosceles triangle in the internal surface of the tibia; the line of fracture being continued

transversely across the tibia, from the apex of the triangle and forming a perfect letter Y. The calcaneum is crushed at its middle.

Purchased.

1427.14- Tibia and fibula; portions of the lower two thirds. Comminuted fractures of tibia and fibula.

1346
39
1

The fractures occured at the junction of the middle and lower third and was due evidently to crushing force. The lines run from the outer side of the tibia obliquely downwards, terminating above the inner malleolus. The fibula is broken transversely about 8 cm. above the joint. The fractures are recent.

Presented by Dr. Mütter.

missing

1427.16- Oblique comminuted fracture of the shaft of the tibia and fibula.

Both bones of the right leg are present having been sawn below the tubercle of the tibia. The fracture must have been caused by direct violence; both bones are crushed at the same height. The line of fracture

extended, in the tibia, from a point in the crest eight inches above the malleoli obliquely downwards and backwards terminating in the posterior surface of the shaft one and three quarter inches below the point of commencement. A fragment of the posterior shaft, four by three quarter inches lies against the upper fragment. The fracture of the fibula occured from behind downwards and forwards, a fragment two and a half inches long having been detached from the anterior portion of the shaft; the upper fragment shows an almost transverse line of fracture.

The interosseous membrane has been preserved below the line of fracture and shows well the opening for the passage of the anterior peroneal vessels.

Presented.

1427.18- Right leg and foot. Compound comminuted fracture of tibia and fibula. The bones are crushed near the lower end. The joint is not invaded. The foot and lower fragments are carried to the outer side. The fragments, tendons etc. are shown well by dissection.

1448
41
1

Presented by Dr. Mütter.

1427.20- Left leg. Compound comminuted fracture of tibia and fibula.

1446
41
1

The specimen consists of the entire extremity amputated below the knee. The part was placed in brine after removal of the skin and dissection of the tendons. It is now dry and odorless and illustrates well a severe rail-road injury. Three detached fragments of the lower shaft of the tibia hang by attachments to the soft parts. The fibula was broken transversely 7 cm. above the lower end and also at the middle.

Presented by Dr.Mütter.

1427.22- Left leg. Compound fracture of the tibia ;compound comminuted fracture of the fibula.

1447.
41
1

The amputated extremity below the knee has been placed in brine and prepared as in the previous cases. The fracture of the tibia was oblique. Starting from a point 10 cm. above the joint on the posterior surface the lines pass downwards, forwards and outwards terminating 3 cm. below. The fibula was broken at the same level;a wedge-shaped piece with broad base being detached from its inner side.

Presented by Dr.Mütter.

1427.24- Comminuted fracture of tibia and fibula at the junction of the middle and lower third. Recent.

1449.
40
1

The specimen consists of all the bones of the right leg and foot below the tubercle of the tibia. The bones are very much comminuted evidently by a severe crush and several fragments are missing. The bones of the leg show signs of periostitis;the tibia is thickened and its surface rough.
H.H.S.

Purchased.

1427.26- Right leg and foot. Compound comminuted fracture of tibia and fibula. Recent.

1450.
40
1

All the tissues are preserved below the tubercle of the tibia excepting the skin over the leg,which has been removed so as to display the fragments and the tendons and muscles.

Both bones were broken transversely just below the middle. The flexor tendons lie in front and on the outer side of the lower fragments,the latter being displaced anteriorly with 4 cm. shortening.
H.H.S.

Purchased.

1427.28- Right leg and foot. Compound comminuted fracture of tibia and fibula.
1451
40
1

The foot hangs by tendons the skin having been dissected off from the amputated part. The lower end of the tibia and fibula are severely comminuted, the ankle-joint opened and the fragments carried backwards from the astragalus.

Presented by Dr.Mütter.

1427.30- Left lower extremity. Double fracture of tibia and fibula.
1256
37
2

The tibia is divided by transverse fracture into thirds. The fibula is broken transversely at the junction of the middle and upper thirds and obliquely 4 cm. from the styloid process.

Presented by Dr.Mütter.

1427.32- Right leg. Compound comminuted fracture of tibia and fibula above the ankle. Compound dislocation.
1257
37
2

After amputation the entire limb below the head of the tibia has been put in brine. The skin has been removed from the dorsum of the foot upward showing well the fracture

and the muscles and tendons exposed. The whole is varnished and makes a handsome specimen.

The tibia was broken transversely 8 cm. above the lower extremity and also sustained a transverse fracture of the internal malleolus. The lower fragment of the shaft is dislocated forwards and inwards and points upwards and outwards lying wholly in front of the upper fragment overlapping 5 cm.

The fibula is broken obliquely 7 cm. from its lower extremity and is displaced forward. The plane of fracture runs from the inner side, downwards and outwards and is dislocated slightly downwards. The muscles and tendons are dissected nicely and sustain the fragments.

Presented by Dr. Mütter.

1427.34- Transverse comminuted fracture of the tibia; double fracture of the fibula.

1258
37
2

The specimen consists of all the bones of the left leg and foot below the tubercle of the tibia. Transverse fracture occured in the tibia and fibula at the junction

of the middle and lower third;and in the fibula an oblique fracture is seen 8 cm. above this point.

Several fragments are missing from the crest of the tibia. Several lines of fracture coming from the crest converge to a single line on the outer and posterior edge forming with the crest as a base a triangle in the subcutaneous portion of the tibia,the apex terminating in a line which extends backward around the bone. Recent.
H.H.S.

Purchased.

1427.36- Tibia and fibula;left. Fracture
1259
37
2
of tibia at lower third. Union and co-ossification of both bones.

The fracture of the tibia was oblique and occured at the junction of the middle and lower third. The lower fragment was displaced outwards and has remained bent in that position,at an angle of 155° . The medullary cavities of the upper and lower fragment are healthy but are distinct from each other.

The fibula was also broken at a little

higher point and has remained bent with the tibia with which it is co-ossified by a broad ridge of callus to the extent of 80 mm. in a vertical direction.

Presented by Dr.Mütter.

1427.38- Tibia and fibula;fracture of both bones below the middle.

1260
37
2

The bones are from the right leg of a well developed adult. The lines of fracture passed in both instances from before downwards and backwards. Firm union has occurred in good position but with overlapping and prominence of the lower fragments,the edges,however,being well rounded off.

No sinuses are present.
H.H.S.

Purchased.

1427.40- Right tibia and fibula. Fracture of both bones. Union.

1261
37
2

The tibia is broken obliquely. The plane starting at a point on the fibular side 12 cm.from the joint passed downwards and inwards to a point on the inner side 8 cm. from the inner malleolus.

In the fibula the plane passed from a point in the posterior surface 4 cm.below

the head to a point in the anterior surface 6 cm.from the process.

Firm union has occured without deformity; the callus is everywhere smooth and firm.

Presented.

1427.42- Right tibia and fibula. Fracture
1262 of both bones.
37
2 The tibia was broken nearly transversely about 11 cm. above the joint and the fibula about 12 cm.from its lower extremity. The lower fragments lie in front of and to the outer side of the upper.

Provisional callus is still apparent, the limb probably having been removed in the course of treatment. Sections have been made about the seat of fracture showing the relation of callus and bone.
H.H.S.

Purchased.

1427.44- Right tibia and fibula. Fracture
1250 of both bones. Union.
36
2 The fracture of the tibia commenced at a point on the fibular side 14 cm.above

the joint and terminated 7 cm.above the inner malleolus.

The fibula was fractured obliquely beginning at a point on the outer side 4 cm. below the styloid process passing downwards and to the tibial side 9 cm.from the process.

The callus is smooth and strong;a sharp spine,however,is left on the inner side,being the projecting end of the upper fragment.

Presented by Dr.Mütter.

1427.46- Tibia and fibula (cast). Oblique fracture. Union with co-ossification of tibia and fibula.

1251
36
2

The fracture occured in the tibia at the junction of the middle and lower third, the plane passing from the outer side of the tibia downwards and inwards;in the fibula the fracture occured at a slightly higher level but the plane of fracture passed in the same direction.

There is no anterior deformity,but the upper fragment of the tibia overlaps the lower fragment on the inner side of the

leg producing quiet a deformity. The lower fragment of the fibula is carried to the outer side, overlaps the upper fragment, the shortening altogether amounting to 40 mm.

There is a broad bridge of bone 40 mm. uniting all of the four fragments.

Cast made by H.B.Tuson, London.

Purchased.

1427.48- Left tibia and fibula. Fracture
1252 of both bones. Union.
36
2

The fracture in the tibia is oblique; the plane runs from the fibular side 13 cm. above the joint, downward and outward to a point 7 cm. from the inner malleolus. The fibula was broken about 10 cm. from the outer malleolus. The lower fragment of the tibia lies between the fibula and the upper fragment. The callus is smooth and not prominent.

Dissecting room specimen.
W.S.F.

Purchased.

1427.50- Right tibia and fibula. Fracture
1253 of both bones. Union with deformity
36 and shortening.
2

The tibia was fractured obliquely, the plane passing from the inner side 10 cm. above the malleolus downwards towards the fibula, traversing a distance of 6 cm.

The fibula was broken about 4 cm. from its lower extremity but the callus is so abundant that its precise location cannot be seen.

Both bones have united with great overlapping. The lower fragment of the tibia lies on the inner (subcutaneous) surface of the shaft and presents a marked prominence. Its upper end is depressed. Firm union has occurred and co-ossification with the fibula. At the upper end of the lower fragment of the tibia a sinus is seen leading to the medullary cavity. The head of the tibia has suffered from rough handling.

Presented by Dr. Mütter.

1427.52- Fracture of tibia and fibula; ununited in the tibia; union of fibula with deformity.

1254
36
2

Fracture occured in the tibia at the junction of the middle and lower thirds;

in the fibula at the middle. The tibia was broken obliquely, the lower fragment overlaps the upper by an inch and a half and lies upon the outer side. Both ends are smooth, for the most part and have well rounded edges. An opening in the upper fragment leads to the medullary cavity. The lower fragment is united to the fibula at its upper tip; it is very slightly rotated outwards, but is bent decidedly outwards allowing the upper fragment to project upon the inner side.

The fibula has united with a bad angular deformity. The broken ends having been carried under the tibia have united at a deviation of 30° from the straight line.

Presented by Dr. Mütter.

1427.54- Right tibia and fibula. Fracture
~~1595~~ 7355 of both bones. Union.
36
2

The fracture in the tibia commenced at a point 12 cm. above the joint on the fibular side and passed obliquely downwards and inwards to a point 8 cm. above the inner malleolus.

In the fibula the fracture was very oblique, the plane starting at a point in the anterior surface 3 cm. below the head and passing out posteriorly 12 cm. below the styloid process.

The upper fragments of both bones terminate in a sharp point. The lower fragment of the tibia lies on the fibular side of the shaft, that of the fibula is in front of the upper fragment. The callus tends to an irregular growth which is quite noticeable posteriorly.
H.H.S.

Purchased.

1427.55- Right tibia and fibula. Fracture of both bones. Union.
~~1536~~ 1356
36
2

This corresponds almost precisely with the last case. The plane of fracture starts in the fibula side of the tibia from a point 13 cm. above the ankle-joint, passes downwards to a point on the inner side 6 cm. from the malleolus.

In the fibula the plane passes from a point in the anterior surface 4 cm. below the styloid process to a point in the posterior surface 10 cm. below that process.

The lower fragment of the tibia is displaced to the fibular side. The upper fragment presents a prominence in the subcutaneous surface.

Vertical section shows the callus blocking the medullary cavity at the seat of fracture and the sinus in the lower fragment leading internally.

Presented by Dr.Mütter.

1427.56- Right tibia and fibula (cast).
~~1357~~ 1357
36
2
Oblique fracture of both bones. Union.

The tibia was broken at the lower fourth; the plane passed obliquely from behind downwards and forwards. There is great shortening and deformity; the upper fragment projects in front of and overhangs the lower.

The fibula was broken above the middle. The plane passes from in front slightly downward and backward. The lower fragment lies on the outer side and overlaps the upper by 2 cm.
H.H.S.

Purchased.

1427.57- Right tibia and fibula. Fracture
~~1358~~ 1358
36
2
of both bones. Union.

The plane of fracture in the tibia commenced at a point on the fibula side 9 cm. from the ankle and passed obliquely to a point 4 cm. above the inner malleolus.

In the fibula the plane passed from the anterior surface 5 cm. from the styloid process, obliquely downwards and backwards. The upper fragment lies behind the lower. The lower fragment of the tibia lies on the fibular side of the shaft. Between the two fragments on the outer side there is a sinus admitting a pencil and leading to the medullary cavity.

Presented by Dr. Mütter.

1427.58- Right tibia and fibula. Fracture of both bones. Union.
~~1359~~ 1359
36
2

This is also an old specimen. Fracture occured in the tibia about 6 cm. above the joint. The lower fragment passed between the shaft and the fibula producing a decided concavity on the inner side of the bone below the upper fragment, the deformity being still further increased by a prominent exostosis curving outwards and downwards.

The fibula was broken obliquely. The plane passed from the posterior surface through a space of 4 cm. downwards and forwards terminating 3 cm. from the joint. The lower end of the lower fragment is lost.

Vertical section has been made following the abrupt curve at the level of fracture and shows blocking of the medullary cavity at this situation.

Presented by Dr.Mütter.

1427.59- Tibia and fibula. Oblique fracture
1255
36
2
of both bones below the middle.
Union without deformity.

Fracture occurred in both bones at the same height. In the tibia the plane of fracture passed from the crest downwards and backwards, emerging posteriorly one inch below its entrance. In the fibula it passed obliquely from the inner side, downwards and outwards, emerging one inch below the point of entrance. The fibula is not quite straight, bending slightly towards the tibia. The lines of fracture are well smoothed in front. Posteriorly a spicule is seen on the tibia, and

numerous vascular channels about the line of union on the inner side.
H.H.S.

Purchased.

1427.60- Right tibia and fibula. Oblique fracture of both bones. Union.
1347
38
2

The fracture of the tibia occured at the junction of the upper and middle third. It is well united and no trace is left of the line of union. The fracture of the fibula occured at the junction of the middle and lower third. The spiral line of the tibia is rough and prominent.

Dissecting room specimen.
W.S.F.

Purchased.

1427.61- Tibia and fibula;left. Oblique fracture of tibia and fibula. Union.
1348
38
2

The fracture of the tibia is very oblique. The plane passes from the popliteal space downwards and forwards to a point in the crest 20 cm. below the head. The upper fragment overlaps the lower presenting anteriorly a sharp spine pointing downwards. Between the upper and lower fragment there is a large cavity but

probably not the seat of any active changes at the time of death. The fragments are solidly united by permanent callus, and present an irregular deformity in the popliteal space.

The fibula is fractured high up, the plane passing from without downward and inward, the lower fragment lying to the outer side.

The internal malleolus is wanting but this is probably not pathological.

Presented by Dr. Mütter.

1427.62- Left tibia and fibula. Fracture
1349 of both bones. Union.
38
2 The tibia was fractured obliquely above the middle. The plane passed from the crest downwards and backwards through a vertical extent of 4 cm. There is decided prominence of the lower fragment.

The fibula was broken at the same level. The lower fragment lies on the outer side of the upper.

Union has occurred firmly and in excellent position.

Dissecting room specimen.
W.S.F.

Purchased.

1427.63- Left tibia and fibula. Oblique fracture of both bones.

1350
38
2

The tibia was fractured at the middle; the plane passes from the fibular side downwards and inwards emerging 6 cm. below in the subcutaneous portion. The surfaces are smooth near the fibula. A small bridge of bone connects a projecting point of the lower fragment with the upper fragment.

The plane of fracture of the fibula passes from in front downwards, emerging 2.5 cm. below in the posterior surface. The lower fragment overlaps the front of the ~~lower~~ upper.

Presented by Dr. Mutter.

1427.64- Left tibia and fibula. Compound comminuted fracture of both bones. Union.

1351
38
2

Both bones were fractured at the junction of the upper and middle third. They are firmly united by permanent callus which has consolidated with the shaft of the tibia a fragment 8 cm. long belonging to the posterior surface. The upper subcutaneous portion of the shaft is marked

by a prominent ridge of callus. The lower fragments are slightly everted.

The fibula was fractured 11 cm. from the styloid process and shows a shortening amounting to 3 cm. A patient of Dr.Forbes. The left leg was crushed by a loaded coal-cart sustaining a compound comminuted fracture with much laceration of the soft parts. Treated with a fracture box and bran dressing. The subject died two years afterward of typhoid fever when the specimen was obtained.
W.S.F.

Purchased.

A
1427.65- Left tibia and fibula. Fracture
1352 of both bones. Union with short-
38 ening.
2

Both bones have been sawn below the head of the tibia. The fracture occurred in the tibia just below the middle and was transverse. In the fibula it was oblique. Both lower fragments are displaced anteriorly and are firmly united by callus. There is a very marked deformity in the anterior line of the tibia owing to the projection of the lower fragment which amounts

to 2 cm.

Vertical section of the tibia shows well the arrangement of the bone and callus. The fragments have slipped by each other a distance of 5 cm. Their ends broken transversely are now well covered with compact tissue, continuous with that of the shaft. Between the adjacent surfaces of the shaft there is the bond of callus which on section shows an arrangement of compact and cancellous tissue the trabeculae, being regular and not differing perceptibly from those seen in other portions of the bone. Dissecting room specimen. W.S.F.

Purchased.

1427.66- Left tibia and fibula. Simple comminuited fracture of the tibia. Union. Deformity.

1353
38
2

The bone was fractured at the junction of the middle and upper third. A large fragment 9 cm. long lies on the inner side of the tibia and is united to it at its extremities by strong masses of callus. The fragments are co-ossified with the fibula throughout an extent of 9 cm. The latter bone is unusually slender and

has curved backwards at this situation. Although there are many openings in the callus there are no cavities leading to dead bone. These fenestrations are well seen in the subcutaneous portion of the seat of fracture.

Case of simple fracture from a swinging beam of an iron crane. Treated with Physicks fracture box. Died of dysentery three years after the accident.
W.S.F.

Purchased.

1427.67- Tibia and fibula;left. Fracture of
~~1334~~ 1354 both bones below the middle.
38
2

The fractures are strongly united but with considerable displacement. The fractures were oblique the planes in both cases passing from the crest,in front, downward and backward. The lower fragments present themselves in front of the upper so that while the edges are well smoothed anteriorly,the upper fragments project as sharp points,posteriorly. There is also a decided concavity anteriorly with considerable shortening.
H.H.S.

Purchased.

1427.68- Tibia and fibula and tarsus;left.

1361
39
2

Oblique fracture of tibia and fibula.

Both bones of the leg have been fractured just below the middle;in the tibia the fracture ran obliquely from the fibular side downwards and inwards;in the fibula from behind downwards and forwards. The fragments are well co-ossified without any superabundant callus.

There is decided deformity;the lower fragments being displaced to the inner side and leg bowing forwards at the point of fracture.

Presented by Dr.Mütter.

1427.69- Fracture of tibia and fibula. Union.

1362
39
2

The fracture occurred very early in life and was possibly intra-uterine. The fibula was fractured at the junction of the upper and middle third;the tibia, above the middle. Callus has been profusely thrown out consolidating the broken ends. There is marked shortening and overlapping of both inferior fragments, that of the tibia being particularly prominent. The tibia and fibula are separate. The fragments are united at an angle of about 30°. No history.

Presented by Dr.Mütter.

1427.70- Bones of left leg and foot. Fracture of tibia and fibula; ununited. Amputation below the knee.

1363
39
2

The tibia and fibula were fractured at the junction of the middle and lower third at the age of 18 months. They remained ununited until the age of 23 years when amputation was done below the knee. The bones of the leg are very slender, while those of the foot are well developed. The transverse diameters of the bones at the point of section are .6 cm. and 2. cm. respectively. The termination of the fragments is quite pointed and the extremities are enveloped in a tough membrane. They have been allowed to remain flexed at an angle of 90°.
H.H.S.

Purchased.

1427.71- Lower end of right tibia and fibula and tarsus. Changes after ununited fracture.

1364
39
2

The fracture occurred close to the ankle-joint. The portion of the tibia remaining is 5 cm. long, is conical terminating in a sharp point. The end of

the fibula is somewhat shorter and terminates in a slender point. The ligaments of the ankle-joint are well shown. The tarsus is intact.

Presented by Dr.Mütter.

Missing

1427.72- Lower ends of left tibia and fibula with tarsus. Oblique fracture of both malleoli. Union with outward displacement.

The lower fragment of the tibia is about the size and shape of a patella and contains the posterior portion of the lower articular surface. It is displaced upward and toward the fibula. Union has occurred in this position. The inner malleolus was fractured transversely and was carried to the outer side. The fibula was fractured obliquely; the fragment is 5 cm. long. It was carried backward and outward; it deviates 45° backward and is united in that portion. The entire tarsus is displaced to the outer side.

1493.05
~~1427.73~~- Bones of left leg and foot. Necrosis of the tibia.
1492
41
2

See Vol 1 - Pg. 1281

The bones are sawn below the tubercle of the tibia. The disease is situated in the lower half of the tibia and occupies chiefly the subcutaneous portion. An opening 5 cm. in length reveals a sequestrum nearly loose lying below the surface. The borders of the opening are elevated and the surface irregular.
H.H.S.

Purchased.

1427.74- Tibia and fibula with tarsus and metatarsus of right side. Oblique fracture of tibia and fibula.

1453
41
2

The bones are united firmly. The fracture of the tibia occurred 11 cm. above the ankle. The plane passed downwards backwards and outwards. The fragments have united firmly;the permanent callus is smooth. There is decided deformity. The upper fragment has fallen backward and points to the outer side. The tip of the upper fragment is only 1 mm. from the fibula.

The fibula was fractured 8 cm. above its lower extremity. The fracture was almost transverse. The upper fragment overlaps the lower 2.5 cm. and lies on its outer side.

Presented by Dr.Mütter.

1427.75- Bones of right leg and foot. Fracture of tibia and fibula. Outward dislocation at the ankle.

1365
39
2

The bones are from a powerful adult who sustained a fracture of the internal malleolus and fibula near the ankle-joint (Potts). The fractures had united firmly. The lower fragment of the fibula deviates 25° outward from its true line. The foot has been carried outward, the broken internal malleolus following it and uniting with the articular surface of the tibia in the line of the axis of the shaft. The tibia projects to the inner side of the astragalus 3.8 cm. Even the long axis of the fibula falls to the inner side of the calcaneum. The latter bone does not rest squarely on the ground but its lower end is carried outwards and it rests on its inner and lower border. The tibia and fibula are co-ossified at the lower end for a space of 7 cm. from the joint. Their surfaces are smooth.

Presented by Dr.Mütter.

1427.76- Portion of right leg and foot. Compound comminuted epiphyseal fracture of the tibia and fibula.

1454
41
2

The ankle-joint has been crushed. The diaphysis of the tibia has been completely separated from the lower epiphysis. The latter has been crushed in several ~~pieces~~ splinters and hangs over the ankle-joint while the tibia is displaced backwards to the inner side of the heel.

The fibula was broken obliquely 6 cm. from the lower extremity. The lower fragment is split vertically both in its outer and posterior surfaces. On the external side, the bone remains attached to the epiphysis; the inner side of the fibula has been split away from the epiphysis but not completely separated from the shaft.

The specimen was removed from the leg of a child about 8 years old.

Presented.

1427.762- Right foot. Separation of the lower epiphysis of the tibia and fibula.

1366
39
2

The foot has evidently been wrenched off bringing with it the lower epiphysis of the tibia and fibula; that of the tibia remains in position; that of the fibula hangs at the outer side.

Presented by Dr. Mütter.

1257

✓ Missing?

1427.764- Right tibia and fibula. Fracture
1455 ✓ of both bones. Union.
41
2

The tibia was fractured at the junction of the middle and lower third. The plane passed from the fibular side 12 cm. above the joint obliquely downwards and to the inner side emerging 7.5 cm. from the joint.

In the fibular the plane passed from a point on the outer side 3 cm. below the styloid process obliquely downwards and inwards.

Both fractures are firmly united. The lower fragment of the tibia is displaced to the fibular side of the shaft and considerable shortening has occurred.

Presented by Dr Mütter.

✓ X

1427.77- Portion of right tibia and fibula.
1456 Fracture of both bones. Union with
41 deformity.
2 ✓

The tibia was broken obliquely. The direction was from a point on the fibular side 8 cm. above the joint downwards and inwards emerging 7 cm. above the internal malleolus.

The fibula was broken transversely

14 cm. from the lower end. Union was evidently delayed in both fractures and is not firm. The lower fragments are inclined to the outer side 22°. The reparative callus is frail and porous. The lower end of the upper fragment of the tibia is hollow and presents a large sinus run-

(1) Photographs of fractures and dislocations (159)
Presented by Dr. A. P. C. Ashhurst.
(2) Family medicine Case - from the effects of Hon. Leonard Myers of Philadelphia. - Presented by Mr. Leonard G. Myers.
(3) Surgical instruments of a native Korean Surgeon & Upper half of a tibia found at Port Arthur - 203 Metre Hill. Photographs etc. - Presented by Dr. Rosetta Sherwood Hall.
(4) Nine brain sections showing the gross anatomy and relations of the brain. Prepared by Dr. Joseph Funis - Purchased.
(5) Forty microscopic sections of the brain. Prepared by C. H. Miller of the Johns Hopkins University. Purchased.

passed from the fibular side downwards and inwards emerging 5.5 cm. from the starting point.

The fibula was broken obliquely at the junction of the middle and upper third, the plane passing from in front downwards and backwards. The callus in both fractures is not redundant; shortening not excessive. A cast of the longitudinal section shows the line of callus blocking the medullary cavity.
H.H.S.

Purchased.

1253

14 cm. from the lower end. Union was evidently delayed in both fractures and is not firm. The lower fragments are inclined to the outer side 22°. The reparative callus is frail and porous. The lower end of the upper fragment of the tibia is hollow and presents a large sinus running through to the posterior surface. The callus about the fracture of the fibula is abundant but weak and suggests that the parts were not kept at rest.

Presented by Dr. Mütter.

1427.78- Right tibia and fibula. Oblique fracture of both bones. Union.

1457 41 2

The tibia was broken at the junction of the middle and lower thirds. The plane passed from the fibular side downwards and inwards emerging 5.5 cm. from the starting point.

The fibula was broken obliquely at the junction of the middle and upper third, the plane passing from in front downwards and backwards. The callus in both fractures is not redundant; shortening not excessive. A cast of the longitudinal section shows the line of callus blocking the medullary cavity.
H.H.S.

Purchased.

p. 1253 b

Photographs of fractures and dislocations - 1671
Presented by Dr. A. P. C assl

1255

destroyed

1427.79- Left tibia and fibula (cast). Fracture of both bones. Union.

1458
41
2

Fracture occurred in the tibia at the junction of the middle and lower third. In the fibula about 9 cm. from the lower extremity, the planes run from the inner side downward and outward in both cases. Callus is not superabundant excepting for the fact that the two bones are bound together by a bridge of callus at the level of fracture.

There is slight angular displacement owing to the inclination of the fractured ends of the tibia toward the fibula.

H.B.Tuson fecit.

Purchased.

1427.80- Tibia and fibula; left. Fracture of tibia and fibula at the lower fourth. Union.

1459
41
2

The fractures are well united but the callus is not prominent. The plane of fracture passed in the tibia from the posterior surface downwards and forwards emerging on the crest 7 cm. below the point of commencement.

The fibula was broken 8.5 cm. above

the lower extremity; the lower fragment lying on the outer side.

The peculiarity of the specimen is the fact that the anterior tibial artery descending as usual in front of the interosseous membrane has been enclosed by callus throughout an extant of 2.5cm. The artery emerges on the fibular side of the leg and descends to the junction of the tibia and fibula, Here it is lost sight of in the specimen, but, according to Gray, usually regains its position beneath the annular ligament at the front of the ankle.

Dr. H.H.S.

Purchased.

1427.81- Right tibia and fibula. Fracture of both bones. Union.

Oblique fracture occurred in the tibia starting on the fibular side 9 cm. from the ankle-joint and passing downwards and inwards to a point 3.5 cm. above the apex.

The fibula was broken about 8cm. from the lower extremity. The bones are firmly united with co-ossification of the lower fragments, which are bent forward at a slight inclination.

Vertical section shows blocking of the medullary cavity by callus. The tibia bows slightly toward the inner side.

Presented by Dr. Mütter.

1427.82- Right tibia and fibula. Fracture of both bones. Union.

1461
41
2

This specimen seems to have been long buried. Fracture occurred above the ankle in both bones and again in the fibula below the head. The lower end of the specimen is enlarged by permanent callus which builds both bones together and obscures the lines of fracture. High up the fracture of the fibula was oblique and is also marked by a prominent ridge of callus on the outer and anterior side. A portion of the lower fragment is lost.

Presented by Dr. Mütter.

1427.83- Right tibia and fibula. Oblique fracture of both bones. Recent.

1462
40
2

In the tibia the fracture from the fibular side 10cm. above the ankle downwards and inwards to a point 8cm. above the internal malleolus.

The fibula was brokwn below the mid-

dle, the direction being from the posterior edge downwards forwards and outwards. The fracture traverses a distance of 4 cm.

Presented by Dr. Mätter.

1427.84- Right tibia and fibula. Oblique fracture of the tibia. Double fracture of the fibula.

1360
36
2

The tibia was fractured obliquely close to the ankle. The plane passed from the fibular side downwards and inwards terminating at the inner malleolus.

The fibula was broken obliquely at the junction of the middle and lower third, also close to the neck. In the lower fracture, the plane passed from the outer side downwards towards the tibia. The ends of the fragments and the tibia are at this point, united by a broad bridge of callus. There is also callus thrown out about the head of the bone binding it firmly to the tibia.

Shortening is marked and deformity owing to displacement of the lower fragments to the outer side.
H.H. S.

Purchased.

1427.85- Left tibia and fibula(cast). Fracture of both bones(Pott's). Union.

1463
40
2

The inner malleolus is fractured transversely. The fibula is broken obliquely 9 cm. from the lower end. The plane runs from the tibial side downwards and outwards. Union is firm and there is no deformity.

H.B.Tuson fecit.

Purchased.

1427.86- Portion of tibia and fibula. Fracture of both bones. Anchylosis of the astragalus. Union with deformity.

1464
40
2

The bones were brokwn transversely at the same level,10cm. from the ankle joint. Union occurred without superabundant callus,except for a bridge of bone joining the two at the seat of fracture. The lower fragments are carried outward and deviate 25° from the natural line.

The astragalus is united to the tibia and its borders are marked by prominent ridges.

H.H.S.

Purchased.

1427.87- Lower portions of the left tibia and fibula. Fracture of both bones in the lower third. Union.

1465
40
2

The tibia has been sawn below the tubercle and, of the fibula, only a portion of the lower shaft remains. Vertical section of the tibia shows a united fracture which occurred about 8 cm, above the ankle, The lower fragment is displaced backward with overlapping. The fragment points downward and to the front, The medullary canal is occupied by indurated spongy tissue all about the seat of fracture, The compact tissue is not well defined, Externally the bone is irregular, distorted by permanent callus, which forms a spindle shaped deposit over the entire lower portion of the bone. The surface is rough and co-ossified with the fibula. The latter bone was fractured at about the same level as the tibia and is thoroughly united.

Presented by Dr. Mütter.

1427.88- Portion of right tibia and fibula. Oblique fracture of both bones.

1466
40
2

The bones have been sawn at the junction of the middle and upper third. The

fracture occurred in the tibia at the junction of the middle and lower third, passing very obliquely from a point on the fibula side 14 cm. above the joint. In the fibula the fracture seems to have occurred in or near the epiphyseal line. The articular surface belonging to the lower fragments remains in position, the upper fragment, embodying the shaft, seems to have fallen below the apex. There was considerable shortening.

destroyed

1427.89- Left tibia and fibula(cast). Fracture of both bones. Union.

1467
40
2

The tibia is fractured obliquely; the plane passed from a point on the fibular side 7 cm. from the joint to a point on the inner side 4.5 cm. from the inner malleolus.

The fibula was broken at the same level. Both lower fragments incline outwards; the deviation in the fibula amounts to 25°; less in the tibia. There is a slight prominence of the upper fragment of the tibia in the subcutaneous surface at the point of fracture. The lower frag-

ment of the fibula lies in front of the upper.

H. B. Tuson fecit.

Purchased.

IX

1427.90- Right tibia and fibula. Double fracture of the fibula involving ankle-joint. Fracture of the shaft of the fibula. Union.

1468
40
2

The tibia was fractured at the lower end. The fragment comprised the inner malleolus and 5cm. of the shaft above it, and one third of the articular surface. The fragment is well united. There is slight atrophy of the inner malleolus and the bone in the line of union is in the articular surface, is depressed and contains two cavities, one of which is nearly 3cm. in depth. There is eburnation also of the main portion of the articular surface.

The fibula was fractured at the junction of the middle and upper third, and also 4cm. from the lower extremity. Both fractures are firmly united. In the lower fracture, the malleolus has turned to the inner side and the foot was doubtless twisted inwards.

Dissecting-room specimen.

Purchased.

R.H.N.

1427.91- Right tibia and fibula. Fracture of both bones, involving ankle-joint. Partial union.

The bones have been sawn below the tubercle of the tibia. Fracture occurred in the tibia obliquely. The plane passed from a point in the fibular side 5cm. from the ankle to the articular surface 1cm. from the inner malleolus. The lower fragment embraces 3/4 of the articular surface. The fibula was broken at about the same level. Provisional callus is seen binding the fragments together; this has been accomplished more thoroughly at the upper portion than at the joint. The specimen must have been removed not many weeks after the accident. The lower fragment of the fibula is wanting.

Presented by Dr. Mütter.

1427.92- Right tibia and fibula. Comminuted fracture of the tibia involving the ankle-joint. Fracture of fibula. Union.

The fracture occurred low down. In the tibia, the direction was oblique from the fibular side downwards and inwards, passing the crest at a point 4cm. above

the joint;thence it passes to the joint, dividing the articular surfaces into three divisions;the larger one embracing the internal malleolus,extending as a wedge toward the fibula;another consists of the outer portion of the articular surface, the third,of the posterior portion.

The lines of fracture in the articular surface are depressed owing to absorption of bone and absence of callus.

In the fibula,it was slightly oblique from the tibial side downwards and outwards,terminating at a point 5cm. from the extremity. Union is firm; the surfaces are smooth,without deformity and with moderate shortening.

Presented by Dr. Mütter.

1427.93- Left tibia and fibula. Fracture of
1471 both bones. Union. Anchylosis of ankle-
40 joint.
2

The fracture of both bones occurred about 10cm. from the ankle. In the tibia, the plane seems to have passed from the inner side obliquely downwards and to the fibular side. Vertical section shows a continuous medullary cavity. The lower

fragments are carried to the inner side. Anchylosis of the entire length of the lower fragments has occurred and complete obliteration of the ankle-joint and anchylosis of the calcaneum and astragalus.

Presented by Dr. Mütter.

1427.95- Right tibia, fibula and astragalus. Fracture of the fibula; union. Anchylosis of the ankle-joint.

1472
40
2

The fibula was broken five centimeters from its lower extremity. Union has occurred with considerable backward displacement of the adjacent ends of the fragments. The ankle-joint is completely anchylosed.

Dissecting-room specimen.

W.S.F. Purchased.

1427.96- Left tibia and fibula. Fracture of the bones. Union.

1473
40
2

The tibia was broken obliquely. The plane passed from a point on the fibular side 5cm. above the joint to a point on the inner side 3cm. above the inner malleolus.

The fibula was broken transversely 5cm. above its lower extremity.

The lower fragments are bent outwards; that of the tibia lies on the external side of the upper fragment, the lower fragment of the fibula lies on the posterior surface of the shaft. The shortening amounts to about 3.5cm.

Presented by Dr. Mütter.

1427.97- Left tibia and fibula. Fracture of both bones (Pott's).

1474
40
2

The inner malleolus has been fractured transversely. It has not united, but has been preserved separate. The adjacent surfaces of the fragments are rough but healthy.

The fibula was broken obliquely, the plane passing from a point in the interior surface 5cm. from the lower extremity backwards and downwards, emerging two centimeters below. Union is firm and the fragments are in good position.

Presented by Dr. Mütter.

1427.98 Tibia and Fibula; Fracture

999

see vol I Page 446

1427.99 Tibia and Fibula; - fracture of shafts; - ununited
Presented by Dr. John H. Brinton.

1427.100 Tibia and fibula; - fracture
Presented by Dr. John H. Brinton.

DISEASES
of
TIBIA
and
FIBULA

1433
to
1435

1433- Left tibia and fibula. Necrosis. Hypertrophy. Periostitis.

1274
37
3

This is a remarkable specimen of the ravages of bone disease. Almost the entire lower third of both bones is gone. The tibia was originally large, but its circumference has been increased in the progress of disease and measures at the junction of the upper and middle third 20cm., at the middle 21cm. The lower extremity is separate from the shaft and consists of the portion adjacent to the joint. The subcutaneous portion in the lower third is wanting for a space of 14cm. There is no trace of the shaft of either bone in this situation excepting posteriorly and continuity has been dissolved.

All the surfaces of both bones are rough, especially posteriorly and along the attachment of the interosseous membrane from which have sprung numerous bridges. Numerous cloacae are seen in the subcutaneous portion having a lumen of from 2 to 4 cm. They are arranged vertically. Sequestra are seen within. The bone is thoroughly underminded. It is astonishing that a human bone should reach such a state.

H.H.S. Purchased.

1433.05 see vol I page 1243
145

1434- Left tibia and fibula. Exostosis.

1275
37
3

These bones are very long. The tibia measures 47cm. It is rough and covered with exostoses. The crest at the middle is sharp and is deflected to the fibular side. On the inner side and also posteriorly below the head osteophytes are seen.

Vertical section shows increase in thickness of the compact tissue.

The fibula has a very rough and irregular surface. Especially along the margins and below the middle the osteophytes are sharp and prominent. One situated posteriorly resembles the dorsal fin of a fish.

Presented by Dr. Mütter.

1434.05- Left tibia and fibula. Exostosis.

1276
37
3

The chief exostosis is in the posterior surface of the tibia and consists of a ridge 12cm.long running from below the outer head downwards and inwards, marking the attachments of the soleus muscles. The fibula shows only a slight roughness of its borders.
H.H.S.

Purchased.

1285

1434.10- Right tibia and fibula. Hypertrophic ostitis.

1277
37
3

The tibia is heavy and strong, measuring 41.5 cm. in length. Its surface is rough but free from sharp points. The line of the crest is irregular, especially below the middle, vertical section of the tibia shows great increase in the thickness of the compact tissue, which in the crest has a thickness of 1.6cm. There is a distinct antero-posterior curvature.

The fibula is nearly straight, but is rough and thick, with a tendency to lose the clear definition of its three surfaces by the loss of angularity.

Presented by Dr. Mütter.

1434.15- Right tibia and fibula. Hypertrophic ostitis.

1278
37
3

Both bones are heavy and thick. Their surfaces are smooth, excepting posteriorly where the tibia presents prominent longitudinal lines.
H.H.S.

Purchased.

1434.20- Left tibia and fibula. Exostosis.
1279
37
3

In this case the fibula is chiefly affected and the disease is most marked below the middle. The borders are rough and dentated. The same condition, in a less degree, is seen in the line of attachment of the interosseous membrane and in the spiral line.

The joint surfaces are smooth.

Presented by Dr. Mütter.

1434.25- Upper third of right tibia and fibula. Anchylosis.
1280
37
3

The bones are slight. The head of the fibula is firmly united to the tibia. The head of the tibia is quite rough. There is a cavity between the articular surfaces and there is no spine.

Presented by Dr. Mütter.

1434.30- Portion of the shafts of the right tibia and fibula. Exostosis.
1281
37
3

The specimen is 19cm.long. The disease is seen chiefly in the fibula, which is marked by rough outgrowths of bone.

A plate of bone occupies the position of the interosseous membrane, uniting the two bones.
W.S.F.

Purchased.

1434.35- Left tibia and fibula. Syphilitic
1282 ostitis. Anchylosis.
37
3

The disease is present chiefly throughout the lower half of the tibia and the whole of the fibula. The bones are united by new growth throughout their lower third. A large patch of carious bone 10 x 5cm. is seen in the anterior aspect of the tibia below the middle. The lines of attachment of the interosseous membrane and the spiral line are prominent.

Dissecting-room specimen.
W.S.F.

Purchased.

1434.40- Right tibia and fibula. Ostitis.
1283
37
3

The bones are generally covered with exostoses. Only the articular surfaces are smooth. The angles of the fibula are prolonged. The lines of attachment of the

interosseous membrane and the spiral line are marked by exostoses.

Purchased.

1434.45- Left tibia and fibula. Anchylosis.

1284 The bones are anchyloses at both extremities. At the upper part ~~of~~ the anchylosis only involves the articulation. In the lower part the bones are united by a smooth band 5cm. long.

37
3

Presented by Dr. Mütter.

1434.46- Left tibia and fibula. Ostitis.

1285 The lower half of the subcutaneous surface of the tibia is rough and porous. There are, however, no prominent outgrowths of bone. There is a small carious cavity 8cm. from the inner condyle. The lower third of the fibula presents the same appearance ina more moderate degree.

37
3

The specimen has been sawn vertically.

Dissecting-room specimen.

Purchased.

1434.47- Right tibia and fibula. Anchylosis.
1270 The bones are co-ossified at their
36 upper articulation, but are otherwise
3 healthy.

Presented by Dr. Mütter.

1434.48- Right tibia and fibula. Syphilitic
1271 periostitis.
36 The tibia and fibula are both af-
3 fected. The surfaces are rough, abound in small vascular openings and the thickness of the bone is considerably increased. The crest is not sharp and protrudes considerably in the middle third. The only smooth surface is seen in the upper third of the tibia.

Presented by Dr. Mütter.

1434.50- Right tibia and fibula, calcaneum and
1272 astragalus. Hypertrophic ostitis. Anchylo-
36 sis of ankle-joint.
3 This is a striking epscimen. The tibia is enormously thickened and bears little resemblance to the normal bone.

It is 39.cm long. Its circumference at the tubercle at the middle and above the ankle is 20 cm. The head is irregular; the facettes are rough and the tuberosities are for the most part devoid of compact substance, porous and marked by spicules of new bone. The popliteal notch is deep and irregular. Between the facettes for the femur and in front of them is a large and irregular opening accommodating the thumb. The tubercle is prominent and above it are seen numerous vascular channels, There is no crest strictly speaking, The anterior line is seen, on section, to recede above the middle, below which it is prominent and irregular, owing to the presence of osteophytes and carious patches, The attachments of the interosseous membrane and soleus are marked by lines of osteophytes.

The fibula is rough and thick. The borders are very rough and prominent. The interosseous ridge has formed bony attachments to the tibia. The prominence of the borders has increased the outer surface at one point to 3.5 cm. Close to the ankle the tibia and fibula are consolidated. Anchylosis of the entire ankle-joint has occurred ~~and~~ also of the calcaneum and of the

astragalus with each other. The groove for the flexor tendons is smooth and deep.

Vertical section of the tibia shows no medullary cavity, the trabeculae being continuous throughout the entire section; neither is there any line separating the tibia from the astragalus. Below the middle and the carious area the bone is more dense and the trabeculae are indurated. The antero-posterior diameter at the tubercle is 7cm., at the junction of the upper and middle third, 4cm., and below the middle, 6cm. The compact tissue is unusually thin throughout.

Presented by Dr. Mütter.

1434.55- Superior thirds of right tibia and fibula. Osteomyelitis of a stump.

1273
36
3

The bones are from a large man who had undergone amputation in the upper third of the leg. The bones are rough and covered with osteophytes. They are well seen below the inner head of the tibia. The spongy tissue has undergone softening, leaving a large vacancy. The compact tissue is quite thin at the point

of original section and shows no efforts at repair of the gap in either bone.

Presented by Dr. Mütter.

1434.60- Left tibia and fibula. Periostitis.
1263
36
3 Exostoses.

This condition is seen in the tibia chiefly on the fibular side, where the surface is quite irregular. The fibula is very rough throughout its whole extent. The borders are irregular and the surface porous. The disease is chiefly located on the tibial side.

1434.65- Lower two-thirds of right tibia and
1264 fibula. Ostitis.
36
3

The disease is confined chiefly to the fibula, which is enlarged, especially at its lower end where it nearly equals the tibia in size, rough and resembling a sponge in its vascularity. The subcutaneous surface of the tibia is rough and marked by fine vascular openings. The bones are united near the ankle-joint.

H.H.S. Purchased.

1435- Right and left tibiae and fibulae.
1265
36
3

Internal bowing.

The lower extremities of the legs deviate outwards; in the right 30°, in the left 40°. The center of the shaft of the right tibia falls 3cm., and that of the left tibia, 3.5cm. to the inner side of the linejoining the centres of the extremities. The bones are adult.

Presented by Dr. Mütter.

1435.10- Right tibia and fibula. Antero-lateral bowing.
1266
36
3

The bones are adult. They present a convexity forward and to the inner side and below the middle. They devite 45° from the natural line. The center of the shaft of the tibia is 5.5cm. from the line joining the centres of the extremities; that of the fibula is 4.5cm. from a corresponding line. The crest of the tibia has disappeared. The lateral diameter of the fibula is 3.75cm. at the convexity. That of the tibia, 3.3cm.

1435.20- Right tibia; outer half by vertical
1267 section. Anterior bowing.
36
3 The bowing is greatest below the middle; the lower end of the bone deviates backward 40°. The specimen is from an adult.

Presented by Dr. Mütter.

1435.30- Left tibia. Antero-posterior curva-
1268 ture.
36
3 There is a prominent curvature in the bone, the convexity of which points anteriorly, involving the shaft below the middle. The crest is carried to the outer side. The angular deviation amounts to about 30°.

Presented by Dr. Mütter.

1435.40- Right tibia. Antero-posterior cur-
1269 vature.
36
3 The curvature occupies the lower portion of the shaft. In this case the convexity is directed posteriorly. The lower portion of the bone having been carried so abruptly forward would suggest ~~being~~ bending of the bone, when in a more flexible state, from a force applied to the lower portion of the crest. The angular deviation amounts to about 35°.

Presented by Dr. Mütter.

1308

1441 Wet Photographs of Congenital anterior dislocation of tibia - on being an Arthrograph.

1435.45 Bones of the right foot, tibia and fibula. Arthritis of the knee joint. Presented by Dr. John H. Brinton

FRACTURES OF THE TIBIA

1442
to
1457

1442- Upper third of right tibia and fibula. Gunshot fracture of the tibia.

1367
38
3

The ball entered the tibia in the subcutaneous surface 6cm. below the head and passed upward and backward, emerging in the middle line 2cm. below the popliteal notch. At the point of exit the compact tissue is elevated. There is a channel marking the track of the ball.

Presented by Dr. Mütter.

1442.01- Upper extremities of right tibia and fibula. Gunshot fracture of the tibia. A battered conoidal ball impacted.

1368
38
3

The ball struck a little below the tubercle of the tibia on the fibular side where it is seen embedded. A triangular fragment embraces the anterior portions of both heads and a slight extent of their articular surfaces. Vertical lines of fracture pass down the fibular side of the shaft and the junction of the subcutaneous and posterior surfaces, but do not involve the joint.

Intermediate amputation at the lower third of the thigh.

Presented by the Surgeon General, U.S.A.

1442.02- Lower two-thirds of right tibia and
1369 fibula. Gunshot fracture of the tibia.
38
3 Extensive comminution.

The ball evidently struck the inner side of the shaft at the junction of the middle and upper thirds. From this point, nine lines of fracture radiate. The point of entrance is round. The point of exit is much more irregular and of greater size. Many fragments are missing from the situation.

From a solider who underwent primary operation after fracture from a conoidal ~~bone~~ ball.

Presented by the
Surgeon General, U.S.A .

1442.03- Left tibia and fibula. Fracture of
1370 the head of the tibia. Union.
38
3

The head of the bone is distorted and it is difficult to say where the lines passed. The inner facette extends 4cm, lower than the outer. About 1cm. below the inner head there seems to be a line of callus. There are two small perforations in the subcutaneous surface 6cm. below the ~~inner head~~.

Dissecting-room specimen.
Purchased.

1442.04- Right tibia, Gunshot fracture.

1371. The ball entered the shaft 5cm. below the joint upon the inner side. A cavity remains bordered by porous bone friable and vascular. Local periostitis, No fracture lines visible.

Presented by Dr. Mütter.

1442.06- Fracture of the head of the tibia; epiphyseal.

1372. The specimen consists of the adjacent extremities of the femur and tibia of the left side, and removed from a child about ten years old. The separation is complete; the epiphysis is held in position by the crucial ligaments.

Purchased.

H.H.S.

1442.07- Upper third of left tibia. Separation of the epiphysis.

1373. The specimen is from a child about seven years of age. The epiphysis is completely separated.

Purchased.

1442.08- Right tibia. Fracture of the outer
1374 head. Union.
38
3

The anterior portion of the outer-head and a portion of the bone above the tubercle constitute the principal fragment. This is united to the shaft, but is 3cm. lower than the corresponding portion of the inner head.

Presented.

1442.09- Left tibia and fibula. Ununited fracture of the tibia. Supplemental hypertrophy of the fibula.
1375
38
3

This is a remarkable specimen. The fracture occurred at the junction of the upper and middle third of the tibia and remained for many years ununited. The upper fragment points downward and backward. The lower fragment points upward and outward and is connected with the upper by a fibrous band 4cm. long. The adjacent ends are pointed and the medullary cavity is not exposed. The lower fragment is decidedly atrophied. At the middle of the leg and 2cm. below the extremity of the lower fragment, the tibia mea-

Fig. 894.

Supplemental hypertrophy, from a specimen in the museum of the College of Physicians, Philadelphia.

1318

sures 6cm. in circumference, the fibula measuring at the same level 7.25cm, with a lateral diameter of 2.6cm. The fibula is very strong, The measurements given above are the usual measurements of the shaft. It bows outward opposite the fracture of the tibia and its center in this situation is 2.75cm. outside of a line joining the extremities of the bone. This hypertrophy and bowing is the result of the fibula's assuming the function of the tibia in the support of the body in the act of walking,--a duty which it fulfilled for many years.
H.H.S.

Purchased.

CUT Fig.894 Agnew's Surgery.

1442.10-
1377.
39
3

Tibia and fibula. Fracture of tibia from gunshot wound. Exuberant callus involving the fibula.

The ball struck the left tibia about three inches below the tubercle. No traces of the lines of fracture remain, all having been obliterated by the permanent callus, which is profuse and smooth, unu-

nited at the head and upper third to the fibula, preserving well the strength of the limb. There is, however, considerable deformity; the lower fragment of the tibia deviates to the inner side, the ankle resting four inches inside of a line drawn perpendicular to the plane of the head--one sinus in front and two behind lead to cancellated tissue.

Section has been made longitudinally, showing the anterior sinus leading downwards and inwards. The medullary cavity is normal below the middle; above it is obliterated by the spongy tissue about the seat of fracture, where it is more dense than usual, but does not follow any particular course.

Presented by Dr. Mütter.

1442.11- Tibia and fibula; upper three; fourths.
1378. Fracture of the right tibia; oblique, Union
39 with deformity.
3

The plane of fracture passed a point in the crest, an inch below the tubercle, obliquely downwards and backwards, emerging four inches below the point of en-

trance, The lower fragment overlaps and projects in front of the upper, The callus is smooth and regular on the inner surface of the shaft of the tibia, but is irregular behind. Union has occurred securely, but the lower fragment is directed backwards and, therefore, the tibia presents an anterior angular deformity.

Longitudinal section has been made. The overlapping of the fragments is well shown.

Presented by Dr. Mütter.

1442.12- Right tibia. Oblique fracture in the upper third with deformity.

1379. 39 3

There is outward bowing at the seat of fracture. The spine of the tibia is sharp.

Presented by Dr. Mütter.

1442.13- Superior two-thirds of left tibia and fibula. Transverse fracture of the head of the tibia. Previous amputation at the lower third.

1380. 39 3

The fracture was transverse and did

not completely sever the head from the shaft. The line runs 3.3cm. below the inner head and half way around the fibular side.

At the lower end the evidence of a previous amputation is seen. The medullary cavity is closed in the fibula; a smallopening remains in the tibia. A portion of the interosseous membrane has been preserved.
H.H.S.

Purchased.

destroyed

1442.14- Right tibia(Plaster cast). Oblique fracture of the head. Union with great deformity.

1381
39
3

The plane of fracture passed from a point in the crest 11cm. below the head upward and backward to the popliteal notch. The lower fragment was displaced backward.

The callus is abundant and the displacement of the fragments enlarges the upper extremity of the bone.
H.B.Tuson fecit.

Purchased.

1442.15- Left tibia. Oblique fracture of the shaft. Union.

1382
39
3

The plane passed from the spiral line downwards and forwards to the crest above the middle. Extensive shortening from overlapping of the fragments has occurred. The adjacent ends of the fragments are depressed.

Vertical section has been made. The medullary canal extends to the level of fracture where the trabeculae of spongy tissue extend to the articular surface.

Presented by Dr. Mütter.

1442.16- Left tibia. Oblique fracture of the shaft. Union.

1383.
39
3

The plane passed from the posterior surface downwards and forwards, terminating at the middle. Union has occurred in good position, the line of fracture being marked by a bony ridge of callus in the subcutaneous surface.

Vertical section shows a continuous medullary cavity.

Presented by Dr. Mütter.

1442.17- Right tibia and fibula. Fracture of
1384. the tibia in the upper third. Union.
39
3

The fracture occurred 10cm. from the head of the bone. It has firmly united and the lines of fracture are obliterated. The lower fragment has a decided tendency inward. Posteriorly the surface is marked by a ridge of callus in the spiral line.

Presented by Dr. Mütter.

1442.18- Left tibia. Oblique fracture of the
1385. shaft. Union.
39
3

The plane passed from a point 7cm. below the outer head downwards and inwards 5cm. in vertical extent. Union has occurred with the lower fragment pointing to the inner side, deviating 5cm. at the ankle-joint.

Presented by Dr. Mütter.

1442.19- Tibia and fibula. Oblique fracture
1475. of the tibia at the upper third. Luxa-
41
3 tion of the fibula.

The plane of fracture passed from

the popliteal space obliquely downwards and forwards emerging on the crest three inches below the tubercle. Posteriorly there seems to have been a detached fragment nearly five inches long, which is now well united to the shaft. The head of the tibia, comprising the upper fragment, overlaps the lower; the head of the fibula has, therefore, been forced upward above the head of the tibia, the displacement amounting to one and a quarter inches. The lines of fracture are comparatively smooth, are marked by permanent callus and present sinuses on the inner and posterior sides.

The inner malleolus is marked by a lamellar exostosis curving backward and outward, a deep sulcus lying between it and the posterior inter-malleolar space.

The fibula is quite rough along its margins and at its head is co-ossified with the tibia,

Presented by Dr. Mütter.

1442.20- Left tibia and fibula. Fracture of
1476. the tibia. Union.
41
3

The fracture occurred above the middle. The fragments are well united and

no trace is left of the direction which the fracture took. The upper fragment is united with the fibula through 4.5cm. and it has a slight tendency toward the fibular side. The surface of the bone is smooth throughout.

Dissecting-room specimen.
W.S.F.

Purchased.

1442.21- Comminuted oblique fracture of the head of the tibia;right.

1446
41
4

The femur,of which the lower third is present,is intact. The tibia has been removed above the ankle and illustrates union after comminuted oblique fracture of the head involving the knee-joint. There are three fragments. The line of fracture traverses the outer head of the tibia at its middle and in the antero-posterior line;passing directly downwards for an inch,it then divides;one branch quickly reaches the outer shaft and inch and a half below the outer head;the other branch passing obliquely downwards,inwards and backwards below the tubercle, cuts off a wedge-shaped piece of the tibia,the point of which is situated three

and three quarter inches below the inner head, This leaves the shaft of the tibia lying between the upper fragments forcing them apart, and rotated outwards about 30°. The fragments are firmly co-osified. There is half an inch shortening. Anteriorly, the line of union is smooth and well rounded. Posteriorly, the eversion of the leg has caused a sulcus between the upper wedge-shaped fragment of the tibia and the shaft. The edges are smooth and free of osteophytes. The patella, its ligament and the tendon of the quadriceps, the lateral and crucial ligaments and semilunar cartilages are preserved.

Presented by Dr. Mütter.

1442.22- Right tibia and fibula. Gunshot fracture of the shaft. Union.

1497.
41
4

The fracture occurred at the junction of the middle and upper thirds. The fragments have united, leaving an opening from the subcutaneous to the fibular surface.

H.H.S.

Purchased.

1442.23- Right tibia and fibula. Oblique comminuted fracture of the shaft of the tibia.
1509
37
4 Recent.

The plane passed from the posterior surface downwards and forwards through a vertical extent of 8cm. A few small detached fragments are seen in the crest.
H.H.S.

Purchased.

1442.24- Right tibia and fibula. Oblique fracture of the tibia below the middle. Union.
1498.
41
4

The plane passed from behind, in the middle of the shaft, downward and to the crest, measuring 4cm. in vertical extent. The fracture is firmly united. There is some sinking of the lower fragment causing prominence of the sharp extremity of the upper fragment.

Presented by Dr. Mütter.

1442.25- Right tibia. Fracture below the middle. Union.
1477
41
3

There is a decided thickening of the bone below the middle and a depression of the crest. The condition is one of long

standing, probably a fracture. The surfaces are smooth.

Dissecting-room specimen,
W.S.F.

Purchased.

1442.26- Shaft of left tibia. Fracture of the shaft. Union with caries and condensing ostitis.

1508?
37
4
1308

Fracture probably occurred at the middle. At this point the line of the crest retreats. The anterior surface, especially on the fibular side, is extensively eroded. No smooth surface of compact tissue is present.

Vertical section shows condensing ostitis with obliteration of the medullary canal. The sawn surface is hard and dense like ivory. In the upper portion of the shaft, the compact tissue is seen to be overlaid with a periosteal deposit.

Presented by Dr. Mütter.

1442.27- Right tibia. Double oblique fracture of the shaft. Union.

1478
41
3

The higher fracture extended from a point in the posterior of the bone at the middle downwards and forwards to the crest 12cm. above the ankle; the second fracture began slightly lower, extending in the same direction and terminating 3cm. from the ankle. The upper fragment is prominent and overlaps the middle fragment. All the lines of union are smooth, strong and free from undue vascularity. Posteriorly, there are two small exostoses.

Vertical section shows beautifully the reparative change. There is a nearly complete septum between the middle and lower fragments.

Presented by Dr. Mütter.

destroyed

1442.28- Left tibia. Transverse fracture of the shaft. Union. (Plaster cast).

1479
41
3

The fracture occurred at the junction of the middle and lower thirds and was transverse. Union with anterior angular deformity has occurred. The callus is smooth and presents no undue prominence.

H.B.Tuson fecit.

Purchased.

1442.29- Left tibia. Oblique fracture of the shaft. Union.

1480
41
3

The shaft was broken at the junction of the middle and lower thirds. The plane passed from the outer side obliquely downwards and to the subcutaneous surface 9cm. from the inner malleolus. Union has occurred in bad position. The lower fragment has been carried abruptly to the inner side. The upper articular surface has been lost prior to mounting.

Presented by Dr. Mütter.

1442.30- Left tibia. Oblique fracture of the shaft. Union.

1481.
41
3

The shaft has been fractured at the junction of the middle and lower thirds. The plane passed from the fibular side downwards and inwards. Union has occurred with slight anterior angular deformity and the callus is smooth and well rounded. Portions of the upper and lower extremities are missing.

Dissecting-room specimen.
W.S.F.

Purchased.

1442.31- Left tibia. Oblique fracture of the
1482 shaft. Union.
41
3 The fracture occurred at the junction of the middle and lower thirds. The plane passed from the fibular side downwards and inwards. There is almost no trace of the line of union.

Presented by Dr. Mütter.

1442.32- Left tibia and lower third of the
1483 fibula. Periostitis and anchylosis of
41 tibia and fibula following fracture.
3 The disease is confined to the lower half of the tibia and was doubtless syphilitic. The bone is thick and round and attached to the fibula at the lower third by means of new bone. Both malleoli have been accidentally broken in making the preparation, owing to the frailty of the specimen.

Presented by Dr. Mütter.

1442.33- Left tibia. Fracture of the shaft at
1484 the lower third. Union.
41
3 The fracture seems to have been almost transverse at a point 11.5 cm. above

the joint. Union has occurred with little superabundance of permanent callus. The line of the crest is broken by a slight backward displacement of the upper fragment; the lower fragment is bent slightly inward.

Presented by Dr. Mütter.

1442.34- Right tibia. Oblique fracture in the lower third. Union with backward displacement of the lower fragment.

1485
41
3

The plane of fracture passed from a point in the posterior surface 11cm. above the articulation downward and forward to the crest through a vertical extent of 6 cm. The upper fragment overlaps the lower and makes a marked prominence anteriorly. There is also a slight outward displacement.

Purchased.

1442.35- Left tibia. Gunshot fracture of the lower end. Spherical ball remaining.

1486
41
3

The amount of callus about the lower extremity makes it impossible to say at

what point the ball entered. The bone is considerably thickened at the seat of fracture. The callus is smooth, but covered with vascular openings.

Longitudinal section shows a sphenoidal musket ball slightly flattened; having a diameter of 1.2 cm., and lying in the cancellated tissue 3.5cm. above the articular surface. There is an irregular cavity in the cancellated tissue at this situation, communicating with the medullary cavity and, by means of sinuses leading through the compact tissue, with the surrounding soft parts.

From a soldier in Blucher's army wounded in the battle of Waterloo. The man lived for many years after the injury. His wound would heal occasionally and break open again.

Presented by Langenbeck of Berlin, to Dr. William S. Forbes of Philadelphia.

Purchased.

1442.36- Right tibia. Oblique fracture in the
1487. lower third. Union with displacement.
41
3 (Plaster cast).

The plane of fracture passed obliquely

from the fibular side downwards and inwards, occupying 6cm. of vertical extent. Considerable shortening has occurred with displacement of the lower fragment upward and on the fibular side.

H.B.Tusom, London, fecit.

Purchased.

1442.37- Right tibia. Oblique fracture lower third.

1488. 40 3

Presented by Dr. Mütter.

1442.39- Left tibia. Oblique fracture of the shaft. Union.

1489. 40 3

Fracture occurred at the junction of the middle and lower third. The plane passed from the posterior side downwards and forwards. There is an opening with rounded edges, on the fibular side, leading to the interior of the bone. The fracture is well united. The line of the bone is good and the callus is smooth.

From a man aet.32. Four years previously he fell down a gravel bank sustaining a compound fracture of the leg, the flesh being torn up from the bone at the

point of fracture, The fracture box and bran dressing of Physick, were used and the man made an excellent recovery and had a perfectly useful limb. Four years later he was killed in a fray.
W.S.F.

Purchased.

1442.40- Right tibia. Oblique fracture in the lower third. Union.

1507?, 37 4 1307

Starting from a point in the posterior and inner surface 13cm. above the malleolus, the plane of fracture ran obliquely downwards and forwards, terminating 3cm. above the joint. Anteriorly and on the fibular side, there are two openings in the compact tissue communicating with the medullary cavity. There is a slight exostosis at the extremity of the upper fragment.

Union has occurred in good position.

Presented by Dr. Mütter.

1442.41- Left tibia. Oblique fracture of the lower extremity. Union.

1490. 40 3

The plane passed obliquely from a

point on the fibular surface 5cm. above the joint obliquely downwards and inwards, terminating 3.5cm. above the inner malleolus. Union has occurred with slight displacement toward the fibular side. The callus is smooth and free from vascular channels.

Presented.

1442.42- Left tibia. Fracture of the internal malleolus. Syphilis.

1522
40
4

The malleolus was fractured transversely. The line of fracture is seen in the articular surface occupying the angle between the horizontal and vertical portions and marked by a depression owing to absorption of callus. The deep grooves in the subcutaneous portion, having a general vertical direction indicate syphilis. This is borne out by a node in the crest at the middle, which breaks decidedly the anterior line of the bone.

Presented by Dr. Mütter.

1449.21
~~1442.43~~- Right tibia. Hypertrophic ostitis.

1491
40
3

The head of the bone is lacking and

the internal malleolus has been accidentally lost. The general appearance of the bone would suggest syphilis. The line of the crest is undulating. The subcutaneous surface is irregular, especially below the middle where there were doubtless chronic ulcers. An irregular patch 12cm. long presents in its lower portion the appearance of the finest sponge or moss. The line of the interosseous septum is marked by osteophytes and the spiral line is exceedingly rough.

vertical section shows well the hypertrophy of the compact tissue. This has a thickness in the middle of 1.8cm., the diameter of the bone being, at this point, 4.3 cm. diminishing at the lower third to 3.5cm. The medullary canal is patulous. The inter-trabecular spaces of the spongy tissue above the ankle, are enlarged.

Presented by Dr. Mütter.

1442.44- Bones of left lower extremity. Oblique fracture of the tibia. Union. Ostitis; exostosis.

1523
40
4

This is a striking specimen. Section has been made at the lower end of the

femur. The fracture of the tibia began in the crest of the tibia below the tubercle and passed obliquely downwards and backwards. A fragment was probably detached at the outer side of the tubercle and is now united with the bone. The fibula was not fractured, but its head was dislocated and extends just above the joint. The latter does not seem to have been impaired. The whole leg has been carried inwards, the heel resting 9cm. inside of the proper line. Both bones of the leg are remarkable for the extent of periostitis and ostitis. It pervades the tibia below the middle and the fibula throughout its whole extent. The latter bone is nowhere smooth. It is extremely vascular and may be said to be in a condition of osteoporosis. The tibia is most markedly affected posteriorly and above the joint. Both bones are in contact for 10 cm. at the lower end.

Presented by Dr. Mütter.

1442.45- Right tibia and fibula. Gunshot fracture of the tibia.

1492
40
3

The fracture involves the entire middle third. Six fragments remain and many

are lost. The lines run in all directions.

From a soldier who died without an operation a short time after receiving a fracture from a conoidal ball.

Pres. By the Surgeon General, U.S.A.

1442.50- Right tibia. Gunshot fracture of the
1493 shaft. Comminution.
40
3

The fracture involves the upper two-thirds of the bone. Longitudinal fracture lines are seen extending through 24cm. Seven fragments are seen.

From a soldier who underwent amputation below the knee after fracture from a conoidal ball.

Pres. by the Surgeon General, U.S.A.

1442.55- Left tibia. Oblique fracture of the
1524 shaft. Union.
40
4

The bone is well united; the callus having only slightly increased the thickness of the bone. The only exostosis is situated posteriorly at the middle and points downward. Otherwise, the bone is smooth.
H.H.S.

Purchased.

1442.60- Middle third of right tibia. Oblique
1494 fracture. Union.
40
3 The fracture extends through 8cm. in vertical direction. Union has occurred with slight overlapping. The callus has a smooth outline and is free of vascular channels.
H.H.S.

Purchased.

1442.65- Portion of left tibia and fibula.
1495 Fracture of the tibia.
40
3 The bones have been sawn close to the knee-joint and at the junction of the middle and lower third. The fracture occurred at the junction of the middle and upper third; was oblique from the fibular side downwards and inwards and is well united with very little redundant callus. There is a slight displacement of the fibula upwards.

1442.70- Shaft of the left tibia.
1506 The specimen has been sawn and cut
37
4 by some sharp instrument at the middle of the crest, so as to expose the medullary cavity.
No history.

Presented by Dr. Mütter.

1442.75- Lower ends of both tibae and shaft of the right fibula. Oblique fractures.

1505
37
4

The right tibia was severely shattered. The specimen presents a wedge-shaped fragment from which the anterior surface has been broken. Lines of fracture run vertically. One courses in a spiral line from a point 15cm. above the posterior edge of the articular surface, along the outer, and obliquely across the anterior surface of the bone, terminating in the inner malleolus. Another line passes vertically toward the inner malleolus where it ends in a zigzag line.

The fragment of the left tibia shows an oblique fracture with a perfect spiral line in one complete turn. This line is 12 cm. long.

The right fibula was fractured obliquely. The plane begins near the head and passes from the outer side downwards and inwards and measures 4.5cm. in vertical extent.

✓ missing

1442.80- Lower ends of left tibia and fibula
1376 and tarsus. Old Pott's fracture. Union
38 with deformity.
3

The foot was sharply displaced to the outer side.

Presented.

✓ 1442.90 Lower portions of tibia & fibula including foot.
The patient, Raymond Parlen, had a fracture of both bones of both legs in 1924. That of the left was compound, comminuted; treated by a steel pin thro calcaneum for traction. Recovery with non-union. Wound healed one year after injury but reopened after 3 years & in Feb. 1928, leg was amputated. Note hole in calcaneum, where steel pin was.

Presented by Mrs. A. P. C. Ashhurst & E. T. Crossan.

✓ 1442.92 Ankle Fracture B2 (Compound)
Second fracture of lower end of tibia produced when this bone burst thro the skin & stuck into the ground.

Presented by Mrs. A. P. C. Ashhurst & J. A. Bolger. BOGER

✓ 1442.94 Right foot and portion of the tibia and fibula:-
Fracture of the lower end of the tibia
Presented by Dr. John H. Brinton.

1365

Diseases of the Leg and Foot and Joints.

1447
to

1728.

1367

144700 Tibia, caries Presented by Prof. George N. Chase

1447.10- Left tibia. caries of the head and upper epiphysis.

The bone is from a young person about fifteen years of age. The epiphysial lines are well marked; the lower epiphysis has been detached and lost. The upper epiphysis and the shaft of the bone as far as the insertion of the tendo patellae is carious. Both heads are rough from erosion. No trace of cartilage is present.

DISEASES OF THE LEG, FOOT AND JOINTS.

1447

1447.20- Right tibia. caries. Periostitis.

1728.

The bone is a young subject approximating adult age. The upper epiphysis is complete. The lower lacks the portion forming the internal malleolus. The outer half of the upper third of the bone is quite healthy. The subcutaneous portion is the chief seat of disease. It is eroded and excavated up and down the shaft. Periosteal efforts at the formation of new bone are made, suggest necrosis, but no sequestrum is visible. The surface of the bone is rough and generally marked by shallow vascular openings. Two fistulous openings are seen in the lower superior anterior portion of the shaft.

1369

1447.05 Tibia; caries Presented by Prof. George McClellan.

1447.10- Left tibia. cariesof the head and upper epiphysis.

1504
37
1304

The bone is from a young person about fifteen years of age. The epiphysial lines are well marked; the lower epiphysis has been detached and lost. The upper epiphysis and the shaft of the bone as far as the insertion of the tendo patellae is carious. Both heads are rough from erosion. No trace of cartilage is present.

Presented by Dr. Mütter.

1447.20- Right tibia. Caries. Periostitis.

B03
37
4

The bone is from a young subject approaching adult age. The upper epiphysis is missing. The lower lacks the portion forming the internal malleolus. The outer half of the upper third of the bone is also lacking. The subcutaneous portion is the chief seat of disease. It is gouged and excavated up and down the shaft. Partial attempts at the formation of an involucrum would suggest necrosis, but no sequestrum is visible. The surface of the bone is rough and generally marked by minute vascular openings. Two fistulous openings are seen in the lower subcutaneous portion of the shaft.

Vertical section shows no well marked boundary between the compact and spongy substance. The fistulous openings lead to separate cavities. The lower is the larger. In the middle of the shaft concentric layers of compact tissue increasing the diameter of the bone, indicate the presence of periostitis.

1447.25 see vol I page 1411 Purchased.

1448- Left tibia and lower end of femur.
1302
1302
37
4
Necrosis of the diaphysis and epiphysis of the tibia.

The specimen is taken from a boy of about fifteen years of age. The epiphyses are united and the entire length of the tibia is 29cm. The greater portion of the tibia has died en masse, forming a sequestrum extending nearly the wholelength of the bone. As viewed through the cloacae this sequestrum embraces, at least in the subcutaneous portion, the outer layer of compact tissue, the smooth surface of which is preserved, and also to a great extent the spongy substance. The borders of the sequestrum are very irregular. Jagged and fantastic prolongations extend upward and downward according to the level at which

the blood supply ceased. The sequestrum is not loose and below the middle consists of several pieces. The sequestrum embraces the central portion of the diaphysis adjacent to the epiphysis. No sequestrum is seen in the epiphyses although there are deep carious excavations. In the head the outer facette presents a pit about 2cm. in diameter, but which does not perforate the whole thickness of the epiphysis. The inner head presents an irregular, deep excavation leading to a cavity in the expanded portion of the tibia. The spine is carious. The upper portion of the shaft is thoroughly disorganized. The discharges escaped through several not very large outlets. One of these is situated near the inner side of the insertion of the ligamentum patella and others along the external border of the bone.

The involucrum is well constructed to preserve the strength of the bone, but closely impris ns the sequestrum. This bony envelope increases uniformly to the size of the tibia. It has a symmetrical outline, is extremely vascular and is furrowed in all directions by channels for the blood vessels. The only compact tissue remaining in the specimen appears to

1375

belong to the sequestrum. Viewed from the fibular and posterior sides the involucrum is a continuous, perfect sheath; only in the upper third a small fistulous opening is seen. The surface has a warty appearance, the dividing channels being extremely narrow in proportion to their depth. In the subcutaneous portion, however, nomerous large cloacae are distributed. They have a vertical extent of 1,3, 4 and 5 cm. increasing from the ankle upward. Their breadth is about 2 cm.

The lower epiphysis is nearly destroyed by caries. Merely a ring remains surrounding a central opening having a diameter of 2.5cm.

The femur is slightly roughened, especially above the condyles and at the inter-condyloid notch.

Case of John S., aet.12. Limb amputated for necrosis following a fall which occurred about one year previously. The patient did well after amputation, gaining rapidly in flesh and strength.

Presented in 1865 by
Dr. John Ashhurst, Jr.

1448.10-
1501
97
1301 4

Shaft of the tibia. Necrosis and periostitis.

The specimen consists of 17cm. of the

shaft of the tibia, probably on the left side. The surface is rough, deeply excavated and marked by capacious channels for the blood vessels. There is no smooth compact tissue.

Vertical section shows an irregular arrangement of the compact tissue. In some places it islacking, while in others it is unusually thick and augmented by periosteal deposit. The medullary canal is not patulous, but is occupied by an irregular arrangement of spongy tissue.

Presented by Dr. Mütter.

1448.20- Right tibia. Necrosis.

1300 37 4 1300

The shaft from a point of 5cm. distant from the head nearly to the ankle, was in a state of necrosis. The line of demarcation, especially at the lower portion, is distinct. The sequestrum is not loose. Its surface is rough. No involucrum has formed excepting to a slight extent over the lower portion and chiefly on the fibular side. The extremities are intact.

Presented by Dr. Mütter.

✓ missing?

1448.30- Upper third of left tibia. Necrosis.

1499
37
4

The articular surface and a portion of the outer head are the seat of disease. The spongy tissue is exposed over the entire articular surface. A sequestrum probably has separated from the outer tuberosity, leaving a cavity 3 x2 cm., the walls of which are not indurated, but show a trabecular arrangement. The subcutaneous surface is smooth, becoming rougher as it approaches the joint.

Presented by Dr. Mütter.

✓ 1448.40- Upper end of right ribia. Necrosis of outer facette.

1298
37
4

The outer facette presents a large cavity, having a diameter of 3cm. Within this cavity, there is a loose portion of the articular surface and subjacent spongy tissue, which probably separated as a sequestrum. The tuberosities of the bone are rough and the borders of the articular surfaces are worse and expose the spongy tissue.
H.H.S.

Purchased.

✓ 1448.50- Necrosis; advanced.

1297
37
4

In this remarkable specimen, the sequestrum measures over 28cm. in length;

it is tubular and consists of the inner layer of the compact tissue and corres ponding spongy tissue. It is not loose but adherent chiefly posteriorly. The involucrum covers the sequestrum wholly in the middle covering 8cm. of the crest; above and below the sequestrum is exposed. Its surface is rough, but conforms more or less to the original contour of the bone. Its color is whiter than that of the involucrum. No vascular channels mark the sequestrum.

The involucrum presents a decided contrast. It is porous. Its surface is comparatively smooth and is continuous with the extremities of the bone, which have preserved their natural shape. The head of the bone and its articular surface has lost its thin shall of compact tissue and the spongy portion is exposed to view. This, however, is probably a post-mortem condition.

Presented by Dr. Mütter.

1448.55- Left tibia;necrosis,periostitis.
1296
37
4

The shaft has been extensively necrosed on the outer border below the middle leaving a large vacancy,exposing the medullary cavity for 6cm.

presented by Dr.A.S.Roberts.

1448.60- Left tibia and astragalus. Necrosis; advanced.
1295
37
4

In this case the disease is chiefly confined to the lower half of the tibia and to the astragalus. The sequestrum is 15cm. in length and embraces the inner portion of the compact portion and the contained spongy tissue. The sequestrum is loose;excessively fenestrated and of irregular outline. The space between the sequestrum and in the involucrum,as the specimen lies on the table,varies between .5 and 1cm.

The involucrum,ensheathing the sequestrum,was in a state of active organization. Posteriorly it is unbroken and is continuous with the bone proper. Through a large opening 11cm. in length in its

subcutaneous portion, the sequestrum is well seen. Below this are three other cloacae capable of admitting the finger. Another series of cloacae, of larger size, is seen in the fibular and posterior surfaces. The surface of the upper portion of the bone is in a great measure denuded of compact tissue. The head of the bone above the epiphyseal junction is lacking.

The articulation with the astragalus was invaded. A portion, however, of the cartilage remains. The astragalus is almost wholly deprived of compact tissue and the spongy substance is seen to be extensively eroded.

The general direction of the tibia is changed. Above the middle the bone bows forward.

Presented by Dr. Mütter.

1448.70- 8.5cm. of the shaft of the tibia.

1294
36
4

Necrosis.

The necrosed portion is circumscribed and occupies a portion of the crest of the bone with the fibular surface. It is 3cm. in vertical extent by 2cm. horizontally. It is firmly adherent to the shaft. Periosteal deposit is seen on the fibular side of the shaft, where longitudinal striations and vascular openings abound.

H.H.S.

Purchased.

1448.80- Arthritis of knee-joint; extensive necrosis of tibia.

1293
36
4

The bones of the left leg and the lower extremity of the femur are present and illustrate in a striking manner rapid disorganization of the knee-joint and tibia in a child aet.13. The femur is intact, excepting at the tuberosities which have been injured, apparently, only in the process of preparation. The patella is unaffected. The upper epiphysis of the tibia is almost wholly destroyed.

The inner head is wholly gone; of the outer head very little remains excepting a shell of bone and cartilage, with a large

1449
1291
36
4

opening in the centre, and strongest in its external aspect. Excepting just below the head, the entire shaft of the tibia is necrosed. The lower two thirds rapidly forming large sequestra and having attached to it irregular osteophytes. The fibula is only superficially affected at its lower extremity. The ankle-joint seems to have been intact.

Case of Gottlieb H., aet. 13, admitted to the Episcopal Hospital, Philadelphia, Feb. 16th, 1865, suffering from disease of the left knee-joint and necrosis of the corresponding tibia, the result of a fall received about one year before. Amputation at the lower third of the thigh was performed Feb. 17th, 1865 by Dr. John Ashhurst, Jr. Patient recovered and was discharged within ten weeks.

Trans. College of Physicians of Phila.

Vol. 11, New series, p. 67, Case XI.

Presented by Dr. John Ashhurst, Jr.

1449- Left tibia. Hypertrophic periostitis and caries.

1292
36
4

The extremities are most comspicuously affected. Only in the shaft below the middle does the bone show its characteristic shape. The upper articular surface is wholly changed. There is no spine or other means of dividing the outer from the inner head. This surface slopes off toward either side and presents no cartilage and only traces of compact tissue. In the inner head are several irregular openings leading to a spacious cavity. In the anterior portion of the outer head is an opening which leads down the outer surface of the shaft, beneath an encircling band of new formed bone resembling an involucrum. Vascular channels and deep grooves abound especially posteriorly. The surface is quite rough and has a profuse vascular supply.

The lower end is the counterpart of the upper end. No articular surface is to be recognized. On either side sinuses lead to the medullary cavity.

Vertical section shows the arrangement of the hypertrophy. The original shaft of compact tissue is seen possessing its regular shape; encircling this at

either extremity is seen the layer of bone superimposed by the action of the periosteum. This layer increases in size as it is traced from the centre to the extremity. It is extremely vascular. The section has been made through the channel of the nutrient artery and may be traced through an extent of 8cm. Its course through the hypertrophic layer is marked by an abundance of capillary openings. This hypertrophic layer is seen in the section to have a not very intimate attachment with the shaft proper. No spongy tissue remains in the medullary cavity below the middle. Above it is of a dark rusty color, not of a loose texture, but comparatively dense.

No articulating surfaces for the fibula are apparent.

presented by Dr. Mütter.

1449.02- Left tibia. Hypertrophic ostitis.

1291
36
4

Both bones are enlarged in their middle third. This is more noticeable in the fibula than in the tibia. The crest of the tibia is regular; the subcutaneous surface is smooth but posteriorly, especially in the spiral line, the surface is rough.

Section of the tibia in the vertical line shows great increase of the compact tissue in the middle third. The medullary cavity is present but encroached upon.

H.H.S.

Purchased.

1449.04- Shaft of left tibia. Rarifying hypertrophic ostitis.

1290
36
4

The specimen is light, probably from an old subject and has lost its extremities. The upper portion of the shaft measures 4cm. antero-posteriorly and 2cm. laterally. The compact tissue at both ends is thin-.5 to 1.mm. in thickness. The spongy tissue is delicate, friable and the intertrabecular spaces are very large. The medullary cavity is also large. At the middle the bone is spindle shaped, having a greatest circumference of 13cm.

The surface is rough but of a gently swelling contour. It is extremely vascular and spongy-like. The openings are mostly capillary. The disease is situated chiefly on the subcutaneous surface, but occupies the entire circumference. The posterior line of the bone is nearly straight, slightly concave; anteriorly it is convex. There are no exostoses.

Presented by Dr. Mütter.

1449.06- Shaft of left tibia. Condensing os-
1289 titis. Periostitis.
36
4

This specimen is heavy. The disease occupies the middle and lower portion of the shaft, chiefly the subcutaneous portion and is of long standing. The compact tissue at the nutrient foramen has a thickness of from three to ten millimeters and resembles ivory in cross-section. Below this point the crest becomes prominent and thick. The periosteal deposit has a thickness anteriorly of 6 or 8 mm; it is vascular and marked by deep vertical fissures, which are noticeable posteriorly. The true shaft is exposed at the lower subcutaneous portion and shows evidence of absorption. The medullary cavity at the upper end has a diameter of nearly 1cm. It is probably closed through most of the shaft. There is an unbroken surface of spongy tissue at the cross-section above the malleolus.

Presented by Dr. Mütter.

1449.08- Lower two-thirds of left tibia and
1288 fibula. Ostitis.
36
4

Both bones are equally involved; their surfaces are rough and cariously marked by

osteophytes having broad bases. The space between the bones is reduced to a minimum and in many places bridged over by the out-growth.

Vertical sections have been made.

H.H.S.

Purchased.

1449.10- Right and left tibia from the same subject. Hypertrophic ostitis. Syphilis.

1287
3b
4

Except at the articulations the disease affects all the surfaces. It is most noticeable in the subcutaneous surfaces. These are rough and porous. The spiral lines are also rough. The line of the crest is irregular, owing to undulations.

Vertical section shows thickening of the compact tissue. The inter-trabecular spaces seem large

From some individual as Fib.23 and 24.

H.H.S.

Purchased.

1449.12- Right tibia. Hypertrophic ostitis.

1286
3b
4

The exterior of the bone is comparatively smooth. The line of the crest is undulating and is prominent in the middle third.

Vertical section shows hypertrophy of the compact tissue amounting to 2cm.

anteriorly at the middle. Probably a case of syphilis.

Presented by Dr.Mütter.

1449.14- Left tibia. Syphilitic ostitis.
1386
38
4

At the upper third there is a slight enlargement of the bone consisting chiefly of an hypertrophy of the compact tissue. Deep vertical striations in the subcutaneous surface point to syphilitic disease.

Longitudinal section shows the hypertrophy of the compact tissue in the crest of the bone.

Presented by Dr.Mütter.

1449.16- Left tibia;inner half. Hypertrophic ostitis. Syphilis.
1387
38
4

The specimen has been sawn vertically. The compact tissue is thickened throughout the upper three-fourths of the shaft. The antero-posterior diameter at the junction of the middle and upper third is 4.4cm. against 2.3cm. above the malleoli. On the inner side below the middle are seen numerous vertical grooves having a breadth of usually .5 mm. and a depth of.5 to2.mm. These are characteristic of syphilitic disease. The general surface of the bone is

not very rough. The line of the crest is undulating. The spiral line is well marked.

Presented by Dr.Mütter.
System of Human Anatomy,Harrison Allen,
Phila.,188 Vol. p.

1449.18- Right tibia. Ostitis. Syphilis.
1388
38
4

The disease is seen chiefly below the middle. It occupies the entire circumference of the bone,the greater mass of the exostosis being situated on the inner and posterior surfaces,rough and abounding in vascular channels and showing the vertical depressed fissures previously referred to.

vertical section in a lateral direction shows the original outline of bone upon which has been imposed the new formation 10cm. in vertical extent and 1.5 in its greatest thickness. The line of the crest is irregular below the middle.

Presented by pr.Mütter.

1449.20- Right tibia. Hypertrophic ostitis.
1389
38
4

Syphilis.

The disease occupies the anterior and subcutaneous portion of the shaft of the bone below the middle. There is in this situation a decided increase in the thick-

ness of the compact tissue. The line of the crest is undulating; the surface of the growth is smooth, but in it there are seen minute channels. On the fibular side are seen fine vertical grooves with well defined and regular walls. The thickness of the compact tissue of the crest is seen, on vertical section, to be 1.3 cm.

Presented by Dr. Mütter.

1449.21 see vol I page 1351

1449.22- Right tibia. Condensing ostitis.

1390
38
4

The bone is strong and heavy. The surface of the shaft is for the most part smooth and well marked. The crest is prominent. Towards the extremities, the surface becomes rough. This is well seen at the upper extremity, where the surface is vascular and has more the characteristics of spongy tissue. The upper articular surface is rough, porous and shows no trace of compact tissue. In the subcutaneous portion 10cm. from the head are seen two fistulous openings, having diameters of .5 and 1.cm., leading to the medullary cavity. The lower portion ismarked anteriorly and on the inner side by projecting spines. The lower articular surface is normal.

Vertical section shows the center of the shaft normal, having a large medullary cavity. The upper and lower thirds are

the seat of condensing ostitis. The spongy tissue is firm, indurated and occupies the entire thickness of the bone at the junction of the middle and upper thirds. The fistulous openings alluded to, lead to a cavity in the upper extremity, having a length of 7cm. and a diameter of 2cm., reaching nearly to the articulation. Its walls are rough, irregular and consist of the indurated spongy tissue.

The lower third presents essentially the same appearance. The spongy tissue presents the same ivory-like hardness, but shows more of the trabecular arrangement. A cavity 6 x 1 cm. has indurated walls and is without outlet. A very beautiful arrangement of concentric compact bony layers is seen in the center of the shaft.

Presented by Dr. Mütter.

1449.24- Left tibia. Hypertrophic ostitis.
1391
38
4

Syphilis.

The disease pervades the bone generally. Ths thickness is increased, especially above the middle. The surface is comparatively smooth, but abounds in minute vascular openings, striations and deep grooves for the reception of bloodvessels.

Vertical section shows the increase of both the compact and spongy substances. The channel for the nutrient artery has been opened very obliquely and shows well its walls of compact tissue running through the spongy portion to the medullary cavity.

Presented.

1449.26- Fragments of the shafts of tibias illustrating hypertrophic ostitis, osteophytes, etc.
1392
38
4
H.H.S.

Purchased.

1449.28- Left tibia; outer half. Ostitis. Medullary abscess.
1393
38
4

The surface of the bone is rough, especially in the upper half and posteriorly. The line of the bone is curved with the convexity directed to the inner side. An abscess cavity measuring 8.5 x 3cm. lies in the upper third of the shaft. The spongy tissue, above and below, is indurated and there is in this specimen no visible outlet through the compact tissue. There are in the external surface none of the small vertical fissures described in previous specimens.
H.H.S. Purchased.

1447.25
1449.30
& 31- Right and left tibia from a young
1394 child. Caries.
38
4 The epiphyses are missing. The extremities of the shafts are superficially eroded. The specimens are 17cm. long.

Presented by Dr.Mütter.

1449.32- Left tibia. Periostitis. Exostosis.
1395
39
4 The subcutaneous portion of the bone is smooth, but below the middle is covered with fine vascular openings. The fibular side is rough, abounding in broad based osteophytes.

Presented by Dr.Mütter.

1449.34- Right tibia. Ostitis. Syphilis.
1396 The disease occupies the upper two-
39 thirds of the shaft and is seen chiefly
4 in the subcutaneous and posterior surfaces. These are smooth, of regular outline, vascular, and abound in vertical fissures.

Presented by Dr.Mütter.

1449.36- Left tibia. Hyperostosis. Caries.
1397 The bone is thickened, rough; marked,
39 especially posteriorly, by osteophytes.
4

The line of the crest is irregular and marked by three carious areas, measuring 2 x 3 cm., in the middle and lower portion of the shaft. Their vascular surface is in contrast with the surrounding compact tissue. Section of the bone shows compact tissue pervading almost the entire thickness of the bone near the middle and extensive induration of the spongy tissue of the shaft.

Two cavities are seen in the spongy tissue and are the only traces of the medullary cavity. The larger one, 3 x 1.5 cm. in extent, is distant 3.5 cm. from the ankle joint; the other, slightly smaller, is situated at the junction of the middle and upper thirds. The convergent arrangement of the spicules of trabeculae present a beautiful appearance.

Presented by Dr. Mütter.

1449.38- Right tibia. Ostitis.

1398
39
4

The middle and lower subcutaneous portions are the seat of the disease. The surface is undulating, comparatively smooth, not unduly vascular. Fine grooves running vertically are seen throughout the affected area. They are particularly noticeable just above the middle. Five centime-

ters above the internal condyle, there is a small exostosis about 1cm. long.

Presented by Dr. Mütter.

1449.40- Right tibia. Ostitis.

1399
39
4

The contour of the bone is irregular. The bone presents a convexity toward the inner side. There is a decided irregularity in this curve at the lower third.

Presented by Dr. Mütter.

1449.42- Left leg and foot. Excision of tibia.

1400
39
4

The specimen consists, first, of a portion of the shaft of the tibia, 19.5 cm. long removed by ex-section; also the limb removed at the knee-joint; the tendons and ligaments of the foot and leg have been dissected and many of the muscles preserved. The upper section was made 10cm. below the head of the tibia and the lower section 7cm. from the ankle-joint. The surfaces of section are smooth and a band, composed chiefly of the interosseous membrane and periosteum slightly ossified, connects the two extremities. The fibula presents no compensatory enlargement.

The portion of bone excised is rough, carious, thickened and condensed. Its med-

ullary cavity has been obliterated. The subcutaneousportion was the seat of painful ulcers and sinuses.

The specimen,accompanied by the following history,was presented by Dr. Packard:-

John Davis,aet.39,came under my care at the Episcopal Hospital in 1868. In Aug. 1864,he was a marine,and struck his leg against a timber on board ship,was taken to the Marine Hospital at Pensacola,and about a year later was discharged. He was admitted into the Pennsylvania Hospital in March 1866 and Dr.Agnew removed a piece of bone;after which,the leg healed,but only for two months,breaking out again as soon as he began to use it. In the same year,Dr.W.H.Pancoast trephined the tibia.

In 1867 he was at the clinic of the Jefferson College and was operated on both by Dr.Pancoast,Sr. and by Dr. Maury. Some bone was removed each time.

Jan.12th,1869,he was taken into the Soldiers' Home in Filbert Street and I exsected 7 5/8 inches of the tibia,leaving the periosteum. As there was only a slight attempt at the reproduction of bone,and he was enormously fat and heavy,on May 26th I amputated at the knee-joint by

an anterior flap. The stump did extremely well, except that he had some tendency to startings in it, which were controlled by hypodermic injections of morphia and by firm mechanical restraint. The discharge was very small from first to last. The ligature on the popliteal artery came away on the 13th day.

He continued to gain flesh, but had fairly good health until Jan. 1885, when he died--from what cause I do not know.

John H. Packard.

1449.44- Left tibia. Ostitis. Syphilis.

1401 39 4

The disease is situated in the upper third of the shaft chiefly anteriorly and laterally. The swelling is regular, but produces a marked prominence below the tubercle. It is extremely vascular, rough and marked by sunken channels for blood-vessels. The remainder of the shaft is apparently perfectly healthy.

Dissecting room specimen.
W.S.F.

Purchased.

1449.45- Tibia. Hypertrophic ostitis. Syphilis.

1402 39 4

The specimen shows advanced syphilis.

Presented by Dr. Mütter.

1449.46- Right tibia;lower three-fourths.

1403
39
4

Ostitis. Exostosis.

The disease is circumscribed and occupies an area 6.5 x 3.5 cm. in the crest and lower subcutaneous portion of the tibia. The surface is elevated;has projecting margins;is rough and had evidently been the seat of a chronic ulcer.

Vertical section through this area shows great thickening of the cancellous portion of the bone. The compact tissue is continuous over the affected area. There are no sinuses. The remainder of the bone seems normal.

Presented by Dr.Mütter.

1449.48- Left tibia. Periostosis. Exostosis.

1404
39
4

The disease has well defined boundaries. It occupies an oval space 6cm.long in the crest and subcutaneous portion of the bone just below the middle. This area is covered with fine vascular channels of capillary size. The exostosis is elevated about .5cm. above the general surface of the bone and was undoubtedly the seat of a chronic ulcer.

Presented by Dr. Mütter.

1449.50- Right tibia. Ostitis. Syphilis.

1405
39
4

The disease is seen in the upper half of the shaft. The subcutaneous portion presents a swelling with irregular elevations in the surface. The tissue is compact, not abounding in vascular channels but presenting sunken grooves, posteriorly and laterally for the reception of blood-vessels. Minute longitudinal striations are seen posteriorly at the middle. Vertical section shows condensation of the bone tissue. In the posterior portion, from the periphery to the center, the order of formation is compact tissue, spongy, compact, spongy.

Dissecting room specimen.
W.S.F.

Purchased.

1449.52- Right tibia. Hypertrophic ostitis. Syphilis.

1499
41
4

The disease is s en chiefly anteriorly and below the middle. The swelling is uniform and not marked by unusual prominences. The surfaces are comparatively smooth and, especially anteriorly, free from vascular channels. The hypertrophy is wholly in the compact tissue which, on vertical antero-posterior section, measures,

in the crest, 1.7 cm. The medullary cavity is not impaired.

Presented by Dr. Mütter.

1449.54- Head of left tibia. Arthritis of knee-joint.

1500
41
4

The specimen consists of 10 cm. of the upper end of a large tibia and illustrates chronic arthritis. The facettes are large and have overhanging lips whose margins are sharp. There is no spine, but betweem the facettes are seen two openings having a diamater of .5cm., which lead to the medullary cavity. The tubercle is high, its upper border being on a level with the joint. Small exostoses mark the surface of the shaft.

The medullary cavity is hollowed out close to the articulation and was doubtless the seat of abscess which, opening into the joint, brought on the changes in the articular surface.

Presented by Dr. Mütter.

1449.56- Upper end of right tibia. Exostosis.

1501
41
4

The specimen is from a powerful adult and shows two small exostoses, -one on the inner, and one on the posterior surface

8cm. below the joint.

Presented by Dr.Mütter.

1449.58- Upper end of right tibia. Abscess cavity.

1502
41
4

Vertical section shows a cavity 4.5 cm.long and 1.5cm. in diameter. It is situated beneath the crest and immediately below the tubercle. Its walls are indurated and posteriorly presents numerous openings into the spongy tissue. No external opening is seen. The inter-trabecular spaces are large.

Presented.

1449.60- Upper third of the right tibia. Ostitis.

1503
41
4

The surface of the bone is rough; the tuberosities are worn so as to show the spongy tissue. The cartilage and compact tissue of the articulation is gone.

Vertical section shows thin walls of compact tissue in the shaft. No spongy tissue remains except near the head where it is very delicate. A large amount of white calcareous matter remains in the head of the bone.
H.H.S.

Purchased.

1449.62- Upper end of the right tibia. Arthritis.

1504
41
4

The articular surface is very much changed, but little compact tissue remains. The plane of the inner facette is lower than that of the right. The expanding portion of the shaft and the tuberosities are marked by a close growth of osteophytes.

presented by Dr. Mütter.

1453.50- Osteo-sarcoma of left tibia.

1505
41
4

Of the tibia, only the head is the seat of disease. The head is enlarged, measuring 18 inches in its greatest circumference and extends upward in a shell-like form encircling the extremity of the femur. The only trace of articulation is a small eburnated surface 1/2 x 1/4 inches in the bottom of the cavity. This hollow space formed by the bone proliferation is ample for the reception of the ordinary human knee. The walls are rough, porous, very thick and solid; in this respect quite different from the specimen 1453.51. The most prominent feature is a pointed shield of bone extending upward seven inches from the inner head. The bone is well marked below and evidently belonged to a powerful adult.

Presented by Dr. Mütter.

1453.51- Osteo-sarcoma of the head of the
See Fem
J.P.32. tibia.

1506
41
4

The tumor is enormous, having measured, when recent, 32 inches in circumference. Longitudinal section has been made through the left femur, the lower fourth of which is present, the patella and the tibia which,

with the fibula, was divided transversely in the middle. The tumor has been dissected and mounted dry with only its bony attachments.

The femur is intact, except to a slight extent about the internal condyle. The patella measures two inches long and one and one-eighth inches thick. The antero-posterior diameter of the tumor as mounted measures nine inches; vertical, eight inches.

The wall of the tumor at the line of section consists of a thin shell of bone varying in thickness from one-fourth to one-thirty-second of an inch. This shell of bone bounds the entire mass. The exterior is round, symmetrical, slightly lobulated superiorly. The interior contained evidently semi-solid matter which has been to a large extent removed, leaving a large cavity contained by the bony wall and resembling a vertical section of a human skull. The internal surface of the bone is rough and some irregular bands of bone run along the superior portion. The weight of the body has caused the femur to sink, producing a marked depression in the top of the tumor. The corresponding half of this tumor was presented to

This is a cross-index m.
(1453.58) Osteo - sarcoma of the
Number on Specimen tibia. Enormous. Sec 91- Sh 4
#6310.48 Vol. 2-Page 383

Prof. S.D. Gross.

Trans. Phila. Pathological Society,

Vol.IV.p.27, April 25,1872

Presented by Dr.R.E.Brown,
Mount Holly,N.J.

1454- 1509 Stump after amputation below the tubercle of the tibia,

The lower half of the femur,the patella and the heads of the fibula and tibia are present. Firm anchylosis between the femur and tibia has occurred. The patella is also adherent. The end of the tibia is smooth,covered with compact tissue and shows no sign of disease. The upper surface of the tibia and the external and posterior surfaces of the condyles are rough and friable. The head of the fibula is broken probably by accident after mounting;its surfaces are smooth. A portion of the shaft of the femur of the inner side is missing,measuring 1 1/2 x 1/2 in. The line of fracture running down toward the patella.

Presented.

1454.10- 1508 Upper third of right tibia, Stump after amputation.

The bone is 14cm. long and is healthy,

There is a slight roughness of the crest above the lower extremity. The end of the bone is completely covered over with compact tissue, affording a perfect protection for the medullary cavity. This surface is slightly rough, but not porous.

Presented by Dr. Mütter.

1454.20- Stump after amputation 11cm. below the right knee-joint.

1509
41
4

The bones are of normal size and shape and the medullary cavities are closed by a smooth layer of compact tissue.

1454.30- Head of left tibia. Stump after amputation. This specimen is 8cm. long and from a powerful man; the bone is healthy. Compact tissue has almost completely covered the medullary cavity. Two or three small openings are seen near the centre. The bone is uniformly smooth excepting at the outer tuberosity and slightly below.

1510
41
4

Presented by Dr. Mütter.

1454.35- Stump after amputation below the tubercle of the tibia; left.

1511
41
4

The extremity of the tibia is smooth and round and well covered with compact tissue. The specimen embraces half of the femur and the patella with its ligament attached. There has been some injury done the specimen in the loss of some compact tissue about the tuberosities of the femur and tibia.

1454.40- Stump after amputation in the lower third of the right leg.

1512
41
4

The bones are considerably thickened and the lower extremity where the fibula has a circumference of 11cm. They are also united for a small space near the end. The extremities are covered with a thick layer of compact tissue. The surface of both bones below the middle is slightly rough.
H.H.S.

Purchased.

1454.50- Stump after amputation 15cm. below the right knee-joint.

1513
41
4

The bones are of their natural size. Their surfaces are slightly rough. Their extremities are healed and the medullary cavities are closed by compact tissue. Section of the tibia shows no change of structure.
H.H.S.

Purchased.

FRACTURES OF THE FIBULA

1457

1457- Left tibia and fibula. Oblique fracture of the shaft of the fibula. Union.

1514
41
4

The plane of fracture begins at a point anteriorly 5cm. from the styloid process and passes downwards and backwards through 4cm. in vertical extent. The callus is smooth and not redundant.

Presented by Dr. Mütter.

1457.02- Right fibula, Oblique fracture below the head. Union.

1515
41
4

The fracture is close to the neck. Large projections of permanent callus mark the line of union. One, situated posteriorly, is directed downward. The bone is a strong one and well marked.

Presented by Dr. Mütter.

1457.04- Right fibula. Fracture below the head. Union.

1516
41
4

The fracture occurred about 4cm. from the extremity. Its exact line is obscured by permanent callus, which has united the fragments strongly.

Presented by Dr. Mütter.

1457.06- Right fibula. Oblique fracture of
1517 the shaft. Union.
41
4 The plane of fracture passes from a point on the inner side 7cm. below the styloid process and passes obliquely downwards and outwards through 3cm. in vertical extent.

Presented by Dr. Mütter.

1457.08- Right fibula. Oblique fracture. Union
1518 with great shortening.
41
4 The fracture occurred about 8cm. below the styloid process. The fragments have overlapped at least 8cm. and union has occurred. The callus is smooth and strong and not redundant. There is a space 1.5 cm. long between the overlapping fragments where there is no callus.

Dissecting-room specimen.
W.S.F.

Purchased.

1457.10- Right fibula. Fracture. Union with
1519 deformity.
41
4 The fracture occurred about 7cm. below the styloid process and was probably

oblique. The permanent callus is abundant and enlarges the bone antero-laterally. The upper fragment points backward and downward. The union is strong.

Presented by Dr. Mütter.

1457.12- Left fibula. Fracture of the shaft.
1525
40
4
Union with overlapping and deformity. Hypertrophic periostitis.

This is a fine specimen. The fracture occurred about 12cm. from the styloid process. The fragments overlap 4cm. and are united by a strong band of callus.

The upper fragment lies on the outer side of the lower, and points outside the lower malleolus. The bone is thickened throughout its whole extent and marked by abundant osteophytes. These are especially marked along the line of the interosseous septum. The surface abounds in vascular channels, especially on the tibial side.

Presented by Dr. Mütter.

1457.14- Portion of left fibula. Oblique fracture of shaft. Union.

1520
41
4

The specimen consists of 12cm. of the upper extremity of the bone. The fracture started posteriorly 5cm. from the head, passed obliquely downward and inward through 5cm. of vertical extent. Union has occurred without excessive callus, but the overlapping has caused pit on the tibial side.
H.H.S.

Purchased.

1457.16- Left fibula. Double oblique fracture of the shaft. Union.

1521
41
4

The plane of fracture started on the posterior surface 10cm. from the styloid process and terminated anteriorly 2cm. below the point of beginning. Sixteen cm. from the lower end a second fracture is seen. This is very slightly oblique. In this case the plane passed from the anterior surface downward and backward through 1.5cm. of vertical extent. The line of the entire bone is excellent.
H.H.S.

Purchased.

1457.18- Right fibula. Oblique fracture of
1526 the shaft. Union.
40
4

The plane passed from a point on the inner side 10.5 cm. from the styloid process and passed downward and outward through 3 cm. of vertical extent. The callus is not excessive and the line is excellent.
W.S.F.

Purchased.

1457.20- Left fibula. Fracture of the shaft.
1527 Union with great shortening.
40
4

The upper fragment was 13 cm. long and overlaps the lower 6cm. The upper fragment is situated posteriorly, the lower fragment pointing upward and forward and presenting a sharp point. The uniting callus is excessive and presents an outward prominence.

Presented by Dr. Mütter.

1457.22- Left fibula. Oblique fracture of the
1528 shaft. Union.

The plane of fracture starts on the posterior aspect 10cm. from the lower end and passes downwards and forwards through

2.5cm. of vertical extent. The union is strong. The upper fragment presents a slight prominence anteriorly.

Presented.

1457.24- Tibia and fibula;left. Fracture of
1529 fibula. Union.
40
4

The fracture occurred about the middle. The union is firm;no lines of fracture can be traced,but the contour of the bone swells at the point of fracture. The line of the fibula is perfect.

Presented by Dr. Mütter.

1457.26- Left tibia and fibula. Gunshot fracture of the fibula. Union. Missile remaining.
1530
40
4

The fracture occurred 10cm. from the lower end of the fibula and is well united with slight displacement of the lower fragment backward. The missile,a clay marble of 1.3 cm.diameter,is lodged between the tibia and fibula 7cm. from the styloid process. The marble is held in the interosseous membrane.
H.H.S.

Purchased.

1457.28- Left tibia and fibula. Fracture of
1531. the fibula. Union.
40
4

The fracture occurred 8cm. from the lower extremity. The bones are well united and the callus does not reveal the exact direction of the fracture. There is slight displacement of the lower fragment forwards. Both bones show exostoses, the tibia especially on its fibular surface. Vertical section of the tibia shows a slight increase of the compact tissue below the crest.

Presented by Dr. Mütter.

1534
40
4

1457.29- Right tibia and fibula. Fracture of
1532 the fibula. Union and anchylosis with
40 the tibia.
4

The fibula was fractured obliquely; the plane passing from a point in the tibial side about 10cm. from the lower end downwards and backwards 4cm. in vertical measurement. The bone is thickened at this point and is united with the tibia. A fracture has taken place, probably post mortem, at the junction of the middle and upper third of the tibia.

Presented by Dr. Mütter.

1457.30- Left fibula. Oblique fracture above
1533 the ankle. Union.
40
4

The line of fracture is smooth and the surface of the bone is almost natural. The plane passed from the outer side downwards and inwards, terminating 4cm. from the lower end.

Presented by Dr. Mütter.

1457.30-5- Right fibula. Fracture at the lower
1534 extremity; union.
40
4

Presented by Dr. Guy Hinsdale.

1457.31- Right fibula. Oblique fracture of
1535 the shaft. Union.
40
4

The plane of fracture passed from a point on the anterior angle 9.5cm. from the lower extremity downward and backward through 1.cm. of vertical extent. The upper fragment lies on the inner side with slight overlapping. The hollow on the inner side of the apex for the attachment of the transverse ligament of the ankle, is very deep and its edges prominent. The fracture has united well.

Presented by Dr. Mütter.

1457.32- Left fibula. Oblique fracture of the shaft. Union.

1536
40
4

The fracture occurred 5cm. from the lower extremity. The plane seems to have passed from the posterior surface downwards and forwards. The fracture is well united and the contour of the bone is excellent.

Presented by Dr. Mütter.

1457.33- Bones of left leg and foot. Oblique fracture of external malleolus. Union.

1537
40
4

The lower end of the fibula seems to have been split vertically. A fissure extends from the ankle-joint 2cm. and lies between the small fragment comprising the external malleolus and the shaft. The minor fragment was about 6cm. long and is united at its upper portion to the shaft of the fibula. The fracture thus extending into the joint, the inflammatory process has altered the articular surface of the tibia, which presents a transverse ridge. Posterior to this ridge the articular cartilage has been eroded and a large sinus is seen leading into the cancellous tissue. Another sinus is seen at the inner end of the ridge. Anterior

to this ridge the spongy tissue is plainly seen. The tarsal bones are light and, over a large extent of surface, deprived of compact tissue.

Presented by Dr. Mutter.

1457.34- Lower ends of left tibia and fibula. Transverse fracture of the outer malleolus. Recent.

1638. 40 4

The fracture occurred in the fibula at a point from .5 to 1 cm. above the broad articular surface of the tibia. The lower half of the lower fragment has been sawn off. The whole specimen is 16cm. long.

1457.35 Fibula; – fracture of the shaft united. Purchased. Presented by Dr. John H. Brinton.

1457.36 Fibula; – fracture; – united. Presented by Dr. John H. Brinton.

1461

1462- Lower third of right fibula. caries.

The inner aspect of the bone near the ankle-joint is excavated irregularly. caries has destroyed the bone about the depression for the lateral ligament. The spongy tissue is eroded. The anterior angle is sharp. vertical striations are seen near the upper end of the fragment. In this region the compact tissue is rough and porous. In the interior a loose spongy tissue is seen.

FIBULA

Presented by Dr. Ritter.

TARSUS

METATARSUS

1463- Upper two-thirds of right fibula.

Necrosis.

1462-1494.

This is a remarkable specimen. The sequestrum, which has been removed, is 20cm. long and is in no place more than 1cm. in diameter. It is irregular in contour and represents about one-half of the thickness of the original bone. Its surface is rough.

A perfect involucrum has been formed. Its greatest circumference is 10½ cm. Its inner and posterior surface is intact though marked by deep channels for blood-vessels. The external surface is open through an extent of 16cm. in which bed the sequestrum lay. There is no smooth surface either or within the involucrum.

Presented.

1462- Lower third of right fibula. caries.

1521 The inner aspect of the bone near the ankle-joint is excavated irregularly. caries has destroyed the bone about the depression for the lateral ligament. The spongy tissue is eroded. The anterior angle is sharp. vertical striations are seen near the upper end of the fragment. In this region the compact tissue is rough and porous. In the interior a loose spongy tissue is seen.

Presented by Dr.Mütter.

1463- Upper two-thirds of right fibula. Necrosis.

1520 This is a remarkable specimen. The sequestrum, which has been removed, is 20cm. long and is in no place more than 1cm. in diameter. It is irregular in contour and represents about one-half of the thickness of the original bone. Its surface is rough.

A perfect involucrum has been formed. Its greatest circumference is 105 cm. Itsinner and posterior surface is intact though marked by deep channels for blood-vessels. The external surface is open through an extent of 16cm. in which bed the sequestrum lay. There is no smooth surface without or within the involucrum.

Presented.

1464- Right fibula. Periostitis. Hypertrophy with exostoses.

The fibularis increased in thickness chiefly by deposit over its anterior and inner surfaces. The lower portion of the inner surface is marked by a growth of osteophytes. Fine longitudinal striations are seen in the anterior angle below the head.

Presented by Dr.Mütter.

1464.05- Right fibula. Rarifying ostitis.

This is probably syphilitic. The disease occupies the middle of the shaft. The surface is rough, vascular and shows no traces of compact tissue over the thickened area. Below the neck there are longitudinal striations.

Presented by Dr.Mütter.

1464.10- Left fibula. Rarifying ostitis.

The entire bone below the upper fourth is thickened, rough and presents no compact tissue. At the middle of the external angle a groove for a blood-vessel is quite prominent.

Presented by Dr.Mütter.

1464.15
&~~1458~~
1516
37 ~~36~~
5

Right fibula. Periostitis;hypertrophy;exostoses.

The bone has been divided below the neck and is 33.5cm.long. It is thickened and exceedingly rough. Its angle bristle with exostoses. These are chiefly seen on the inner surface and near the lower end. At the middle of its outer angle is a deep vascular channel. The outer surface is, at its lower part marked by grooves running transversely. The surface of the bone in this region is porous and finely vascular.

Presented by Dr.Mütter.

1464.20
&~~1458~~
1515
~~36~~ 37
5

Right fibula. Hypertrophic ostitis.

This bone is enlarged throughout the lower two thirds of the shaft;at the junction of the upper and lower third it has a circumference of 8cm. There are no osteophytes. The bone is covered,however, with fine vascular openings,and,on the inner surface,fine vertical striations are seen.

Presented by Dr.Mütter.

1464.25
&~~1458~~
1514
~~36~~ 37
5

Right fibula. Hypertrophic ostitis.

The hypertrophy occupies the lower two-thirds of the bone. At the junction of the middle and lower third, the circumference is 7cm. The angles are prominent. Vascular grooves course transversely over the angles, particularly at the middle of the posterior angle and on all sides in the lower third.

Presented by Dr. Mütter.

1464.30-
1513
37 ~~36~~
5

Upper two-thirds of right fibula. Hypertrophic ostitis.

The shaft is enlarged, having a circumference of 7cm. Its surface is comparatively smooth, but is dotted with minute openings for blood-vessels. There are numerous large openings distributed along the shaft. These have a diameter of from .5 to 1.cm. One of them perforates the bone near the head, but does not lead to any cavity. Whatever cavities may have been connected with some of these openings, the reparative process has filled them up. Some of these sinuses communicate with each other. The sawn end of the specimen shows no medullary cavity.

Presented by Dr. Mütter.

1464.35- Fragments of a fibula. Osteophytes.

The fragments represent 19cm. of the shaft of a fibula which has been sawn vertically. The angles are prominent, owing to a series of spiculated osteophytes. The medullary cavity is open.
H.H.S.

Purchased.

1464.40
& ~~1458-~~ Fragment of the shaft of a fibula.

Hypertrophic ostitis.

The bone is enlarged, having a circumference of 8cm. The surface is rough and marked by sunken vascular channels coursing over the angles of the bone. The compact tissue is thin.

Presented by Dr. Mütter.

1467.05
& 1467.10- Hypertrophic ostitis. Syphilis.

The surface of the bone is rough and the angles have an irregular line. The right fibula at the junction of the middle and upper third has a diameter of 2.5 cm. The surface is marked by vascular channels coursing along the surface and dipping into the medullary cavity. There are numerous deep vertical fissures in the upper part of the bone.

Vertical section shows thickening of

the compact and cancellous tissue. The compact tissue has a variable thickness.

From the same individual as Fib. 29 and 30.
H.H.S.

Purchased.

1470-H
1406
38
57

Talipes equino varus of the left foot.

The specimen embraces the lower ends of the tibia and fibula besides the bones of the foot. The tibia shows a lateral thickening of the inner malleolus. The astragalus is rotated with its head downward, the line of the head and neck passes in the same direction as that of the long axis of the tibia except that it points a little more anteriorly. The head of the astragalus is in contact with the scaphoid only at the outer side of its articular surface, and is situated immediately above the head of the calcaneum.

The calcaneum is elevated at the heel. Its head produces a prominence on the outer side owing to the depression of the cuboid and cuneiforms. Between the sustentaculum tali, the scaphoid and the innermalleolus there are the remains of an abscess cavity having a capacity of from

1470.50- Bones of the left foot, Flat-foot,
1407 from a negro,
38
5

The dorsum of the foot is but slightly arched, the surface of the cuboid being actually below the level of the cuneiforms. The astragalus, viewed relatively to other positions of the tarsus, is elevated; but its position in comparison with the same bone of a normal foot, is somewhat depressed. The plantar surface is characterized by an unusual prominence of the region giving origin to the calcaneo-scaphoid ligament, of the inferior surfaces of the astragalus, scaphoid and internal cuneiform bones. The inner border is straight to a point opposite the posterior border of the internal cuneiform but beyond this it is thrown in a conspicuous prominence formed conjointly by the scaphoid bone and head of the astragalus. (See figure, in which it may be remarked that the first metatarsus and first phalanx of the great toe are represented as disproportionately large.)

See Pathological Society Proceedings, Vol. III, p. 34.

The apparent cause of the defromity is in the head and neck of the astragalus. The head is pushed downwards and the neck is almost obliterated--the latter measuring but 4mm. upon its inner edge. The lower half of the articular surface, with the scaphoid line, was exposed upon the plantar aspect and separated from the upper half by a shallow groove. The latter portion is articulated with the lower half of the scaphoid bone, while the remainder had formed a new irregular opposing surface to the scaphoid at the expense of the inner portion of the head and neck of the astragalus. The contour of the scaphoid bone is altered at the points of contact with the abnormal surface above mentioned, while its facettes for the cuneiform bones are unusually well defined. The internal cuneiform with the exception of the inner surface being more concave than usual, is not changed. The calcaneum is somewhat inflated upon its inner surface and irregularly grooved upon its outer where, at its articulation with the cuboid, two minute exostoses points are seen. The inferior extremities of both tibia and fibula were hypertrophied and showed evidences of periosteal excitation. This was

1472-1408 38 5

1485

especially conspicuous upon the external malleolus and extended thence along the borders of the interosseous space. The right foot was normal.

Dissecting room specimen.

Reported to the Phila. Pathological Society March 27th, 1867, and presented to the Museum by

Dr. Harrison Allen.

1471-
1408
38
5

Bones of the right foot. Luxation of the astragalus outwards.

The specmen was removed below the middle of the leg. The relations of the tibia, fibula and astragalus to each other are not altered. The astragalus has been forced from its bed and lies on the outer sides of the tarsus. Its neck, instead of resting against the scaphoid, points upward and outward and is situated immediately over the cuboid and external cuneiform. The neck and the outer half of the base of the bone thus forms a marked prominence on the outer side. The tendon of the tibialis anticus muscle passes along the inner side of the neckof the astragalus.

The internal lateral ligament is intact. The external lat ral ligament has been dissected and shows the anterior fasciculus undisturbed. The middle, and to a less extent, the posterior fasciculi were subjected to violence. The foot turns abruptly to the inner side, the great toe being high above the others.

Purchased.

1471.05- Tar.3. Portion of right tibia and fibula with tarsus and metatarsus. Luxation and caries of the astragalus and caries of the calcaneum.

The tibid, fibula and astragalus have preserved their relation to each other. The head of the astragalus has left the scaphoid and, having been forced to the outer side 90°, lies immediately over the posterior edge of the cuboid. The spongy tissue appears over the entire head and nack. The posterior surface of the lower end of the fibula is also bare of compact tissue.

The calcaneum has been rotated on its long axis nearly 90° and the heel raised. The sustentaculum tali is the lowest portion of the bone and rests upon the ground. The articular surface formerly in apposi-

tion with the astragalus, now lies against the scaphoid and the opposing surfaces have undergone arthritic change. The heel is elevated. The external and subcutaneous aspect of the calcaneum has suffered great inroads, whether from disease or from the original violence it is difficult to say. A large part of the anterior and external surfaces are lost; the articular surface for the cuboid bone is exposed and exhibits spongy tissue.

The fibula abuts against the external tubercle on the inferior surface of the calcaneum. The entire foot has been carried 90° to the inner side and probably remained a considerable time in that position.

Presented.

I472- Left tarsus. Fracture of the neck of
~~1310~~ 1410. the astragalus. Recent.
38
5'

The bones are from a small foot. The anterior fragment involves the entire head and neck, and the entire anterior facette of the inferior surface. The fracture follows the line of the insertion of the interosseous ligament inferiorly, skirts the anterior edge of the superior articular surface and passes close to the facette for the fibula.
H.H.S.

Purchased.

I472.05- Right tarsus and portion of tibia
~~1311~~ 1411 and fibula. Fracture of the neck of
38 the astragalus, the scaphoid and cal-
5' caneum.

The bones were crushed by direct violence and the specimen was probably obtained after amputation at the lower third of the leg. The neck of the astragslus was fractured transversely and the fragment carried to the inner side where it is retained by its ligamentous attachment to the inner malleolus. The lower border of the scaphoid bone was broken away. The calcaneum was crushed into a number of fragments. The entire tarsus points abruptly to the inner side.
H.H.S.

Purchased.

1472 12/13 Missing

Portion of tarsus.
Tarsectomy.
Presented by Dr John B Roberts.

1491

1472.10- Lower ends of tibia and fibula and tarsus. Fracture of the astragalus. Dislocation of the fragments. Anchylosis.

~~1412~~ 1412.
38
3

The astragalus was fractured probably transversely through the body. The fractured end of the anterior fragment is tilted toward the fibula to which it is anchylosed. The head and neck are atrophied and united with the scaphoid. The posterior fragment is atrophoid. Vertical section shows continuous spongy tissue from the shaft of the tibia to the bottom of the heel. This stretch of spongy tissue is narrow at the fibular side of the ankle-joint and at the inner side of the calcaneo-astragaloid articulation. Viewing the specimen anteriorly, there is a space nearly 2cm broad between the inner malleolus and the astragalus, at the bottom of which is seen the posterior fragment between which and the astragalus there is a channel passing transversely and emerging in front of the external malleolus. The anterior fragment of the astragalus being dislocated to the outer side presents a marked deformity in front of the outer malleolus.

H.H.S.

Purchased.

I472.I5- Lower end of right tibia and fibula
~~1413~~ 1413.
38
5
and tarsus. Comminuted fracture of the calcaneum and outer malleolus.

The neck and body of the calcaneum are crushed. A small fragment has also been broken off from the outer malleolus. The under and anterior surface of the calcaneum have suffered most. The calcaneo-cuboid ligament holds some of the fragments in position. The sustentaculum tali and the groove for the flexior longus pollicis, are found in the anterior fragment. The ligaments of the ankle-joint are intact excepting the middle fasciculus of the external lateral ligament.

Presented by Dr.Mütter.

I474- Right astragalus and calcaneum.Atrophy.
~~1414~~
1414
38
5

The heel is atrophied and irregular.
The astragalus is everted.

Purchased.

I477- Left calcaneum. Caries.
1415
38
5

The disease has destroyed the neck of the bone. The sustentaculum tali is left ,but presents no compact tissue. This may be said of the bone generally and is doubtless owing largely to lack of care before mounting.

Presented by Dr. Mütter.

1495

✓ ✓ missing

I477.10- Right astragalus. Caries.

1416
38
5

The bone is light. Only a portion of the neck of the bone and the depresion for the interosseous ligament show any compact tissue. The head and neck are dwarfed. Posteriorly the bone is marked by osteophytes. The under surface of the neck is excavated by caries.

Presented by Dr. Mütter.

✓ ✗

✓ I477.20- Portion of left calcaneum. Caries.

1417
38
5

There remains only a shell, constituting the outer aspect of the bone. The spongy substance shows signs of disease. Above it is rough; below there is evidence of an attempt to cover the exposed spongy tissue with compact substance.

Presented by Dr. Mütter.

✓ ✗

✓ I477.35- Lower end of right tibia and fibula.

1418 ~~1418~~
39
5

Caries of astragalus and calcaneum. The astragalus is very slightly involved; the disease is situated on the outer side of the neck. The calcaneum on the other hand is almost wholly destroyed. A few remaining fragments are seen about the cuboid and the head of the astragalus. The largest fragment embraces the sustentaculum tali, and the inner surface of the bone.

The other bones of the tarsus are not involved. No evidence of repair are seen at the seat of disease.

Presented.

I477.40- Right tarsus and metatarsus. Caries of the scaphoid, cuneiforms and first and second metatarsals.

1420
39
5

The disease is situated on the inferior surface. The scaphoid and cuneiforms are deeply involved, but present an intact superior surface. The first metatarsal is eroded near the under surface of each extremity. Lines of fracture, probably accidental, are seen in the scaphoid, internal cuneiform and first metatarsal.

Presented.

I477.50- Lower ends of the left tibia and fibula, and bones of the foot. Caries of tarsus and metatarsus.

1421
39
5

The disease is situated chiefly on the inner side of the foot. The ankle- joint, astragalus and calcaneum are intact. The inner and anterior portions of the scaphoid are destroyed. The internal cuneiform has disappeared; the remaining cuneiforms and scaphoid are bare of compact tissue upon their surfaces.

The base and proximal portion of the shaft of the first metatarsal have been destroyed.

Presented by Dr.Mütter.

I477.60- Lower ends of left tibia and fibula and bones of the foot. Caries and ostitis of the entire foot.

1422
39
5

Thetibia and fibula show their proximity to inflamed tissue by roughness at the lower extremity. The astragalus has coossified withthe scaphoid and calcaneum, but allows of some motion at the ankle, although the articular surface is partially destroyed. The head and neck are merged in the scaphoid and are unrecognizable. The surface is rough and posteriorly is marked by osteophytes. The calcaneum is a good example of ostitis;it is light,porous and vascular. The cuneiforms are coossified with each other and the first metatarsal, and are deeply excavated on the under surface. The cuboid is not present. The first and second metatarsals are coosified at both extremities. The second is small and porous. The third is very much reduced in size and has a thickness of about I.5 mm; being flattened out between the second and the fourth. The latter bone is likewise much reduced in size,the base of the bone having dis-

appeared. The fifth metatarsal has preserved nearly its original shape. The phalanges are generally eroded at their extremities. There is thus left a gap in the arch of the foot 2by 3 cm, in extent.

Presented by Dr, Mütter.

1477.70 1423 39 5 Left tarsus and metatarsus. Caries

The lateral surfaces of the astragalus, the superior, posterior and outer surfaces of the calcaneum, the superior and inferior surfaces of the remainder of the tarsus, and the extremities of the metatarsals are involved. The fifth metatarsal has lost both extremities. The internal cuneiform has been excavated on the inferior surface.

Presented.

Vol. 1- Pg. 1509

1479.40 ~~1477.75~~ 1424 39 5 Tarsus and metatarsus. Anchylosis; Atrophy.

The tarso-metatarsal joint is anchylosed and only pointed stumps are left of the three outer metatarsal bones.

Presented by Dr. Mütter

I477.80- Caries of tarsus.

1425
39
5

The specimen consists of all bones of the left leg and foot below the tubercle of the tibia. The tarsus has undergone serious changes, consequnt on a rail-road injury. Both malleoli have suffered whether by fracture or caries it is difficult to say. The tarsus was extensively invaded. The arch of the foot is absolutely lost. The anterior portion of the calcaneum is in a plane with the heel and toes. The tibia rests on the neck of the astragalus and is separated by 5 cm, from the scaphoid. The calcaneum projects prominently behind. It is a case of consecutive dislocation. The last phalanx of the great toe is missing, the first phalanx has a sharp termination.

Purchased.

I479.- Left astragalus and calcaneum. Anchylosis.

1426
39
5

The joint between the bones has been obliterated. No trace of it can be seen in the posterior portion, even on vertical section. The spongy tissue is continous from one bone to the other. The under surface of the head and neck is not involved.

1505

There is some callus at the postarior edge of the astragalus.

N.N.S.

Purchased.

I479.IO- Left astragalus and calcaneum. Anchylosis.

1418
38
5

The bones are large, and are coössified throughout their posterior articular surfaces. No evidences of arthritis are seen about the head and neck. The head however is small, and projects but very slightly in front of the calcaneocuboid articulation. The articular surface, near the sustentaculum tali has been worn away previous to mounting. The heel is short The outer and posterior surface of th . heel has been worn away previous to mounting. The surface for the insertion of the tendo Achillis terminates in a point at the center. Half way between this point and the Sustentaculum tali, there is an exostosis, about a centimeter in length.

1129.48 and 1138.866.

Copied by mistake

Presented by Dr. Mütter.

I479.20- Right astragalus and calcaneum.

1427
39
5

Arthritis.

The head and neck of the astragalus are atrophied.

The articular surface is irregular; its border and neck are marked by arthritic deposit, especially superiorly where an osteophyte is seen pointing direcly upwards. The calcaneo-astragaloid articulation is unimpaired in its posterior facette; but anteriorly the surface is small owing to the same changes which resulted in atrophy of the head and neck of the astragalus. The calcaneum is thus deformed anteriorly. Its articulating surface for the cuboid is small. It is marked by a slight transverse elevation dividing the surface into about equal portions.

Presented by Dr. Mütter.

Mpsary

I479.30-V Lower end of left tibia, tarsus and metatarsus. Arthritis.

The border of every articular surface in the specimen is marked by arthritic deposit. The groove for the tendon of the flexor longus pollicis is thereby deepened; this is owing to profuse fungoid deposit at the posterior end of the astragalus. There is a well marked groove in the tibia for the tendons of the tibialis posticus, and the flexor longus digitorum. The cuboid is particularly deformed; the absence of the fourth and fifth metatarsals reveals a coössification of the internal cuneiform

and third metatarsal. There was practically no motion at the ankle-joint, and the foot was doubtless rigid.
H.H.S.

1479.40 see vol I page 1501. Purchased.

IX

I484. Stump after a tarso-metatarsal amputation of the right foot.

1428
39
J

The specimen embraces the lower end of the tibia and fibula, and the tarsus. The ankle-joint is intact likewise the articulation of the astragalus and calcaneum with the scaphoid and cuboid. The latter bones are anchylosed with each other. Lying between them anteriorly the external cuneiform is seen much reduced in size. The other cuneiform bones are not seen. The whole anterior border of the bones in the specimen is smooth and rounded and presents the indurated surface usually seen at the extremity of stumps of long standing. The cuboid has lost the angle which is normally presented between the internal cuneiform, and the bases of the fourth and fifth metatarsals. The calcaneum is very much altered posteriorly; being worn on the outer side, leaving a sharp vertical ridge on the inner side of the tendon of the muscles of the calf.

A few exostoses are seen on the inner surface near the posterior ridge.

Presented by Dr.Mütter.

IX

I487. Left tarsus and metatarsus.Fracture of the third,fourth and fifth metatarsals. Union with deformity and caries.

1539
40
5

The metatarsals were fractured at their middle,and have united with outward displacement of the distal fragments.The proximal fragments of the secondand third metatarsals have united at the seat of fracture. Between the cuboid and the fourth and fifth metatarsals there is a carious excavation. The distal fragment of the fifth metatarsal has atrophied to a small piece about I cm,long.

Presented.

IX

I487.IO- First metatarsal of left side.Oblique fracture. Union.

1540
41
5

The fracture occured obliquely in the middle of the shaft. Union has occurred with slight overlapping of the distal fragment on the proximal,causing a prominence on the subcutaneous surface. The head of the bone is irregular,has no smooth surface and is marked by numerous vascular

openings. The line of union is well seen on the under surface.

Presented by Dr.Mütter.

1489. Right tarsus and metatarsus. Anchylosis.

1541 Atrophy of the metatarsus.

41

5

The astragalus calcaneum and scaphoid are normal. The middle and internal cuneiforms are coossified with the remains of the second and third metatarsals. There is no fourth metatarsal and no place for it. The fifth metatarsal articulates with the cuboid, and occupies the entire space for metatarsal articulation. The internal cuneiform dips down between the bases of the first and second metatarsals, projecting I.5 cm. beyond the base of the second metatarsal. The articulation of the cuboid and fifth metatarsal is marked by pouting exostoses. The first metatarsal bone is 2.5 cm. long. This includes a flat piece articulating at the distal end. The second and third metatarsals are 3 cm, long, and dwindle to a point. There atrophy resembles the atrophy of bones in ununited fracture. The remaining metatarsal bone is strong and of its normal length. At its distal end there is an exostosis pointing upward.

Presented by Dr.Mütter.

I492.- First metatarsal of left side. Caries. The extremities of the bone are involved. Near the proximal end the compact tissue is absent and the spongy tissue is visible. The head is gone.

I492.05- Caries of the tarsus and metatarsus.

1542
41
3

Dr.A.S.Roberts.

I492.10- Third metatarsal, right side. Caries of base.

1543
41
3

At the base there is a carious cavity opening on the articular surface for the second metatarsal.

Presented by Dr.Mütter.

I492.20- First phalanx of great toe. Caries of base. Periostitis.

1544
41
3

Presented by Dr.Mütter.

I494.- Left scaphoid, cuboid and cuneiforms with the metatarsus. Arthritis.

1546
41
4

The intertarsal and tarso-metatarsal articulations are fringed with arthritic deposit. The head of the first metatarsal is also heavily fringed with callus.
H.H.S.

Purchased.

I494.10- Left tarsus and metatarsus. Synostosis
1548 of the first and second metatarsals.
40
5 The first and second metatarsals are united for the space of Icm, near their bases, in which situation inter-metatarsal articular sirfaces are prolonged.

Presented.

I494.20- Left scaphoid, cuboid and cuneiforms.
1549 Arthritis.
40
5 All the articular surfaces are fringed with arthritic deposit.

Purchased.

I494.30- Right cuneiforms, second metatarsal
1550 bone, and its phalanges. Anchylosis.
40
5 The three cuneiforms are co-ossified, and with them the second metatarsal. The phalangeal articulations are normal. Viewed posteriorly the cuneiforms can not be distinguished as individuals. The posterior surfaces form one large irregular, rough articular cavity for the scaphoid. The depth of this cavity is I.5 cm; its surface is marked by irregular depressions which on the inner surface almost perforate the bone and in the middle penetrate it . The margins are very rough and prominent.

The anterior facettes for the first and third metatarsals are seen to be in fair condition. The second metatarsal is firmly anchylosed inits socket between the cuneiforms. Its junction with the middle cuneiform is marked by a transverse ridge.

Presented by Dr.Mütter.

I494.40- First metatarsal of right side. Ostitis.
1551
40
5
The distal half of the bone has been involved. It is enlarged, rarefied and porous. The head has been lost. Periosteal deposit on the surface next the second metatarsal.

Presented by Dr.Mütter.

I494.50- Shaft of first metatarsal of left side. Rarefaction.
1552
40
5
The spongy tissue is very light and the compact tissue thin.

Presented by Dr.Mütter.

I494.60- Third metatarsal of right side. Exostosis.
1553
40
5
The exostosis on the under surface near the base, and points downward, forward and to the inner side. It is about I cm, long.

Presented by Dr.Mütter.

I494.70- Third metatarsal of right side.
1554
40
5 Rarifaction.

I494.80- A metatarsal bone. Rarifaction.
1555
40
5 These specimens have lost there extremities. Them shafts are normal externally. The spongy tissue is light and the compact layer very thin.

Presented by Dr.Mütter.

I494.85- Second metatarsal of right side.
~~1555~~
1547 41
3 Exostosis.

The exostosis, sessile about 3 mm, long, is situated on the under surface near the head. The bone may have been fractured at this point. The thickening of the shaft would suggest it, but it is not certain.

Presented by Dr.Mütter.

Museum

I494.90- Third and fourth right metatarsals
1556
40
3 and phalanges. Anchyloses and deformity.

The bones are anchylosed with there respective phalanges, and there is also anchylosis at two interphalangeal articulations. The fifth metatarsal curves over the fourth, and is atrophied.
H.H.S.

Purchased.

1523

J O I N T S.

1546

to

1728

1525

I546. Right scapula and humerus. Old sub-coracoid luxation of the humerus.

774
82 24
86 3

The head of the humerus lies under the coracoid process, and is in contact with it and the subscapular border of the glenoid cavity and the under surface of the neck. A new articulation is thus formed; it is rough except on the under surface of the coracoid process. The head of the humerus is rough and has no lateral direction in reference to the shaft. The surgical and anatomical neck are identical. The old glenoid cavity, is rough and marked at the margins by exostoses. The acromial process is similarly marked. From same individual as scap; I6.

Presented.

I546.05- Right scapula and humerus. Old sub-coracoid luxation.

775
82 24
86 3

A new articular surface has been found on the sub-scapular side of the neck, below the coracoid process. It is rough and slightly concave. The old glenoid cavity is rough and atrophied. The head of the humerus is distorted, but presents an anatomical neck. The groove for the long tendon of the biceps is deep.

The arm was elevated, its motion impaired, and the condyles were in a vertical line.
H.H.S.

Purchased.

I546.10- Right scapula and humerus. Sub-coracoid luxation.

776
Se 94
86 3

The new articular cavity of the scapula is 3 cm, broad and 5 cm, long, and is situated immediately below the coracoid process. Both the old and new cavities are rough. The head of the humerus is of globular shape but rough.
H.H.S.

Purchased.

I552- Shoulder joint; caries.

777
Se 24
86 4

Presented by Dr. A.S. Roberts.

I553- Scap, 22; Right scapula and humerus, and outer portion of the clavicle. Necrosis with absorption of the head of the humerus. Periostitis.

778
Se 94
8 4

The coracoid process is adherent to the under surface of the clavicle. The former appears as a prolonged boundary of the glenoid cavity. This cavity is rough and the bone of it is friable having undergone extensive absorption.

Its outer edge is formed by a prominent ridge of callus. The outer surface of the acromion is necrosed. The head of the humerus has disappeared inthe process of necrosis. The shaft and tuberosities remain. The upper third was involved in periostitis. From a young man, a workman in a factory, who received a blow on the shoulder from a revolving beam. There appeared to be no fracture, but the soft parts were severely contused. The inflamation was followed by suppuration, and death from exhaustion ten (IO) months later.
W.S.F.

Purchased.

I554 779 Sr 24 86 Left scapula and humerus. Arthritis of the shoulder-joint.

The articular surfaces are rough excepting at the point of contact of the humerus and acromion, where there is eburnation. The borders are fringed with callus. The humerus was rotated outward. From same individual as scap, I5.

I554.02- 768 Sr 24 86 Right scapula and clavicle. Exostosis.

The acromion and coracoid process and the extremities of the clavicle are rough and present numerous warty exostoses.

The sternal end of the clavicle is flat in the vertical line. The coracoid process is pointed. The coracoid process is in contact with the under sudface of the clavicle,and at this situation there are outgrowths of callus. There is ossification of the transverse ligament.

Presented by Dr.Mütter.

I554.05- Right scapula and humerus. Arthritis. The shoulder joint was rough and its motion impaired by the deposit of callus. This fringes the glenoid cavity and hangs in heavy masses from the head of the humerus. The center of the articular surface of the humerusis convex, but towards the margin becomes concave.

Presented by Dr.Mütter.

I554.10- Portions of right scapula and humerus. Arthritis. Eburnation. The glenoid cavity is slightly fringed with callus,and a large extent of its surface,eburnated. The head of the humerus presents an eburnationof larger extent, and is more heavily fringed with callus. The coraco-acromial,and a portion of the capsular ligament remain.
H.H.S.

Purchased.

I554.15- Right scapula and humerus. Arthritis. The glenoid cavity is greatly altered. It is traversed at the middle by a deep fissure which passes laterally downward, surrounding the lower portion of its neck. The articular surfaces are rough and marked by small openings. The head of the humerus is marked by deep ridges and grooves.

Presented by Dr.Mütter.

I554.20- Left scapula and humerus. Anchylosis. The shoulder-joint is anchylosed; there is a strong bridge of callus 2 cm, thick connecting the coracoid process, and lesser tuberosity. This callus is smooth. The bicipital groove is deep. The transverse ligament has been preserved, but the acromion has been accidentally broken. From a sailor who fell from the rigging at sea. No fracture could be discovered at that time. From the use of his arm and inflammation after the accident, anchylosis occured. He died two years later of intestinal trouble.
W.S.F.

Purchased.

I561.4 Left humerus, ulna and radius. Old internal lateral luxation of both bones of the forearm. Anchylosis.

1569. Elbow joint — portion of humerus, radius and ulna - Anchylosis
Presented by Dr. John H. Brinton

The radius and ulna are displaced to the inner side. The olecranon is on the outer-side of the line of the internal condyle; the radius is immediately beneath the olecranon fossa. The anterior portion of the articular surface of the humerus is protected by a broad plate of callus; the olecranon and internal condyle are also united by callus. The forearm is flexed at an angle of 110°, and the bones are fixed half way between pronation and sup-ination.

1562.
1562.05 – see Vol I p. 1537

Presented by Dr. Mütter.

1569.05 Elbow joint; – humerus, radius & ulna; – Anchylosis.
Presented by Dr. John H. Brinton.

1569.10 Elbow joint; – humerus & ulna; – Anchylosis.
Presented by Dr. John H. Brinton.

1562 IX Elbow joint; - portion of humerus, radius + ulna - Fracture of the joint and also the lower end of the radius - ununited
Presented by Dr. John H. Brinton

1562.05 Elbow joint; - portion of humerus, radius and ulna and shell; Gunshot fracture; ununited
Presented by Dr. John H. Brinton

1539

1574- Missing

Concretions from the elbow-joint

About 250 small bodies like wheat in size, of irregular shape.

Presented by Dr.Mütter.

I584. Bones of the left upper extremity. Anchylosis of the wrist-joint and carpus.

The bones of the arm and forearm are normal excepting at the wrist. The ulna articulates well with the radius, but the radio-carpal joint is obliterated. Except the pisiform all the bones of the carpus are co-ossified with each other; the second and third metacarpals are also anchylosed at the base. The groove for the extensor communisdigitorum is broad and well marked. The fusion ofthe bones of the carpus, has allowed the radius and the bases of the metacarpal bones to approach within I cm. of each other. Posteriorly there is a depression over the carpus; anteriorly the carpus is prominent. The metacarpus has been fixed in slight extension.

Presented by Dr. Mütter.

I584. Ib- Bones of the left forearm, carpus and metacarpus, Anchylosis of the radius, carpus and metacarpus.

The bones are slight. The head of the ulna is deformed by arthritis and deviates to the inner side; it presents a great lateral diameter and is rough. The radius is ossified with the carpus; the bones of the latter are fused together in an indisting-

uishable mass, and presents at the base of the fourth metacarpal bone a vacancy having a diameter of I.5 cm. The first metacarpal was not involved; the remaining metacarpals are firmly anchylosed at their bases with the carpus and with each other. The fourth is I cm. shorter than the fifth, owing to absorption of the head; both bones are curved and are flexed. The heads were also involved in arthritis.

Presented by Dr. Mütter.

I584.20- Left radius, ulna, carpus and metacarpus.
787 Anchylosis.
8z 24
8b 6

The radius is anchylosed with the ulna at its lower extremity and is fixed midway between pronation and supination. The inner half of the articular surface of the radius is ossified with the carpus; the latter is composed of a fusion of all its bones, and is co-ossified with the second, third and fourth metacarpals. The bones are well developed. Dissecting room specimen.
W.S.F.

Purchased.

I584.30- Left ulna, radius, carpus and metacarpus.
788 Anchylosis.
8z 24
8b 6

The radius is anchylosed with the ulna at

its lower extremity and is fixed in almost complete pronation. Both bones are co-ossified with the carpus. The carpo-metacarpal joints were probably not wholly obliterated, but motion was slight owing to the callus at the margins. The metacarpus was flexed at nearly a right angle with the forearm. Small exostoses are seen over the position of the lunar bone and on the dorsal surface of the neck of the middle metacarpal. The pisiform and the process of the unciform are prominent. The trapezium is completely dislodged, probably as a consecutive dislocation and lies on the palmar side. Dissecting room specimen.
W.S.F.

Purchased.

1584.35- Right radius, carpus and second and third metacarpals. Anchylosis.

789
82 24
86

The bones enumerated are anchylosed in one. No traces of the intervening joints remain. Among the indistinguishable mass of bones of the carpus, the prominent process of the unciform bone may be seen. On the dorsal surface the carpus retreats, and is prominent anteriorly. The metacarpals are fixed in a line with the radius.
H.H.S.

Purchased.

Missing

1609.00 Bones of the right foot, tibia and fibula. Arthritis of the knee-joint

Presented by Dr. John H. Brinton

1629-
1339
37
6

Sacrum and left innominate anchylosis. The two bones are co-ossified at the superior part of there junction. Both bones are large. A small exostosis is seen at the symphysis pubis.

Presented by Dr. M"tter.

1636- Right innominate. Luxation of the femur. (Wooden model)
1338
37
6

The femur was dislocated backwards and downwards. A new acetabulum formed, guarded by a strong hook-like process on the outer side, well worn and curved in its contact with the femoral head. The original acetabulum is atrophied.

Presented by Dr. Mütter.

1636.05- Right innominate. Upward luxation of the femur. (Wooden model)
1337
37
6

The head of the femur rested under Poupart's ligament. The new articular cavity is broad and shallow.

Presented by Dr? Mütter.

1636.10- Left innominate and upper half of the femur. Luxation backward.
1336
37
6

The femur is displaced backward; the acetabulum is filled with osseous deposit; the new articular surface lies to the outer side, is nearly flat, quite smooth, and presents an elevated border. The femoral head is extremely flat in a vertical line, and occupies a low position; it is 2 cm. distant from the lesser trochanter, which is also flattened, and which takes part in the articulation.

Presented by Dr. Mütter.

1636.20- Left innominate and upper third of the femur. Luxation on the dorsum of the ilium.

1335
37
4

The old acetabulum is atrophied and of sufficient size only to accommodate the thumb. The head of the femur rests on the dorsum of the ilium in which it has made a large, smooth and regular depression; internal surface shows a corresponding convexity of smooth and regular contour. The femoral head is atrophied, infact has practically disappeared.

Purchased.

1636.25- Left innomminate and upper third of the femur. Luxation.

1334
37
6

The head of the femur rests on the outer margin of the acetabulum. The latter cavity is slightly atrophied, while the portion of the ilium on which the femur rests is dense and strong. The head of the femur is slightly roughened.

H.H.S.

Purchased.

I636.30- Pelvis and upper extremity of femurs.
1021
32
2

Luxation of the right femur on the dorsum of the ilium.

The old acetabulum is narrowed and atrophied. A new cavity with elevated margins and strong walls is situated immediately above and behind the old, and receives and gives support to the head of the femur. The femoral head is flattened and somewhat fringed with callus. The pelvis is slightly distorted from depression of the right side. The ligaments have been preserved. Flat oblique pelvis. See pelvic measurments. #I365.I3-
H.H.S.

Purchased.

I636.35- Left innominate and upper third of
1333
37
6

the femur. Luxation and anchylosis in transverse position.

The head of the femur rests on the outer side acetabulum, to which it is firmly ossified. Secondary inflammatory processes have softened the bone and made great inroads in the acetabulum. The femur points transversely across the pelvis and is within 4 cm. of the symphysis.

Purchased.

1555

I636.40- Portion of the pelvis and left femur.

1332 Luxation.

37

6

The femur rests on the dorsum of the ilium where a rough socket has been formed by the deposit of bone. The head of the femur has been absorbed, and only a small portion of the neck remains encrusted with callus, which is prolonged along the line aspera.
W.S.F.

Purchased.

I636.50- Pelvis, upper half of left femur; fourth and fifth lumbar vertebrae. Luxation of femur on the dorsum ilii. False joint.

1331

27

The pelvis is slightly deformed. The antero-posterior diameter of the superior strait is 58 mm. (3.5 in.) The transverse diameter 137 mm. (5.3/8 in). The vertebrae deviate markedly to the left, in compensation for the shortening due to the luxation. The femur has left the old acetabulum, which from lack of use has contracted and is encroached upon largely by ossific deposit proveked by the trochanter minor which rubs against its lower margin. The new socket is immediately above and behind the old one, and is well formed by being excavated at the centre, and built up at the margins, and is dotted all over by minute openings leading within.

The head of the femur is much flattened, compressed, and the epiphysial line thickened. The neck has not undergone any great change. The trochanter minor is in the shape of a button, supported on a pedicle and worn by attrition with the pelvis. The general direction of the femur is nearly parallel with Poupart's ligament. The trochanter major is 70 mm. (2.75 in) from the crest of the ilium and 65 mm. (2.5 in.) from the anterior ~~supinous~~ spinous process. For pelvic measurements, see I365.I2. See Trans. Amer. Med. Ass'n-I878. Dr. H.H. Smith. Plate 5. Figure 4.

Purchased.

I636.60- Right innominate. Old luxation.
~~1329~~ 1330
37
6

The true acetabulum is nearly obliterated. An upward dislocation of the femur has been followed by the formation of a new socket, consisting of a new lip of bone rising from the ilio-pectineal line. The surfaces of this and of the old acetabulum are rough, and probably permitted little or no motion of the joint.

Presented by Dr. Mütter.

I636.70- Left innominate and upper third of
1329 the femur. Backward luxation.
37
6

The femoral head occupies a position immediately behind its former location. The old acetabulum is small and its cavity encroached upon. The new articular surface is rude, very slightly concave, and at its upper portion, is eburnated. The femoral head is somewhat flattened, is thick above and thin below and eburnated.
H.H.S.

Purchased.

I642-05 Hip-joint. Caries.
1436
38
6

I642- Right innominate and superior third
1328 of femur. Caries.
36
6

The neck and head of the bone have been the seat of caries. The head has been detached from the neck and remains in the acetabulum.

Presented by Dr.Mütter.

I644- Right acetabulum and femoral head.
1327 Anchyloses and changes due to cox-
36 algia.
6

The bone is large. The head of the femur is broken off squarely and remains in the socket. Suppuration has been followed by openings in the bone above the ileo-pectineal line, and at the angle and ramus of the pubes. The latter is channeled and fenestrated. The obturator foramen is deformed.

Presented by Dr. Mütter.

I644.05- Adjacent portions of right innominate
1326 and femur. Coxalgia.
36
6

The articular surfaces are roughened and deprived of cancellated tissue. Osteophytes fringe the outer surface of the ilium about the acetabulum.
H.H.S.

Purchased.

I644.10- Left innominate and superior third
1325 of femur. Arthritis.
36
6

The articulating surfaces are irregular and, at the superior portion, eburnated.

The depression for the ligamentum teres is obliterated. Deposit of bone over-hangs the neck of the bone producing a marked resemblance to a mushroom.

Presented by Dr. Mütter.

1644.I2- Right innominate with upper third
1429 of femur. Arthritis.
35
6 The acetabulum is broad and shallow; its superior surface is eburnated, and the margins irregular and prominent. The femoral head presents greater changes and deformity. The head is directed downwards owing to the extensive arthritic deposit. The neck is greatly distorted and overgrown with osteophytes, leaving only a narrow fissure between their mass and the greater trochanter, while the lesser trochanter is almost in contact with the overhanging head. There is eburnation corresponding with that in the acetabulum.

Presented by Dr. Mütter.

1644.I4- Right innominate and upper third of
1430 femur. Arthritis.
38
6 The acetabulum is filled up and distorted by the arthritic deposit. It is broad and shallow and has low and smooth margins. The femoral head is flattened, acuminate below and has overhanging borders. No eburnation.

Presented by Dr. Mütter.

I644.I6- Right innominate and upper third of
1324 femur. Arthritis.
36
6 The acetabulum is broad, being extended upwards and backwards by osseous deposit. The cotyloid notch is large. The femoral head does not present a commensurate change. There is a slight increase in the vertical diameter of the neck; the articular surface is smooth.

Presented by Dr. Mütter.

I644.I8- Right innominate and upper third of
1323 femur. Arthritis.
36
6 The acetabulum is 7 cm. broad, is porous and by attrition the femur has practically perforated the bone. Exostoses are seen above the acetabulum and below the anterior inferior spine. The femoral head is small and deprived of articular cartilage and compact tissue. There is a large flat exostosis on the anterior surface of the ilium below the greater trochanter. The epiphyses of the crest of the ilium, and of the ischium are still ununited.

Presented by Dr. Mütter.

I644.20- Left innominate and upper third of
1431 femur. Arthritis.
38
6 The disease was far advanced. The acetabulum is broad, irregular and perforated; The superior and outer margin is marked by osteophytes. The femoral head has been entirely destroyed, or at any rate is not present. The neck partly remains and shows by attrition having been in contact with the acetabulum.
H.H.S.

Purchased.

I644.22- Right innominate and upper third of
1432 the femur. Arthritis.
38
6 The acetabulum is deep and has a diameter of only 5 cm. The margins are prominent but regular; the depression for the ligamentum teres is marked. The femoral head is of natural size but the compact tissue is worn away. The neck is encumbered by a large osteophyte on its anterior surface.

Presented by Dr. Mütter.

I644.24- Right innominate and upper third of
1433 the femur. Arthritis.
38
6 The acetabulum presents sharp margins and an eburnated surface. The head is worn, is flattened and depressed. The digital fossa is deep.

Presented by Dr. Mütter.

I644.26- Sacrum, right innominate and upper
1434 third of right femur. Arthritis.
38
6 The hip-joint has undergone great alter-
ation. The acetabulum is broad and shallow
and presents a ragged margin. The pubis is
irregular, being indented at the symphysis.
The femoral head is small, ragged, porous,
having lost a large portion of its substance
Exostoses are seen on the anterior surface
of the great trochanter. The sacro-iliac
symphysis, and the lumbo-sacral articulation
are ossified.

Presented by Dr. Mütter.

I644.28- Fragments of right innominate and
1435 femur. Advanced arthritis.
38
6 There is perforation of the acetabulum
and extensive softening of the bone by
the supperative process. The femur has
also undergone great change. The head is
small and deprived of compact tissue.
The great trochanter presents general
ostitis.

Presented by Dr. Mütter.

I644.30- Right innominate and upper extremity
1322 of the femur. Anchylosis.
36
6

The joint is completely obliterated, the femur being slightly flexed. From a case of long standing.

Presented by Dr. Mütter.

I644.32- Right innominate and upper extremity
1437 of the femur. Arthritis.
39
6 The acetabulum is enlarged and thickened. The head of the femur is also enlarged by osseous deposit at its junction with the neck. Superiorly the compact tissue is worn away disclosing the spongy portion.

Presented by Dr. Mütter.

I644.34- Right ilium and upper third of the
1438 femur. Arthritis.
39
6 The acetabulum is deep and has strong margins. Its cavity approaches very closely the pelvic cavity. The femoral head is roughened and is detached from the neck; it seems to be carious. The epiphyses of the innominate have all united.

Purchased.

I644.36- Right innominate and upper third of
1557 the femur. Arthritis.
41
6

The cavity of the acetabulum is deepened by the inflammatory deposit at the border. The femoral head is worn above, abundantly perforated, and from its under surface a mass of callus hangs which must have seriously impaired the motion of the joint.
H.H.S.

Purchased.

I644.38- Left innominate and upper extremity
1439mm of the femur. Arthritis.
39
6

The margin of the acetabulum has become ulcerated and a few osteophytes render the borders of the acetabulum rough. The articular cartilage of the acetabulum and femur has become eroded (chondro-necrosis). Arthritis has caused a new deposit of bone in the acetabulum filling it up and taking the place, to a large extent of the cotyloid cartilage. The femur is very much changed. The head bears no resemblance whatever to a ball. The neck has been depressed 90° from its original direction. It is now very short, the space between the head and shaft varying from I to 6 mm. The head rests upon the trochanter minor. The shaft of the femur therefore approaches the crest of the ilium, the great trochanter

being situated 2 cm. above the edge of the acetabulum. Openings on the surface of the head where the cartilage has become eroded have allowed the discharge of their softened contents; a process which was accompained by softening and breaking down of the cancellated tissue resulting in arthritis and deformity. See Trans. Amer. Med. Assn. 1878 Dr.H.H.Smith. Plate 5. Fig. 1

Purchased.

I644.40- .Left innominate and upper third of the thigh. Arthritis.

1440
39
6

The acetabulum is rough and irregular and its walls are thickened by inflammatory deposit. The cotyloid notch is converted into a groove by a bridge of callus. The femoral head is greatly deformed by the deposit of callus. The sides of the head and neck and the capsular ligament are invested with callus.
H.H.S.

Purchased.

I644.42- Left innominate and upper third of the femur. Osteophytes.

1558
41
6

The joint seems to be in a fair condition.

The anterior inferior spine and the greater trochanter are the seat of osteophytes of moderate size.

Presented by Dr.Mütter.

I644.43 Right innominate and upper third of
1559 femur. Arthritis.
41
6 The acetabulum is rough and deformed, and has elevated margins. The cancellated tissue of the upper portion is exposed, corresponding with attrition of the head of the femur. A belt of callus envelopes the head.

Presented by Dr.Mütter.

I644.44 Right innominate and upper third of
1441 the femur. Arthritis.
39
6 Elevation of the margins of the acetabulum has increased to a large extent its capacity. A fringe of callus hangs from the head of the femur.

Presented by Dr.Mütter.

I644.46 Left innominate and upper third of
1560 the femur. Arthritis.
41 Elevation of the margins of the acetabulum,
6 and attrition of the compact tissue of the articulation, characterize this specimen.

1579

I644.48-
1442
39
6

Right innominate and upper extremity of the femur. Arthritis.

Arthritis of the joint has been followed by osteophytes which surround the acetabulum and increase to a considerable extent the depth of the socket. Eburnation of the opposing surfaces has occured, the anterior surface of the head of the femur being beautifully polished and grooved. The anterior superior spinous process is also marked by osteophytes. The spherical head of the femur is flattened so that, it resembles a broad mushroom. Several deep openings lead to cavities in the cancellous tissue, while the induration caused in the reparative effort near the margin of the largest cavity, situated in the upper portion of the head, has developed an ivory-like structure that by friction against the corresponding surface of the acetabulum has been eburnated. The neck is somewhat atrophied and shortened and ossification near the insertion of the capsular ligament indicates the reparative efforts of nature. A vertical section shows a cavity, whose walls are indurated like the indurated lining of a pulmonary cavity;

its interior is sinuous but in its formation it has encroached upon the articular cartilage from below upward, discharging, finally, its contents into the joint. The cross-section of this cavity is 21 by 12 mm. The flattening of the head and shortening of the neck are well seen in the cross-section and the induration of the trabeculae. See Trans. Amer. Med. Ass'n. 1878 Dr. H. H. Smith. Plate 4 figures 2 and 3. Plate 5 figure 3.

Purchased.

1644.50- 1443 39 6

Left innominate with proximal extremity of the femur. Arthritis.

The specimens are from a child; the three portions of the innominate are still distinct. The acetabulum is flat and broad and its margins are illy defined. Two sequestra from the head of the femur are present and are of a dark color. The head and neck of the bone have disappeared leaving the shaft encrusted with inflammatory ossific deposit. From a case occurring in the Children's Hospital Philadelphia.

Presented by Dr. John Ashhurst Jr.

I644.52- Left innominate and upper third of
1561 the femur. Arthritis.
41
6 The acetabulum is thickened and provided with stout margins. The head of the femur is deformed and presents superiorly a deep notch below which is the articulating surface, extended by adventitious deposit downward much below the great trochanter, necesssrily greatly shortening the limb.
H.H.S.

Purchased.

I644.54- Left innominate and femur. Coxitis
1562 and anchylosis.
41
6 The disease was far advanced. The innominate is necrosed, and what remains exhibits the condition of osteoporosis. Channels of large size perforate the bone. The great trochanter is wholly and the head and neck partially destroyed. The femur is flexed, adducted, rotated inwards and anchylosed in that position. From a child.

Deposited

I644.56- Right innominate and upper third of
1444 the femur. Arthritis advanced.
39
6 The specimens are from an advanced case of hip-joint disease. The acetabulum presents a large perforation and its surface

is ragged and deprived of compact tissue. The head of the femur is atrophied and its cancellous tissue exposed.

Presented by Dr.Mütter.

I644.58- Left innominate and upper third of femur. Anchylosis.

The joint has been obliterated and the bones are co-ossified with extreme adduction and flexion of the thigh. The whole inner surface of the ilium especially near the crest shows caries and evidence of long standing inflammatory processes. From a female who had hip-joint disease in childhood and died of typhoid fever, age I9 years.

Presented by Dr. J.Ewing Mears.

I644.60- Pelvis and femurs; anchylosis.

1563
41
6

1587

KNEE- JOINT.

1651
to
1659/

1589

X.
1651.
1564
41
6

Luxation of knee-joint backward.

The luxation was old but had probably not existed for any great length of time. The specimen is from a well developed adult, and embraces the lower third of the right femur and upper half of the tibia and fibula, with the patella and its ligament. The leg was displaced backward, rotated outwards, and is flexed at an angle of 130°. The anterior half of the inner head of the tibia is in contact with the posterior articulating surface of the inner condyle of the femur. The outer head of the tibia is carried further backward, the posterior surface of the outer condyle of the femur having been in contact with the anterior portion of the head of the tibia. Both opposing surfaces are roughened and eroded, the tibia showing the greater degree of loss. The patella is displaced outwards and rests on the outer tuberosity of the femur. There is no anchylosis, but there is slight roughening of the contiguous surfaces. The articular cartilage of the joint surface exposed is present, but there apparently was none at the surface of contact.

Purchased.

1591

IX.

1651. Luxation of knee-joint backward.

1564
41
6

The luxation was old but had probably not existed for any great length of time. The specimen is from a well developed adult, and embraces the lower third of the right femur and upper half of the tibia and fibula, with the patella and its ligament. The leg was displaced backward, rotated outwards, and is flexed at an angle of 135°. The anterior half of the inner head of the tibia is in contact with the posterior articulating surface of the inner condyle of the femur. The outer head of the tibia is carried further backward, the posterior surface of the outer condyle of the femur having been in contact with the anterior portion of the head of the tibia. Both opposing surfaces are roughened and eroded, the tibia showing the greater degree of loss. The patella is displaced outwards and rests on the outer tuberosity of the femur. There is no anchylosis, but there is slight roughening of the ~~contigous~~ contiguous surfaces. The articular cartilage of the joint surface exposed is present, but there apparently was none at the surface of contact.

Purchased.

I65I.I0- Luxation. Anchylosis of knee-joint.
~~1565~~
~~4~~
6 Section has been made at the lower third
1572 of the thigh and the middle of the leg.
40
6 The bones are atrophied especially below the joint and the general shape of the contiguous end, altered. The inner tuberosity of the tibia rests against the posterior surface of the internal condyle of the femur, and the intercondyloid notch; the outer head of the tibia is therefore carried wholly beyond the outer condyle of the femur. The patella rests on the femur in nearly its usual position. Its ligament is intact but is carried 40° inward from the perpendicular. All the bones are firmly anchylosed at an angle of II0° the leg being rotated outwards, no cartilage is visible. There is an opening through the intercondyloid notch. There are no prominent spicules of bone or roughnesses.

Purchased.

I65I.20- Luxation of left knee-joint. Ostitis of shaft of the femur.
1566
41
6 The luxation is backward but is not quite complete.

The patella is attached by its ligament to the tibia. The shaft of the femur at the lower third is thickened from ostitis. The bones of the leg are flexed at an angle of 60°.

Purchased.

1651.30- Outward dislocation of the tibia and patella. Anchylosis of the femur, tibia and patella with caries.

1567
41
6

The specimen is a remarkable one. The limb must have been subjected to extreme violence and the dislocation must have been very old. The femur is strong and evidently from a male subject. No portion of its lower articulating surface remains. Firm coossification has taken place between it and the tibia. The latter bone is rotated outwards 90° and is slightly flexed. The bone is sawn transversely two inches below the tubercle. The cross-section is narrow, the transverse diameter varying from half an inch anteriorly to nearly an inch posteriorly. The antero-posterior diameter is nearly two inches. The patella rests on the outer epitrochlear eminence and is firmly coossified with the femur.





The patella is attached by its ligament to the tibia. The shaft of the femur at the lower third is thickened from ostitis. The bones of the leg are flexed at an angle of 60°.

Purchased.

1651.30- Outward dislocation of the tibia
1567 and patella. Anchylosis of the femur,
41 tibia and patella with caries.
6

The specimen is a remarkable one. The limb must have been subjected to extreme violence and the dislocation must have been very old. The femur is strong and evidently from a male subject. No portion of its lower articulating surface remains. Firm coossification has taken place between it and the tibia. The latter bone is rotated outwards 90° and is slightly flexed. The bone is sawn transversely two inches below the tubercle. The cross-section is narrow, the transverse diameter varying from half an inch anteriorly to nearly an inch posteriorly. The antero-posterior diameter is nearly two inches. The patella rests on the outer epitrochlear eminence and is firmly coossified with the femur.

A small opening is seen anteriorly between the condyles extending to the intercondyloid notch. There is a slight caries of the external border of the patella, of the anterior and exterior aspect of the junction of the femur and tibia, also of the external crest of the tibia. Slight exostoses are seen on the tibia posteriorly.

Presented by Dr. Mütter.

X
I652-
1568
41
6

Gunshot fracture of knee-joint; right. The specimen embraces the lower third of the femur consisting of three fragments; the patella, of two fragments and two inches of the tibia. The ball, of conoidal shape, and about 44 calibre, is in sight resting in the intercondyloid notch. The ball entered at the inner side of the patella, splintering obliquely both condyles, particularly the inner, portions of which are lost. The shaft forms a wedge on either side of which are the two condyles with their respective portions of the shaft, both fragments being about four inches long. The patella exhibits what seems to be an old fracture. A small fragment of the outer portion of the patella one half by one inch, ununited seems to have resulted from some previous violence.

Presented .

1599

destroyed make card.

I652.I0- Fracture of the femur, inter-condy-
1569 loid. Fracture of the head of the tibia.
41 Right side.
6

The line of fracture commences at a point on the outer portion of the popliteal space, runs downward and inward to the middle of the intercondyloid notch, breaking off the outer condyle. The line of fracture in the tibia extends from a line to the inner side of the junction of the inner and outer condyles of the tibia and extends obliquely downwards and inwards. The line of fracture is not complete anteriorly.

1652.15 Comminuted fragments. Presented.
Fracture of left knee joint, Calibre .45 500 yds
see V I
Page 448

1657.30 ~~I654~~ Knee-joint; caries.
1570 Identified as "probably tuberculosis", by Dr. Joseph McFarlane, Curator - April 1939
41
6

Presented by Dr.A.S.Roberts.

1657.40 ~~I654.I0~~ Knee-joint; caries.
1573
40
6

Presented by Dr.A.S.Roberts.

Caries of femur and tibia, following
chronic arthritis of the knee-joint.

[illegible] aged four, admitted to the Children's
Hospital Philadelphia, in the winter of
[illegible]. In september 1870, the right knee
was enormously swollen and presented two
[illegible] openings, communicating with carious
[illegible]. The joint was extremely tender and
[illegible] and distinct grating was felt when
[illegible] the part. Enlargement of the liver
[illegible] presence of albumen in the urine,
[illegible] the history of prolonged [illegible]
[illegible] disease was of eighteen months, these
[illegible] rendered it probable that the kidneys
[illegible] affected with so called "amyloid" or
"lardaceous" degeneration; the child was
[illegible] and irritable, [illegible]
[illegible] excition was resorted to and was
[illegible] by recovery. Trans. Path. Soc.
Philadelphia. Plate [illegible]
[illegible] attain and if possible from Trans.
[illegible] College of Anthrets Surgery.

Presented by Dr. John [illegible] Jr.

Caries of femur, tibia, fibula and
patella and epiphyseal cartilage of
[illegible]

I657-
1574
40
6

Caries of femur and tibia, following chronic arthritis of the knee-joint.

James.C. aged four, admitted to the Childrens Hospital Philadelphia, in the winter of I869-70. In september I870, the right knee was enormously swollen and presented two large openings, communicating with carious bone. The joint was extremely tender and painful and distinct grating was developed on moving the part. Enlargement of the liver and the presence of albumen in the urine, with the history of prolonged suppuration (the disease was of eighteen months standing) rendered it probable that the viscera were affected with so called "anyloid" or "albuminoid" degeneration; the child being anaemic and irritable, amputation rather than excision was resorted to and was followed by recovery. Trans. Coll. of Physicians, Philadelphia/ Third series Vol.2: 68 - 1876 Obtain cut if possible, from Trans. of College or Ashhursts Surgery.

Presented by Dr.John Ashhurst Jr.

I657.I0-
1565
41
6

Caries of femur, tibia, fibula and patella and epiphyseal abscess of tibia.

1605

The specimen comprises portions of all the bones involved in the left knee-joint, all of which exhibit the destructive process. The cartilages which when recent were in a state of gelatiniform degeneration, are not present in the specimen. Fred.G. aged I3 admitted to the Childrens Hospital Philadelphia. December 29" I873. with disease of the right knee-joint of five years standing. The knee was evidently painful and full of pus. The tibia was far advanced in caries. Amputation, January 2" I874. Patient recovered and was discharged in I2 weeks. Trans.Coll. Phys. Philadelphia. Vol.#2 New series. Page 71 - 1876

Presented by Prof.John Ashhurst Jr.

I657.20- Caries of the head of the tibia.
1575
40
6

The specimen is from a child about six years of age, and consists of all the bones of the left leg including the lower fourth of the femur. The epiphysis of the tibia is carious and presents a sinous at the inner and posterior side. Periostitis of the anterior portion of the upper half of the shaft of the tibia has resulted in roughening over that area.

Presented by Dr.John H.Packard.

1657.30 see Vol I page 1599

1657.40 see Vol I page 1599

I658- 1585 40 6

Tibia;necrosis of the knee-joint.

The specimen has been sawn longitudinally through the joint and shows the femur and tibia. The latter bone below the joint is disorganized;there are loose fragments and sequestra. The condition is possibly due to a crushing force directed against the tubercle of the tibia.

Purchased.

I659- 1576 40 6

Arthritis of the knee;right.

The specimen consists of the adjacent ends of the femur and tibia and fibula with the patella. No ossification has occured but the articulating surfaces and their edges abound with new osseous deposit. A thick heavy lip of bone nearly an inch long extends upward from the articulating surfaces of the femur and patella. A new growth as large as the patella itself hangs from the lower and inner border of the patella. The articulating surface of the tibia is bounded on the outer side by a wall of bone,and is eburnated and grooved by contact with the irregular surface of the femur.

Purchased.

I659.05- Arthritis of knee;right.

1577
40
6

The specimen consists of the adjacent ends of the femur and tibia. The edges of the articulating surfaces are marked by ridges from one eight to one fourth inches high. The process has extended to the patellar surface,but is slight. There was no bony anchylosis.

Presented.

I659.I0- Arthritis of knee-joint;right.

1578
40
6

The adjacent ends of the femur and tibia and the patella constitute the specimen. The joint is slightly flexed. Motion of the bones upon each other was possible to a very limited degree. The surfaces of bone about the joint are rough,porous and in many places deprived of compact tissue. The cartilages are destroyed. A prominence of bone due to the inflammatory process affords a resting place for the femur.

Presented by Dr.Mütter.

I659.15- Arthritis of left knee-joint with caries.

1579
40
6

The specimen is from a subject probably about fourteen or fifteen years of age.

Caries is slightly more advanced than in the last specimen. The epiphyses are in an advanced state of caries. In this case the patella shows more the destructive process. The femur and bones of the leg have been sawn at the middle and are flexed at an acute angle.

Presented by Dr.Mütter.

I659.20- Arthritis of knee-joint.Anchylosis; right.

1586
40
6

The disease is of long standing. The femur and tibia are flexed at an angle of II5°, are separable,their articulating surfaces are still seen but motion of the joint was lost. The patella is firmly ossified, throughout its posterior surface,with the femur,and the tubercle of the tibia is marked by a bony prominence pointing upwards. Posteriorly in the intercondyloid notch is seen a piece of bone one and one fourth inches by three fourth inches, articulating with the femur and tibia. This seems to have sprung from the femur to which it is at one point adherent. All the articulating surfaces are marked by prominent and overhanging bony ridges. The tibia is slightly rotated outwards.

Presented by Dr.Mütter.

I659.25- Arthritis of knee-joint. Eburnation.
1581
40
6

Only the lower end of the left femur and the patella are present. There is an osteophytic fringe about the articulating surfaces. The outer trochlear surface is eburnated. Deep grooves correspond to ridges and eburnation in the patella.

missing

I659.30- Right patella and condyles of the femur.
1234
36
1

Eburnation.

The patella is eburnated especially on the outer facette where vertical grooved lines are seen. A corresponding eburnation is seen in the femur. Cross-section immediately above the condyles shows a centre of apparent softening of the spongy tissue.

Presented by Dr.Mütter.

I659.35- Anchylosis of the knee-joint.
1584
40
6

The specimen is from a powerful adult and embraces the lower half of the femur, the upper half of the tibia, together with the patella and its ligaments. The joint is obliterated and the three bones ~~through~~ thoroughly co-ossified. The tibia is slightly flexed and is rotated outwards nearly 45°. No trace is left of the articulating surfaces.

This region,however is abundantly supplied with vascular channels and exhibits can-cellated tissue. Beneath the ligamentum patellae is a sinus situate between the femur and tibia. The patella rests upon a prominent bony outgrowth of the femur and as much of its under surface as is not in contact with the femur is rough porous and deprived of compact tissue. The line of the articulating surface , however,between the bones,can still be traced. The shape of the condyle is very much altered,the tuberosities of the femur are rounded and smooth.

Presented by Dr.Mütter.

I659.40- Anchylosis of the knee-joint.
1582
40
6
The bones are fixed in a straight line and the patella is co-ossified with the femur.

Purchased.

I659.45- Anchylosis of knee-joint.
1586
40
6
The extremities of the bones involved in the left knee-joint are all present. The condition is due to arthritis of long standing.

The bones are fixed at an angle of 110°. The femur is considerably altered. The inner tuberosity is prominent and irregular. There has been imposed upon the articulating surfaces new layers of bone with protuberant lips with irregular edges. The new bone by which the patella and femur are co-ossified, resembles a new patella and forces that bone forward half an inch.

Presented by Dr. Mütter.

1659.50-
1587
40
6

Specimens removed in a case of resection of the knee-joint.

A thin section of the head of the tibia, the patella and a portion of the condyles of the femur, constitute the specimen. The section from the tibia is one quarter of an inch thick. The portion of the femur has been sawn into three sections, the upper section having been made three eighths of an inch above the intercondyloid notch. When freshly removed the articulating bony surfaces were found slightly eroded; the semilunar cartilages had almost entirely disappeared and the synovial membrane had

undergone the characteristic gelatiniform change.

Case of Harry V. aged 4 years 8 months. Gelatinoid arthritis of uncertain duration. Knee- joint swollen, tender, and the seat of consecutive dislocation. Excision by Dr. John Ashhurst, Jr. at the Childrens Hospital. September 30", 1875. Recovery. Trans. Coll. Phys. Phila. Vol. 2 new series. Case 9 p. 65. March 1876

Presented by Dr. John Ashhurst Jr.

1659.55- 1588 40 6

Arthritis of knee-joint; exostoses; eburnation.

Portions of the bone involved in the left knee-joint are present, with the exception of the patella. The specimen is from an adult male. The margins of all the articulating surfaces are rough and prominent. About the internal condyle of the femur especially, the new formation is redundant extending in a fringe upward and creating a deep groove around the internal tuberosity. The inner head of the tibia is eburnated, presenting distinct grooves which correspond to ridges in the femur. The outer head is natural. The spine and tubercle of the

tibia are well marked. Posteriorly and underneath the outer head there is a peculiar civity in the tibia, about the size of a filbert and bridged by delicate fibres of bone. The cavity extends nearly to the articular plate, but does not seem to have been, at the time of removal, the seat of any active pathological process. The articular facet for the fibula is also marked by osteophytes.

Presented by Dr. Mütter.

1659.60- Anchylosis of knee-joint.

1589
40
6

The specimen consists of the adjacent extremities of the left femur and tibia, and the patella, all of which are firmly co-ossified in a position of almost complete extension. The patella occupies its normal position; it is, however, narrow owing to loss of its inner border, probably in the process of preparation. There are no evidences of caries about the joint. The antero-posterior opening usually found in these specimens is present, occupying the intercondyloid space. The junction of the bones are smooth and well rounded, and evidently of long standing.

Purchased.

I659.65- Anchylosis of ankle-joint;caries of the bones of the foot;abscess of condyles of femur.

1583
40
6

The specimen consists of all the bones of the left lower extremity of a child,from the lower third of the thigh. Longitudinal section of the knee-joint shows a cavity in the condyles I.5 by IbyI inches. No sinus is apparent. The articulation is very thin. The ankle-joint and all the other joints of the foot,excepting the phalangeal,are anchylosed. Sinuses extend in every direction,invading the tibia,fibula and tarsus and the extremities of the metatarsal bones. Two large cavities are seen on the calcaneum and outer tarsus. The fifth metatarso phalangeal articulation is anchylosed,the phalanx standing almost erect.

Presented .

I659.70- Femur;lower third;left. Tibia upper third. Ostitis of condyles.

1590
40
6

The articulating surfaces of the bones are rough,porous and devoid of cartilage. The spongy tissue is unprotected. Both bones,from one to three inches from the articulation,show superficial ostitis.

Purchased.

I659.75- Ostitis of the head of the left tibia, with displacement of the patella outwards.

1591
40
6

The ostitis is superficial and is not marked. The patella is attached by its ligament to the tibia and inclines outwards.

Purchased.

I659.80- Specimens from excision of knee-joint.

1592
40
6

The excised portions consist of the condyles of the left femur, section having been made one fourth of an inch above the intercondyloid notch; also of a thin plate removed from the head of the tibia. Both bones are carious, and the articular cartilages eroded. A small pit is seen below the internal tuberosity of the femur, also in the anterior portion of the outer condyle, close to the intercondyloid notch. The spine of the tibia has also been slightly invaded.

Case of Annie McS. admitted to the Childrens Hospital, October 8th 1873, suffering with arthritis of the left knee, with partial anchylosis and consecutive outward and backward dislocation of the tibia. The disease being of two years standing,

excision was performed by Dr.John Ashhurst Jr. Recovery was tedious,but complete.

Trans.Coll.of Phys.Phila. Vol.2 new series pp.59 &60. March 1876

Presented by Dr.John Ashhurst Jr.

I659.8I- Cartilages of the knee-joint;excised. #399
399 Ulceration of the articular surfaces of the bones. Sec 10 Shelf 2

The cartilages are ulcerated and the bone carious. The softening of the bone is distinctly seen in the line of section. Case of S.Call;a patient in the Childrens Hospital,November 20" I878.

Presented by Dr.John Ashhurst Jr.

I659.85- The condyles of the femur;ulceration. #400
Sec 10 Shelf 2

The anterior surface of the outer condyle is eroded,but the bone has not been involved.

I659.86- The patella;ulceration of the articular cartilage. #401
Sec 10 Shelf 2

The outer half of the articular facet has been eroded. The bone is plainly visible. The remaining cartilage,is shreddy,and was apparently in an inflammatory state. This specimen probably belongs to the preceding.

1664- Five cartilaginous bodies, from
1598 knee-joints
48
I 2

1664.10- Cartilaginous

1660-308-

nasal cavity

1660-309- Felidae

Rodentia-

1660-31- Rabbit's skull
1660-32- Paca's skull
1660-33- " skull
1660-34 Agouti's skull
1660-35- Aquatic skull
1660-36- Dasyprocta's skull
1660-37- Maxilla of agouti
1660-38 Three
1660-39- One skull and one maxilla
1660-40- Skull of a Hydrochoerus
Squillus notius that
Considerable protrusion
so quite long antero-posterior
latitude
permits the upper
contact for gnawing
teeth do not
Anatomy of the face
1660-41 Wood Chuck's
1660-42 Porcupine's
1660-43- Mollusca
1660-44
1660-45
1660-46
1660-47
1660-48
1660-49
1660-50
1660-51
1660-52
1660-53
1660-54
1660-55
1660-56
1660-57
1660-58
1660-59
1660-60
1660-61
1660-62
1660-63
1660-64
1660-65
1660-66
1660-67
1660-68
1660-69
1660-70
1660-71
1660-72
1660-73
1660-74
1660-75
1660-76
1660-77
1660-78
1660-79
1660-80
1660-81
1660-82
1660-83
1660-84
1660-85
1660-86
1660-87
1660-88
1660-89
1660-90
1660-91
1660-92
1660-93
1660-94
1660-95
1660-96
1660-97
1660-98
1660-99
1660-100
1660-101
1660-102
1660-103
1660-104
1660-105
1660-106
1660-107
1660-108
1660-109
1660-110
1660-111
1660-112
1660-113
1660-114
1660-115
1660-116
1660-117
1660-118
1660-119
1660-120
1660-121
1660-122
1660-123
1660-124
1660-125
1660-126
1660-127
1660-128
1660-129
1660-130
1660-131
1660-132
1660-133
1660-134
1660-135
1660-136
1660-137
1660-138
1660-139
1660-140
1660-141
1660-142
1660-143
1660-144
1660-145
1660-146
1660-147
1660-148
1660-149
1660-150
1660-151
1660-152
1660-153
1660-154
1660-155
1660-156
1660-157
1660-158
1660-159
1660-160
1660-161
1660-162
1660-163
1660-164
1660-165
1660-166
1660-167
1660-168
1660-169
1660-170
1660-171
1660-172
1660-173
1660-174
1660-175
1660-176
1660-177
1660-178
1660-179
1660-180
1660-181
1660-182
1660-183
1660-184
1660-185
1660-186
1660-187
1660-188
1660-189
1660-190
1660-191
1660-192
1660-193
1660-194
1660-195
1660-196
1660-197
1660-198
1660-199
1660-200
1660-201
1660-202
1660-203
1660-204
1660-205
1660-206
1660-207
1660-208
1660-209
1660-210
1660-211
1660-212
1660-213
1660-214
1660-215
1660-216
1660-217
1660-218
1660-219
1660-220
1660-221
1660-222
1660-223
1660-224
1660-225
1660-226
1660-227
1660-228
1660-229
1660-230
1660-231
1660-232
1660-233
1660-234
1660-235
1660-236
1660-237
1660-238
1660-239
1660-240
1660-241
1660-242
1660-243
1660-244
1660-245

M. H. Cryer Anatomical Collection.

Primates-

1660.00- Skull of old world Monkey. Sec. 79-Sh. 2
1660.01- Skull of old world monkey. Sec. 79-Sh. 2
1660.02- Skull of Cercopithecus - Sec. 79-Sh. 2
1660.03- Monkey mandible - Sec. 79-Sh. 2
1660.04- Monkey mandible - Sec. 79-Sh. 2
1660.05- Monkey mandible - Sec. 79-Sh. 2
1660.06- ~~Catarrhine~~ Catarrhine monkey mandible - Sec. 79-Sh. 2
1660.07- Maxilla of monkey - Section 79-Shelf 2
1660.08- Macaque monkey skull - Sec. 79-Sh. 2
1660.09- Chimpanzee Skull - Sec. 79-Shelf 2
1660.10- Chimpanzee skull - Sec. 79 Shelf 2
1660.105- Male Gorilla skull. Sec. 79-Shelf 2
1660.106- ~~Catarrhine~~ Catarrhine monkey skull - Sec. 79 Shelf 2
1660.11- Mustelini skull. Sec. 79-Sh. 3

Carnivores-

1660.12- Bear skull - Sec. 79-Sh. 3
1660.14- Black bear skull Sec. 79-Sh. 3
1660.15- Candidae skull - Sec. 79-Sh. 2
1660.16- Candidae skull - Sec. 79-Sh. 3
1660.17- Candidae skull. Sec. 79-Sh. 3
1660.18- A.B.C.D Transverse sections of a dog's face. Sec. 79-Sh. 2
1660.19- Eight sections of the head of canine. Sec. 79-Sh. 2
1660.20- 1660.21- Mandible of a member of the Candidae family.
1660.22- Sections of a dog's head. Sec. 79-Sh. 2.
1660.23- ~~Dog~~ skull Sec. 79-Sh. 2
1660.24- ~~Dog~~ 's skull Sec. 79-Sh. 2
1660.25- Wolf. Mandible Sec. 79-Sh. 2
1660.26-
1660.27- Woolverine - Sec. 79-Sh. 2 Lower jaw.
1660.28- Wolverine - Sec. 79-Sh. 2 Lower jaw.
1660.29- Tiger Skull Sec. 79-Sh. 2
1660.295- Skull of a cat - Sec. 79-Sh. 2
1660.30- Part of a skull of a cat - Sec. 79-Sh. 2
1660.305- Mephitis (skunk) Skull
1660.306- Transverse section of a dog's skull.
1660.307- Sagittal section of a greyhound's skull. The nasal cavity extending to the outer wall of the maxilla. No true sinus is found, tho the inferior concha helps to partly shut off a space which might be named the conchomaxillary sinus. Fig. 273- Cryer's Internal Anatomy of the Face

I664- 1598 48 72 Five cartilaginous bodies, from the knee-joint.

I664.IO- Cartilaginous body from the knee. #402
Sec 10
Shelf 2

1660-308- Sagittal section of a badger's skull. The root of a tooth is seen in the floor of the nasal cavity similar to the roots shown in the human nasal cavity. Fig. 274- Cryer's Internal Anatomy of the Face.
1660-309- Felidae skull

Rodentia-

1660.31- Rabbit's skull.
1660.32- Paca's ~~head~~ skull. (South American Animal)
1660.33- " skull " " "
1660.34- Agoutis skull.
1660.35- Agoutis skull.
1660.36- Maxilla of a ground hog. part of skull
1660.37- Maxilla of a ground hog. part of skull
1660.38- Three muskrat mandibles
1660.39- One skull and one maxilla of a wood chuck.
1660.40- Skull of a Hydrocherus Capybara. It will be noticed that the lower incisors are considerably posterior to the upper. The mandible fossa is quite long anteroposteriorly, which allows great latitude in carrying the lower jaw forward and permits the upper and lower incisors to come into contact for gnawing purposes, while the posterior teeth do not occlude. Fig. 65-66 Cryer's Dental Anatomy of the Face.
1660.41- Wood chuck's lower jaw
1660.42- Porcupine's skull
1660.425- Muridae - Part of skull
1660.43- Tooth of a beaver
1660.435- Three unidentified rodents
1660.436- Wood chuck - Part of skull

~~Hoofed~~ Mammals.

1660.44- Calf - Two cross sections of the skull.
1660.45- Bovidae (sheep) showing maxillary sinus

1660.46 Deer Mandible
1660.47 Deer mandible
1660.48 Deer mandible
1660.49 Deer mandible
1660.50 Skull of a deer
1660.51 Green sea-turtle skull

Pices.

1660.511 Part of the lower jaw and fragments of a jaw of the sheep-head fish

1660.512 Skull of a Bald Eagle. Accipitriformes - Haliaeetus leucocephalus.
From the H. H. Cuyler Anatomical Collection.
Presented to Dr. Cuyler by Horace J. Mann, M.D.
Dr. Mann found the skull of the eagle on the shores of Lake Ontario in the summer of 1917.

1660.52 Armadillo - part of a skull
1660.53 Opossum - part of a jaw
1660.54 - Wallaby - part of a skull

ANKLE-JOINT.

1667
to
1674.

1635

I667- Lower end of left tibia and fibula and tarsus. Crush of the ankle-joint. The specimen was probably removed by amputation, at the lower third of the leg. The articular surface of the tibia has been split into three parts; posterior portion belongs to the shaft of the bone composing the upper fragment. The remaining fragments, insize and shape resembling a patella, are situated on the right and left of the shaft. They are held in place by the ligaments of the ankle-joint. The external malleolus was broken by direct violence. The lower fragment measures 2.5 by 3 cm. and was carried inward. The astragalus was not fractured. The calcaneum was crushed at the middle, and presents a gaping fissure, exposing the spongy tissue. The anterior edge of the cuboid bone has been broken off.

Purchased.

1672 I668- Caries of the tarsal and metatarsal joints.

Presented by Dr.A.S.Roberts.

Missing

1674- Right tibia. Arthritis of the ankle-joint, with hyperostosis.

This bone is an example of one of those doubtful cases, in which the articular surface and the surrounding parts are so changed by pathological processes as to lead one into doubt as to whether he is dealing with case disease, or with deformity after fracture. The lower end of the bone is very much altered. Anteriorly it is noticed that the broad, smooth, flat surface above the ankle-joint is not present. The lower half of the bone produces in this region a marked concavity. The lower anterior margin is far in front of its natural position. So, also, the lateral lines spread suddenly outward at the ankle-joint. The posterior border of the joint, instead of being flat and rectilinear is pointed. The articular surface is triangular and plainly marked into three segments, two of them resembling strongly the third, the internal malleolus. Between the latter and the posterior projection, a deep fissure is seen. Smooth articular surface is seen, chiefly at the inner side, the remainder being rough and exposing the spongy substance.

1720.5 Injuries of tendons. Bones of left foot. Lower portion of tibia and fibula. Injury the result of forcible extension. Separation of Calcaneoastragalo-joint.

See 37-Shelf 6.

1674- Right tibia. Arthritis of the ankle joint, with hyperostosis.

This bone is an example of one of those doubtful cases, in which the articular surface and the surrounding parts are so changed by pathological processes as to lead one into doubt as to whether he is dealing with case disease, or with deformity after fracture. The lower end of the bone is very much altered. Anteriorly it is noticed that the broad, smooth, flat surface above the ankle-joint is not present. The lower half of the bone produces in this region a marked concavity. The lower anterior margin is far in front of its natural position. So, also, the lateral lines spread suddenly outward at the ankle-joint. The posterior border of the joint, instead of being flat and rectilinear is pointed. The articular surface is triangular and plainly marked into three segments, two of them resembling strongly the third, the internal malleolus. Between the latter and the posterior projection, a deep fissure is seen. Smooth articular surface is seen, chiefly at the inner side, the remainder being rough and exposing the spongy substance.

Its surface is much deeper, and its concavity is spheroidal. The surface of the bone above the ankle, is marked by depressed vascular channels. The subcutaneous surface abounds in vascular openings and vertical striations.

Presented.

Missing

1674.10- Tibia, fibula, astragalus and calcaneum. Anchylosis of ankle-joint.

The tibia and fibula have been divided at their middle. The ankle-joint is obliterated. Vertical section has been made, and shows no trace of the articulation. The spongy tissue is continuous from the lower border of the astragalus into the shaft of the tibia. The compact tissue and cartilage of the joint, are not seen. The calcaneo-astragaloid articulation is unimpaired, save for some lips of callus at the periphery.
H.H.S.

Purchased.

1689- Bones of left foot. Tarso-metatarsal anchylosis.

1595
40
6

Of the third, fourth and fifth metatarsals, only the proximal portions remain.

Their stumps are atrophied, and the bases of the third and fourth are co-ossified with each other, and with the cuboid. The scaphoid, first, second and third cuneiforms, and the base of the second metatarsal are also co-ossified. The first cuneiform is displaced laterally, and forms a prominence on the inner side of the foot. The base of the fifth metatarsal, forms a prominence on the outer side of the foot. The long axis of the astragalus, points towards the place of the little toe. The The outer toes and metatarsala have been subject to some destructive process. The arch of the foot is lost, and the irregular inferior surface of the tarsus, rests on the floor. (In case with tarsus.)

Presented by Dr. Mütter.

deaccessioned gm

I720- Injuries of tendons. Evulsion.
1599
48
2

Thumb torn from the hand with extensor. From a man whose finger was caught between two railroad cars.

Presented by Dr. Mütter.

I724- Displacement. Repair after subcutaneous division.

#403
Sec 10
Ref 2

Two specimens of the tendo achillis, united after section. From a case in which the tendons were cut, I6 years previously, to relieve talipes. No trace of the section is seen.

Presented by Dr. Mütter.

V
I726- Diseases of tendons. Diseases of the sheaths of tendons.

Bodies found in the fluid of chronically inflamed sheaths of tendons and ganglia.

V
I728- Bodies taken from the palm of the hand.

Presented by Dr. J. Furbell.
December 23. I845.

Two specimens of the tendo achillis, united after section. From a case in which the tendons were cut, 16 years previously, to relieve talipes. No trace of the section is seen.

Presented by Dr. Matter.

1728- Diseases of tendons. Diseases of the sheaths of tendons.

Bodies found in the fluid of chronically inflamed sheaths of tendons and ganglia.

2003.5 Pericarditis - Vol. 1. Pg. 34
1704
107
2

1728- Bodies taken from the palm of the hand.

Presented by Dr. J. Purbell.
December 23. 1845.

Heart 8 1740
a patient in Episcopal Hospital with marked aortic & mitral obstruction ~~following~~ Typhoid fever preceeded final illness -
Pericardial adhesions - endo - carditis - Globular thrombi - hypertrophy & dilatation - aortic valves thick & cretaceous - mitral leaflets thickened with cretaceous deposit near base.
Death occurred 10.20.91
P.M. 10.21.91

P. 1645 A

Circulatory.

Symphatics. SYSTEM.

Respiratory.

Digestive.

2000- Heart normal.

2003- Heart and Pericardium.

Plastic pericarditis.

2003.1 Pericarditis; Child Vol. 1 - Pg. 34
1689
1
Presented by Dr Eshner

2004- Heart; adherent pericardium; hypertrophy.

The pericardium is thickened in its entire extent and adherent to the heart. The heart itself is hypertrophied.

From the Philadelphia Hospital.

2015- Eustachian valve; enlarged.

The valve is large; raised by its free edge it is of triangular shape having an altitude of 2.3 cm. and a base of 3 cm. The base is attached to a portion of the auricle, which is thickened and which is evidently from an adult. The valve is fenestrated, giving it a lace-like appearance.

Presented by Dr. J. Parrish.

2015.10- Eustachian valve from an adult. Vol 1 - Pg. 36
1692

This specimen is smaller than the preceding. The sides of the triangular valve are about 2 cm. in length. The valve is also fenestrated and is attac[illegible] to a po[illegible]n

of the auricle.

Presented by Dr. Mütter.

2015.20- Heart. Inter-ventricular sinus.

1734
108
4

A probe traverses the sinus which is apparently pathological.

Presented.

2020- Heart from a case of congenital cyanosis. From a boy aged 10 years.

Presented by Dr. Tucker.

2023- Heart and aorta;laceration; death from hemorrhage. The aorta has been nearly severed from above downward a few millimetres beyond the origin of the left subclavian.

Presented by Dr. Mütter.

2025- Heart;hypertrophy with dilatation.

The heart is greatly hypertrophied and dilated; the latter is especially true of the auricles,which are quite translucent.

Presented.

2025.05- Heart; hypertrophy. Vol. 1 - Pg. 36

1696

The left side of the heart is greatly hypertrophied; the valves of that side appear normal;the pericardial surface is smooth.

Presented by Dr. Mütter.

1649

2025/10- Heart. Hypertrophy. Vol. 1. Pg. 36
1697

The hypertrophy is enormous; the weight when recent with clots, after removal of the adgerent pa ts except the pericardium, forty-eight ounces. The pericardium was uniformly adherent, leaving no pericardial cavity. The right ventricle contained about six ounces, and the left, two ounces of soft postmortem clots. After washing, the weight was forty ounnes. All the valves and blood-vessels are healthy. The mitral valve measured two inches across.

Patient aged 18. The hypetrophy followed an attack of muscular rheumatism, accompanied by a strong, harsh, mitral systolic and presystolic murmun. This murmun disappeared. A parotid swelling appeared; ascites, oedema andpleurisy supervened; the urine contained no albumen or sugar.

Death from asphyxia.

12.75

Trans. Phila. Path. Society, Dec. 13th, 1883.

Presented by Dr. Chas. W. Dullas.

2028.- Heart; fatty degeneration and hypetrophy.

There is an old organized clot in the left ventricle; associated with this condition were apoplectic clots in the middle lobe of the right lung.

From an old gentlemen who died several weeks after musual exertion, in lifting a trunk. Cardiac dilatation, dyspnoea supervened.

Presented by Dr. J. C. Morris.

2029.- Heart; spontaneous rupture.

When recently removed the pericardium was fwhich the s.

greatly distended by firmly coagulated blood which had issued from the heart through a small rupture of the left ventricle near the apex. The heart was greatly softened throughout its entire structure and especially at the point of rupture. Valves healthy; Aorta normal with no atheromatous deposits. Lungs perfectly normal.

From F.M.L., aged 34 years, male. He had been subject to dyspnoe from several months previously, a slight cough and a feeling of constriction across the upper part of the chest with moderate expectoration of glairy mucous. Complexion pale; pulse weak but regular; tongue clean and bowels regular. He had lost flesh and had been treated for Phthisis. He had long been habituated to the unmoderate use of whiskey. Careful examination of the chest made by Dr. Packard two months before death did not reveal the slightest evidence of cardiac trouble other than the somewhat enfeebled action of the heart corresponding with his debility. Respiration normal. He said he had sensations as if something were tearing within his chest at times. He was not subject to palpitation of the heart.

April 9th, 1867 while preparing to go out for a walk and while endeavoring to get his foot into a tightly fitting boot, he suddenly fell from his seat gasping and struggling violently for breath, his face becoming livid. He remaining in this condition, gradually growing weaker, for two hours, when death ensued.

Trans. Path. Society Phila., Vol. III p 43. April 25, 1867

Presented by Dr. John A. Packard.

2029.10-
1758
109
1

Heart; spontaneous rupture.

When recently removed, the body from which the spec-

imen was taken contained subcutaneous fat about one inch thick. About eight or ten ounces of clotted blood or serum were taken out of the pericardium. The valves were competent on trying the water test. The aorta and mitral valves showed the beginning of atheroma but only slightly. The cause of death was found in a rupture of the walls of the left ventricle. The external orifices were mere slits from 3 to 4.5 mm. long respectively, 6mm. apart 12mm. from the septum ventriculorum anteriorly and 5 cm. from the apex respectively. Internally there was but a single opening, hidden completely by the columnae carneae, as shown by two probes passed from the exterior. The walls of the right and left ventricles were 4.5 mm. and 15 mm. thick, were not fatty to the eye and were not at all torn or undermined in any way by the rupture. The heart contained no clots, save one, quite small, entangled in the columnae carneae at the internal opening and composed of two parts, one half of white fibrin, the other half of more recently coagulated blood. On microscopical examination, the muscular tissue was found very fatty, the striation being plainly visible, however, at most points; but the fibres everywhere broke up longitudinally into fibrils on the slightest violence.

From Mrs. S., aged 68 years, who had been generally in poor health for several years and who, a year previous to death, had been cautioned as to exertion, on account of a fatty heart.

Sept. 16th, 1874 she did not feel well and her hands and feet were cold; she had vomiting and retching in the morning; rose at noon; at one o'clock having been about the room she felt rather worse and lay down; she then sat up in bed, retched and suddenly threw herself back and was dead.

Half an hour after death there were frequent, inconstant spasmodic movements of the whole foot and great toe; these movements were observed for an hour by Dr. Keen.

Trans.Phila.Path.Soc'y.vol V,p.94. Sept. 23, 1874

Presented by Dr. W.W.Keen.

2030. see vol I page 1676

For Microscopic Sections of Aneurisms, see

ANEURISMS.

2031- Heart; aneurism of the apex of the left ventricle.

The heart is hypertrophied; the left ventricle is greatly distended and dilated forming, when viewed externally, a large knob at the point of the heart. The wall of this aneurism is thin but firm and filling its cavity is a firm clot.

Presented by Dr. Mütter.

Vol. 1-Pg. 36

2031.05- Heart; aneurism of the left ventricle and ascending arch of the aorta.

1705

The dilatation is very great and involves the region of the aortic valves and the ascending portion of the arch of the aorta as well as the upper portion of the ventricle.

Presented by Dr. Mütter.

Vol. 1-Pg. 36

2031.10- Heart and anterior thorax; aneurism of the left ventricle; destruction of the anterior chest wall.

1706

The left ventricle is enormously dilated. Its wall is adherent to the thorax in front and at one place rupture has taken, apparently, place. The sternal ends and cartilages of the adjacent ribs are eroded and the tissues are ragged, owing to the impulse of the

aneurism.

(1767) 2031.15 see Vol I Page 1687

(1764) 2031.20 see Vol I Page 1687

Presented by Dr. Mütter.

2035- see vol I page 1676

1738

2036- Tumor from the mitral valve.

The tumor is globular and has a diameter of 3.5 cm. It is laminated, the outer wall having a thickness of from 1 to 3 cm. Within this is a slightly smaller and thinner laminated layer, separated a few millimeters from the outer wall. The exterior is smooth.

Presented by Dr. Mütter.

2046. see vol I, Page 1676

2050- Left ventricle and ascending aorta; acute endocarditis.

The valves are thickened, eroded and ragged; they were evidently insufficient.

From a patient in the Philadelphia Hospital who also had renal embolism, g.v.

Presented by Dr. Wm. Pepper.

2050.05 (1739) See Vol I, Page 1676

2050.10 (1741) See Vol I, Page 1676

2057- Left heart. ~~Alturoma~~ atheroma of mitral valve.

The mitral valve is thickened with a firm calcareous deposit. The heart is apparently not hypertrophied.

Presented by Dr. Mütter.

2058- ~~Altnroma~~ atheroma of the aortic valves.

1709

Presented by Dr. Mütter.

1659

2058.05- Atheroma of the aortic valves.

1710

Vol. 1- Pg 38

Presented by Dr. Mütter.

2058.10- Stenosis of the aortic valves with calcareous degeneration.

1711

The valves are exceedingly thick and rigid so that but only a very small quantity of blood could have passed through them, The handle of a scalpel can with difficulty be introduced between the edges of the valves.

From a man aged 68 years. He had not been suspected of heart disease;his circulation and respiration had never been impeded sufficiently to arrest attention excepting in one instance ten months previous to death when he suffered from congestion of the lungs, The latter condition was present during his last illness and slight hemorrhage took place.

Vol. 1- Page 38

Presented by Dr. John Neill.

2058.15- Cir.19. Atheroma of the aortic valves.

1712

Vol. 1- Pg. 38

Presented by Dr. Mütter.

2058.20- Cir.20. Atheroma of the aortic valves.

1713

Vol. 1- Pg 38 Presented by Dr. Mütter.

2058.21- Heart. Stenosis and atheroma of aortic valves.

Missing

1735
108
4

Presented.

2058.25- Cir.21. Heartlstenosis of the aortic valves,with extensive calcareous degeneration reaching nearly to

1728
107
4

the mitral valve.

The heart is moderately enlarged, the enlargement being confined to the left side, the right ventricle appearing as a patch on the side of the organ. The right auricle and ventricle, with the openings and valves on that side, are normal. The left auricle is somewhat enlarged, its wall about normal, certainly not thickened; the endocardium somewhat thickened. The mitral orifice was found considerably dilated, the valvular leaflets, nearly normal and likewise the tendons. The cavity of the left ventricle is dilated and the ventricular walls about normal or perhaps slightly thicker.

The aortic orifice is narrower, slit-like, allowing merely of a nickel five cent piece being passed edgewise through it. The two anterior cusps are firmly united as far as their middle part along their line of mutual contact. The posterior cusp was still slightly flexible at its posterior part. There is a large calcareous deposit, extending not only throughout the whole extent of the semilunar valves, but reaching down to the origin of the mitral leaflet.

The aortic sinuses are reduced in size; the aortic wall at this portion is nearly normal except at a few points near the opening of the coronary arteries, where are seen small atheromatous changes. These arteries have their walls normal and are surrounded by a pad of fat.

The ascending part of the aorta is slightly enlarged, though the wall of the vessel is smooth and of normal texture. Atheromatous changes are visible where the vessels leav[illegible] va[illegible]h of the aorta.

Microscopic examination showed the heart fibre of the left ventricle granular and fatty;the striation had largely disappeared.

(Dr.Morris Longstreth.)

From a man aged 50 years of medium size,a regulator of gas-metres. Healthy till six months before death,he had malarial fever followed by icterus,ascites and great general debility. His physical condition a few weeks before death was deplorable;icterus,ascites, dyspnoea, anorexia,intense pre-systolic and post-systolic cardiac murmurs audible before the ear reached the chest. Improvement followed treatment,but he was found dead in bed after returning to work on his dicharge from the hospital.

In addition to the condition of the heart noted above,the body was found in good condition with plenty of adipose tissue;liver cirrhotic;the remaining organs appeared normal.

Trans.Phila.Path.Soc.vol Vlll.p.64 Dec.27 1877

Presented by Dr. J. Solis-Cohen.

2058.26 Calcification of the aortic valves.
1714 Vol. 1-Oz 38

2060- Heart, Atheroma of the coronary arteries.

On removal from the body,the heart was found to be nearly twice its natural size and flabby. The valves of both sides were more or less ossified and across one of the aortic sinuses of Valsalva was a rod one inch(2.5 cm.) in length and three lines (6mm.) in thickness;one end rested against the internal surface of the aorta and the other end against the corpusculum Arantii,thus keeping the valve permanently stretched toward the ven-d

triule. This condition is not preserved in the specimen. The coronary arteries are atheromatous and large. At the autopsy no effusion was found in the pericardium or pleurae. The aortic and mitral valves seem healthy. The apex of the heart has been cut away;about one inch of the aorta remains.

From C.W.M.,aged 61,one of three brothers,all of whom had died of a similar disease and who belonged to a very gouty family. He had suffered from dysponea and palpitation for three years but continued actively engaged in his pursuits until within a few months of his death. Dysponea increased and respiration alarmingly slow during sleep. Death occurred easily and suddenly.
See Summary of Trans. Coll. of Phys. Vol III - 1849-1850 Page 23.

Presented by Dr.Isaac Parrish, 1849.

Missing

2060.5- Heart. Atheroma;hypertrophy.
1716
Vol. 1 - Pg 38

Presented.

2061-Cir.4. Vertebral artery arising from the aorta.
1717(?)

The vertebral artery comes from the aorta between the left common carotid and subclavian.

Vol 1. Pg. 38 ?

Presented by Dr. Mütter.

2061.05-Cir.4.5. Anomalous origin of the right subclavian artery and of branches of both subclavians.
1720

The right subclavian takes its origin from the superior and posterior aspect of the aorta on the left side at a point corresponding to the junction of the transverse with the descending portion of the arch and

Vol. 1 Pg. 38

one inch from the point of origin of the left subclavian artery. From this origin it takes its course backwards and obliquely upwards, passes between the oesophagus and vertebral column, traversing portions of the second and first dorsal vertebrae and reaches its normal position on the upper and outer surface of the first rib.

The right primitive carotid artery occupies the place of the innominate, arising from its point of origin at the commencement of the transverse position of the aortic arch.

The left primitive carotid originates in close connection with the right carotid artery and in this respect occupies a position more to the right than is normal; in crossing to its distribution on the left side of the neck it covers a large surface of the trachea than is natural.

The left subclavian artery arises from the summit of the arch of the aorta--the middle point of the transverse portion of the arch, which is the normal point of origin of the left primitive carotid artery, deviating from its normal origin at the end of the transverse portion of the arch.

The thyroid axis on either side is absent.

The right inferior thyroid arises, independently, from the first part of the subclavian artery at a point on the anterior surface and near to the inferior border.

The left inferior thyroid arises, independently, from the anterior surface near the superior border from the first part of the subclavian artery.

The vertebrae artery is smaller on the right side than on the left and arises from the superior surface

con.

Preps by Dr. Fred D. Weidman.

2065.13. Congenital Stenosis (Coarctation) of Aorta. Wax cast of lumen of aorta executed by Dr. Fred D. Weidman. From autopsy on a robust negro, aged 35 years, dying very suddenly of pulmonary oedema. The heart weighed 750 grams, and the internal mammary and superior intercostals were also markedly hypertrophied. The aortic valvular orifice was two-cusped.

The original specimen (aorta, aortic cusps and internal mammary arteries) are on exhibition in the Pathological Museum at the Medical School of the University (G.C. 443-444-445-446) and very detailed records are on file in the Pathological Laboratory there (U.P. Path. Inst. 4636-'13-124).

Full description of this condition given by Dr. Maude Abbott in Osler's System of Medicine under Anomalies of Heart and Blood-vessels.

The two colors of wax are used to indicate the two pieces which were used together in constructing the model; the heart and adjacent aorta having been removed at autopsy before the rest of the aorta was dissected out.

The specimens were exhibited before the Pathological Society of Phila., and an abstract of the presentation appears in its Proceedings (1914, N.S. XVI, p. 98.

In the photograph here with the aorta is shown in the middle, the hypertrophied internal mammary arteries under the breastplate on the right and a normal breastplate (inferior surface) on the left.

The steno[illegible] occurs at the scar which develops at the [illegible]trophe[illegible]ctus arteriosus

the subclavian artery; on the left side, from the superior and posterior surface of the artery; on both sides, from the first part of the subclavian.

Dissecting room specimen.

Amer. Jour. Med. Sciences, Oct. 1871.

Presented by Dr. J. Ewing Mears.

2065- Atheroma of arteries.

Presented by Dr. Mütter.

2065.05- Atheroma of abdominal aorta and iliacs.

Presented by Dr. Mütter.

2069- Ligature of carotid and vertebrae arteries in a rabbit.

The arteries on the left side are obliterated; on the right side, they are distended.

Presented by Dr. Mutter.

2077- 1724 106 4 An aneurismal sac.

The sac of this aneurism is large and of globular shape, having a diameter of about 11cm. Its walls are not thin; apparently they are strong and are reinforced by fibrous bands which are seen in the interior. The inner surface is shaggy and of rough fibrinous character.

Presented by Dr. Mütter.

2079. 1753 107 6 False aneurism of the leg. " " " H. R. Wharton.

2082- Aorta;atheroma,
1725
106
4

The specimen consists of the greater portion of the aorta;it is dilated and when laid open shows a breadth of from 7 to 10 cm. and is a marked example of calcareous degeneration.

Presented by Dr. Mütter.

2082.05- Heart and aorta;atheroma of the aorta with dilatation,
1726
106
4

Presented by Dr. Mütter.

2082.10- Arch of the aorta;atheroma.
1727
106
4

Presented by Dr. Keating.

2082.15- Atheroma of the aorta.
1729
107
4

Presented by Dr. Mütter.

2082.20- Atheroma of the aorta with dilatation.
1723

Presented by Dr. Mütter.

2082.30- Heart and aorta;aneurism ofthe aorta and atheroma.
1730
107
4

The heart is enlarged;its valves appear normal. The aorta is thickened,rough and dilated. There is a sacculation or recess in the aorta just above the aortic valves.

From the Philadelphia Hospital.

2082.06 ~~2098~~- Heart and large vessels;aneurism of the arch of the aorta;absorption of the sternum.
1731
107
4

The heart is greatly hypertrophied. The arc[illegible] the aorta is enormously distended. On the su[illegible]

face of this dilatation a large laminated clot is seen. The aneurism exerted great pressure anteriorly on the sternum, producing absorption of it, and posteriorly on the trachea, which is attached to the specimen and which shows near its bifurcation ulcerated points.

Presented by Dr. Mütter.

2082.40- Aneurism of the arch of the aorta.

1732
107
4

The arch of the aorta has been removed and laid open; it shows slight thickening of the aortic valves, dilatation and thickening of the aorta. The latter has a large pocket partly filled with a firm, laminated clot.

Presented by Dr. Mütter.

2082.50- Aneurism of the arch of the aorta opening into the trachea.

1733
108
4

Presented by Dr. Mütter.

2082.55- Aneurism of the arch of the aorta.

1748
107
5

The aneurism is of large size and involves the entire arch; the heart seems somewhat hypertrophied. No examination of the valves has been made. The pericardium is thickened and adherent. The aneurism was adherent to the sternum to such an extent that in its removal much of the anterior wall was cut away; there are strong adhesions to the trachea and pulmonary artery, which are embraced in the specimen. The aneurism was filled with laminated clots.

From J.D., colored, aged about 50. First seen August

6th,1866;stated that he was attacked first seven months before with palpitation and shortness of breath,which gradually increased,and finally forced him to discontinue work. When first visited he was found sitting up in bed,although able to lie down if his head were moderately elevated by two or three pillows.

Heart found pulsating very forcibly,a little to the left and below its normal position;dullness on persussion on the upper part of the sternum and a little to the right,and slight pulsation distinguishable there. The sounds of the heart were also to be heard in the region but neither at this time or subsequently was there any marked abnormal sound either in theregion of over the heart. The normal heart sound was heard over the tumor.

Morphia and a little digitalis were prescribed and in a month he had so much improved as to be able to walk about,and even went up and down stairs and worked a little about the house,contrary to the directions which had been given him.

About October 15th,he became worse,and there was strong expansive pulsation of the right subclavian and axillary. He was unable to lie down for even a moment on account of difficulty of breathing.

Oedema of face,chest and arms soon set in, which became excessive,and was accompanied with pain,particularly in the arms. A puncture was made in one elbow, but although a good deal of serum was discharged,there was but little subsidence of the swelling even in the immediate neighborhood,and no relief of the pain.

He died December 8th.

2082.561
1736 Patient died of Bright's disease Slowly
108 Granular degeneration of Tricuspid valve
4
Pres by Dr Fred Packard

2082.562
1737 Heart showing pulmonary valve composed of only two
106 leaflets atheroma of aorta &c
5
Pres by Dr Fred Packard

see vol I page 1657

2035.
1738 Heart showing a condition of Myocarditis
106
5
Pres by Dr F A Packard

see vol I page 1657

2050.05
1739 Heart showing adhesions Pericarditis and endocarditis acute
106 of right & left sides
5
Pres by Dr Charles Fraser
Blockley 4-27-95

2082.575
1740 Heart showing aortic and mitral obstruction
106
5

see vol I page 1657

2050.10
1741 Heart Endarteritis of Aorta Inflammation of Aortic
107 Cusps commencing atheroma of mitral cusps
5
Patient was Frederick Shoemaker 419 Lombard St
Died Oct 27th - 1896
Pres by Dr Fred Packard.

see Vol I, page 1657

2046
~~1742~~
~~107~~
~~5~~
Heart Large opening between rt and left auricles
Pres by Dr Packard

1757
106
6

see vol I page 1655

2030
1756 Heart. Dilated and hypertrophied atheroma
108 of aorta
6
Pres by Dr F A Packard

~~1757 Calkins heart~~
108
6

2082.60- Heart and aorta;aneurism of the ascending and de-
17443 scending arch.
107
5

The heart appears normal. The ascending arch is considerably dilated. The descending arch is the seat of a small aneurism 4 cm. long,symmetrical,and filled with a firm laminated clot.

From an old negro coachman of Dr. Mütter's. The aneurism was of from two to three years duration. Death occurred from rupture (probably from the smaller aneurism).

Presented by Dr. Mütter.

2082.61- Aneurism of the arch of the aorta and innominate.
1749
106
6

Presented by Dr. DeF.Willard.

See Univ.Med.Mag. July or August,1891.

2082.65- Aneurism of the arch of the aorta.
17444
107
5

The sac is enormous,involving the entire arch and from its posterior surface,the large vessels are seen to arise. The left jugular vein is obliterated and is marked by a whalebone. The superior portion of the heart remains and does not seem to be hypertrophied. No clots are present in the aneurismal sac,the diamater of which may be said to be 10 cm.

Presented by Dr. Mütter.

2082.66- Aneurism of the arch of the aorta;with clot.
1750
106
6

Presented.

1679

2082.70- Aneurism of the descending arch of the aorta.

1746
108
5

The specimen has been mounted dry. The heart appears of normal size. The aneurism is situated about 5 cm. beyond the origin of the left subclavian and forms an enormous mass, covering the third, fourth, fifth, and sixth vertebrae and being attched to the second, third, fourth, fifth, sixth, and seventh left ribs. The continuity of the latter two, at least, has been destroyed. The antero-posterior diameters of the sac is 12 cm. The aneurism is also found to lie on the right side of the vertebral column, opposite the heads of the third, fifth, and sixth right ribs, pressing forward the trachea and oesophagus. The aneurism formed a large pulsating tumor on the posterior left thorax projecting considerably beyond the spine; it was filled with a large amorphous clot.

Presented by Dr. Mütter.

2082.75- Aneurism of the arch of the aorta.

1747
108
5

The heart is of normal size. The aneurism is sealed in the transverse arch immediately beyond the origin of the left subclavian. It has a vertical extent of eight centimeters and measures 10cm. laterally. A clot is seen in its cavity.

The specimen has been mounted dry.

Presented by Dr. Mutter.

2082.80- Aneurism of the arch of the aorta.

1748
108
5

The dilatation is in the entire arch. The ascending portion has a diameter of 5cm; as it becomes transverse, there is a sudden expansion of the coats giving

rise to a rounded protuberance which is about 4 cm. in diameter, containing a clot, The descending aorta has a diameter of 4.5 cm.

The specimen has been mounted dry.

Presented by Dr. Mütter.

2083- 1754 107 6

Aneurism of the descending aorta; erosion of vertebrae.

The vessels ~~is~~ are of ab. normally ~~of~~ small size. A dilatation of the aorta is seen in the descending portion, increasing the diamater from 1.3 cm. to 3cm. Opposite the fifth dorsal vertebrae, the posterior wall of the aneurism ruptured, probably a considerable time previous to death, Through this opening may be seen a cavity in which may be seen and felt the carious bodies of at least the third, fourth, fifth, and sixth vertebrae. This cavity extends laterally a distance of about 7cm. on either side of the spine formed posterior to the costal pleura, eroding the ribs near their articulations.

The specimen has been mounted dry,

Presented.

2084- 1755 108 6

Aneurism of the abdominal aorta.

The anemrismal sac is about 10 cm, in diameter. Its lower extremity is 8 cm. from the bifurcation of the iliacs, No clots are seen.

Presented by Dr. Mütter.

2084.10 & ~~2101~~- 1745 107 5

Aneurism of abdominal aorta; communication with the colon.

The dilatation begins a little below the ~~coliac~~ coeliac axis. The diameter is about 10cm. A firm laminated clot of long standing is seen in the sac. At the lower portion of the sac a stick has been passed, through an opening in the aneurism, into the bowel. The aorta is seen to be intact for the space of 5 cm. above the bifurcation of the iliacs. The pendulous tumor of the aneurism was thus not in the direct channel for the blood. The bowel has been distended and is seen adherent to the aneurism.

Presented.

2084.20- 1763 110 1

Multiple aneurism of the aorta.

The specimen consists of the vertebral column, pelvis and ribs with all the larger vessels. Two aneurisms are seen; one involves the entire ascending aorta; the other the abdominal aorta. The heart itself is small; the ascending aorta is dilated into a sac measuring 11 cm. vertically and 9 cm. laterally. This large tumor must have produced the greatest distress and deformity. The transverse and descending portions of the arch are of irregular calibre; several distinct points of constriction are apparent from dilatation of the intervening portion of the vessel. The abdominal aneurism commences at the middle of the body of the seventh dorsal and reaches to the middle of the body of the twelfth.

Its lateral diameter is 12 cm. There is no point of rupture apparent. The remainder of the aorta is dilated, but as it approaches its bifurcation, gradually assumes its proper diameter.

The vertebrae in their posterior aspect are normal. The arterial distribution is also normal. The pelvis is apparently that of a male.

Presented by Dr. Mütter.

2086-
1759
109

Aneurism of the carotid artery.

The aneurism occurred at the point of bifurcation into the external and internal branches. The sac is 8 cm. long and 4 cm. wide. The cavity is large and the walls thick and rugous.

From a man aged 25 years. Aneurism of non traumatic origin. After attempted cure by digital compression the common carotid artery was tied with catgut carbolized. Everything went well for three months, when secondary hemorrhage occurred from the mouth and the carotid was ligated again in the cicatricial tissue. The pneumo gastric nerve was accidentally included in the ligature. Death from pneumonia occurred within three or four days.

Presented by Dr. John Ashhurst, Jr

2089-
1760
109
1

Aneurism of a minute cerebral artery.

The aneurism is fusiform, having a length of 5 mm. The sac has been opened, revealing a small firm clot. A portion of the brain depending on this vessel for blood supply has been preserved; it is in a state of softening.

Presented by Dr. Wm. Pe[illegible]

2150 see Vol I page 1695
~~2094.~~ To Section of Internal Saphenous
2846 vein. Removed May 1896.
108
3 Pres. by Mr. W. S. Rodman.

2093- Portion of the popliteal and tibial arteries; aneurism of the posterior tibial. Femoral artery tied by Bransby Cooper.
1761
109
1

The aneurismal sac is situated with its long diameter, 7 cm., oblique. Its short diameter is about 5 cm. A laminated clot occupies the upper portion of the sides of the sac. The aneurism begins about 3 cm. from the bifurcation of the popliteal in the branches of which, below the aneurism, a firm cylindrical clot is seen. The popliteal contains no clot.

Presented by Dr. Mütter.

2031.15 see vol I page 1657
~~2094-~~ Aneurism and clot; cross-section.
1762
109
1

The cross-section is nearly 1cm. thick and embraces the aneurismal wall with a laminated clot partly filling the contained space. The greatest diameter of this cross-section is 8.5 cm.

Presented by Dr. Mütter.

2031.20 see Vol I page 1657
~~2094.05-~~ Aneurismal clot.
1764
111
1

The specimen consists of an aneurism firmly coagulated. Two ribs are attached.

Presented.

A series of sections, Aneurism of the ascending aorta and femoral artery prepared by Dr. Henry D. Schmidt of New Orleans.

Case 36 Sheet 1
2095- Horizontal section of a sacciform aneurism of the

ascending aorta.

The section has been made immediately above the middle of its clot near the termination of the cavity.

The aneurism occurred between the heart and innominate artery. The tumor was almost globular in shape and anteriorly in contact with the sternum and portions of the right first and second ribs to which it was so firmly attached as to require a knife for its separation. The sac of the aneurism represented a dilatation of the wall of the aorta in which all the coats (omit this (error) of the allet) appeared to be preserved. The tumor, therefore, presented all the characters of true aneurism, with the sole exception of that part attached to the sternum and ribs. Here a considerable portion of the sac had disappeared by the pressure exerted upon the bones in consequence of which, the clot of the aneurism rested in contact with the latter, while the margin of the sac around the orifice was intimately blended with the periosteum.

(Fig.3.Annals Anat.&Surg. Brooklyn No.4.Monroses. Vol.Vll No.1.Jan.1883.)

The tumor was hardened in Mütter's fluid and transverse sections made of the upper portion. The more recently formed portion of the clot is easily distinguished from the older one. Hardened blood either in the form of strata atrata of alternating with strata of fibrin or in the form of masses, forms the central portion of the clot surrounded by the more recent fibrinous deposits.

The diameter of this cross-section is 7.8 cm. The channel for the blood current is triangular, situated

ute

near the centre and has a greatest diamater of 1.5cm.

See Annals of Anatomy and Surgery, Brooklyn, N.Y. Jan. 1883.

Purchased.

These sections in Case 36 shelf 1

2095.05
2095.10
2095.15- Horizontal sections of the same aneurism made successively upward; showing entire obliteration of the channel.

Purchased.

Case 36 shelf 1

2095.20- Vertical antero-posterior section of the lower half of the same aneurism.

This shows well the wall of the sac, the most recently formed portion of the clot and the older portion of the clot. The cavity is very irregular in shape, owing to the most recently formed portion of the clot projecting into it. The deficient margin of the sac is seen through which the clot came in contact with the ribs.

See Annals of Anatomy and Surgery, Jan. 1883.

Purchased.

Section in case on display.

Wet specimen bearing this same number, destroyed because it could not be identified 1/24/1941

Case 36 shelf 1 -

2095.25- Section of the clot of a sacciform aneurism of the femoral artery.

The section shows a stratified clot after removal from the sac.

Purchased.

For microscopic sections of aneurism, see page

2095.25 (above) on display but a duplicate no. - 2095.25 covering a wet specimen was also shown but as this wet specimen bearing this number could not be identified was destroyed 1/24/1941 by order of the Matter Committee - Dr. Schauer.

2095.30- Organized coagulum from the sac of an aneurism.

1765
111
1

Presented by Dr. Mütter.

2101 See 2084.10X only one specimen, same number 2084.10

2103- Thrombosis of the profunda artery.

missing

From a female aged 48 years. After an unusual muscular effort, while being in sound health--a fleshy woman--, she felt something sounding in her head "as if a gong were being struck there." She lost power over her limbs and vomited continuously. Dizziness, retching, and flushing of the face were present on the following day. Heart apparently normal. On the third day, pain of the most excruciating character was developed in the whole right lower extremity. Sense of the limb being on fire and cramp. No pulsation could be detected in any artery of the limb. The skin was colder than on the opposite side. Discoloration took place, growing to blackness at death, which occurred on the seventh day.

Trans.Coll.Phys.Phila. Vol 1V.N.S.p.262.

Presented by Dr.W.F.Atlee.

2105- Portion of lung. Pulmonary apoplexy.

1766
111
1

The color is indian red; the tissue is firm and heavy.

Removed from an old man who died after over-exertion.

Presented by Dr.J.C.Morris.

2162. see vol I page 1694

~~2112.~~ Haemorrhoids removed at various times.

1770
109
2

Presented by Dr. Mütter.

2150 see Vol I page 1686.
2846

2153. Femoral vein 12th day after Ligature
Presented by Dr. H.R. Wharton.
1771
109

2162 --- see vol I page 1693

This specimen destroyed because it cannot be identified.
Auth. Mütter Committee - Jan. 24, 1941 - Dr. J. Parsons Schaffer - Dr. Philip Custer
Dr. Alma C. McQuinness.
2200
1767
111
1
Destroyed.
1695

LYMPHATIC SYSTEM ILLUSTRATED BY MERCURIAL INJECTION IN VERY YOUNG CHILDREN.

2201- Lymphatics of the scalp and superior portion of the neck. Purchased - Prof. Sappey - Paris 1867

2202.00- Lymphatics of the scalp more complete than in the preceding. Purchased - Prof. Sappey - Paris 1867

2203- Lymphatics of the scalp, the face, the ear; very complete. Purchased - Prof. Sappey - Paris 1867

2204- Lymphatics of the scalp.
Purchased - Prof. Sappey - Paris 1867

Lymphatics of the
2205- Origin of the vessels of the scalp.
Purchased - Prof. Sappey - Paris 1867

2206- Lymphatics of the dorsum of the tongue and fauces and epiglotis and aryteno-epiglottideau fold; from a woman aged 35 years. Purchased - Prof. Sappey - Paris 1867

2207- The same; from a young child.
Purchased - Prof. Sappey - Paris 1867

2208- Lymphatics of the lower side of the tongue and larynx. Purchased - Prof. Sappey - Paris 1867

2209- Lymphatics of the tongue and ~~had~~ hard palate.
Purchased - Prof. Sappey - Paris 1867

2210- Lymphatics of the ear.

2211- Lymphatics of the tongue, fauces dissected
Purchased - Prof. Sappey - Paris.

2212- Lymphatics of the ear.
Purchased, Prof. Sappey - Paris 1867

2213- Lymphatics of the lips.

Two trunks spring from each lip. The right trunk of the upper lip is injected only at its origin.
Purchased - Prof. Sappey - Paris 1867

2214- Lymphatics of the nasal cavities and of the ear.

Three trunks arise from the net work of the meatus and empty into a ganglion situated behind the hyoid bone; two others arise from the posterior nares.
Purchased - Prof. Sappey - Paris 1867

2215- Origin of the Lymphatic vessels of the nasal chambers.

The minute trunks arise from the middle and inferior meatus and turbinated bones and empty into a vertical trunk. The latter has been accidentally cut.
Purchased - Prof. Sappey - Paris 1867

2216- Canal of Fontana.
Purchased - Prof. Sappey - Paris 1867

2217- Lymphatics of the hand.
Purchased - Prof. Sappey - Paris 1867

2218- Lymphatics of the foot.
Purchased - Prof. Sappey - Paris 1867

2219- Lymphatics of the bladder. Purchased - Prof. Sappey - Paris 1867

2219.05 —— Vertebrae Column of man. - Purchased - Prof. Sappey - Paris 1867

1068.10 see Vol I page 308 - This number shows a specimen

~~2220-~~ Hand; showing the arterial venous and nervous distribution.
1768
111
/

2221- The lower extremity. Missing

The preparation has been carefully dissected [illegible]

The arterial, venous, and nervous supply is well shown. A section has been made so as to show the cavities of the bladder and rectum; the penis is injected; the ureter is also seen.

Lymphatics of -

2221.05- Thoracic duct and vertebrae column of man.
Purchased - Tramond - Paris 1889

2222- Lymphatics of penis and scrotum and groin.
Purchased - Tramond - Paris 1889

2223- Lymphatics of external female genital.
Purchased from Tramond - Paris 1889

2224- Lymphatics of foot of man.
Purchased - Tramond - 1889

2225- Lymphatics of vomer of a horse.
Purchased of Tramond, Paris 1889

2226- Lymphatics of superior maxilla and nasal chamber of a horse.
Purchased - Tramond, Paris 1889

2227- Lymphatics of diaphragm of a horse.
Purchased from Tramond - Paris - 1889

Specimens 2221 and 2227 were purchased of Tramond in Paris 1889.

RESPIRATORY SYSTEM.

2404
2642

2413 2 missing Tumor of Pharynx
1772
109
2

Pres by Dr J Solis Cohen

2404.05 Post nasal Polyp
1773
109
2

Pres by Dr J Solis Cohen

2417 Round cell Sarcoma of Tonsil
1774
109
2

Pres by Dr J B Roberts

2417.05 Sarcoma of Tonsil
1775
109
2

Pres by Dr J Solis Cohen

These lymphatic injections (2201 to 2220 inclusive) seem to have been purchased from Prof. Sappey of Paris (vid. Account Book May 1867 Minute Book Mar. 5 & 22 1866 and Jan. 7 1867 pp. 8 & 9.

p. 1703 a

2404- Large nasal polypus.
1769
111

The polypus has a long diameter of 7 cm.

Presented by Dr. Mütter.

2407- Tongue, tonsils and epiglottis; gangrenous ulceration.
1776
109
2

There is gangrenous ulceration of the root of the tongue, embracing the epiglottis and tonsils; the parts are dark and ragged.

From a patient in the Philadelphia Hospital; a female who had secondary pneumonia of the base of the right lung.

2503 ~~2516~~ Larynx; circumscribed epithelioma; tracheotomy.
1777
109
2

The destruction is most marked on the left side of the larynx. The whole of the aryteno-epiglottic fold and its constituents down to the lower border forming the ventricular band (false vocal cord) of that side, is destroyed, exposing the sac of Hilton from above and leaving the ventricle and ventricular band intact. The Stump of epiglottis, which is the only portion of that structure remaining, appears not to have been involved in the morbid growth, but there are tracks of ulceration extending completely around it. The remaining portion of the larynx, the tongue, palative arches, and oesophagus appear to be free from the disease. There were two lymphatic glands, lying in the line of the carotid artery of the left side, at the level of the larynx, which

wereen

were enlarged. On section they showed cheesy degeneration in nearly their whole extent. Microscopic examination by Dr. Morris Longstreth showed abundance of oil drops, lymphatic cells, highly granulated and fatty and also some crystals of cholesterine. There were also seen numerous large flat cells, containing a single large granular nucleus. There was no microscopic evidence of an extension of malignant disease to the glands or to the surrounding tissue.

The Committee on Morbid Growths of the Philadelphia Pathological Society reported, Jan. 10th, 1878, "pegs formed of epithelial cells penetrating into the submucous tissue. Here and there some of the cells forming the cells are arranged concentrically, constituting the so-called pearly bodies. We, therefore, find an infiltration of the submucous tissue by an epitheliomatous growth."

From a lady aged 50 years. Fifteen months before death she had bronchitis and an oedematous epiglottis. Five months later, she was garroted by a burglar; a few months later, laryngoscopic examination revealed a fungous looking mass involving the free portion of the epiglottis and the left aryteno-epiglottic fold.

The epiglottis was removed; nutrient enemata were required to sustain life. Five months before death, tracheotomy was performed; breathing became easier, but swallowing was more difficult. Death ensued from exhaustian.

Trans. Path. Soc. Phila. Dec. 27th, 1877.

Presented by Dr. J. Solis-Cohen.

1078.10 see Vo
~~2503.40~~ Larynx
1783
110
2
~~Pres by Dr J Solis Cohen~~
See Vol. 1- Page 309

1707

2503.05- Tumor of the larynx and thyroid gland.
1778
110
2

The specimen comprises the larynx, trachea, and thyroid. The latter is the chief seat of disease.

Presented by

2503.06 *Tracheotomy* Presented by Dr Drysdale.
1779
110
2

2503.10
~~2503-~~ Larynx and trachea; tracheotomy for stricture of
1780 the larynx; tuberculous laryngitis.
110
2

Presented by Dr. J. Solis-Cohen.

2503.20- Larynx; Laryngotomy for syphilitic stricture, The
1781 mucous membrane is extensively destroyed. Laryngotomy
110 was performed five months before death; the opening is
2 1 cm. in length.

Presented by Dr. J. Solis-Cohen.

2504- Foreign body in the trachea of a child.
1784
110
2

A coffee bean is seen on the right side of the trachea immediately below the thyroid cartilage.

Presented by Dr. Mütter.

2501. see vol I page 1709

2503/30- Larynx. Tracheotomy.
1782
110
2

Presented by Dr. Cohen.

2504.10- Foreign body at the bifurcation of the trachea.
1785
110
2

The body is about the size of a coffee bean and is situated just to the right of the bifurcation.

From a child aged 3 years.

Presented.

n.

ncis G.Smith.

te ossifica-

ncis G.Smith.

ation; caries.

rt of the

t side a

ricoid carti-

ancis G.Smith.

agus; abscess-

us; oedema of

tter.

and opened

tter.

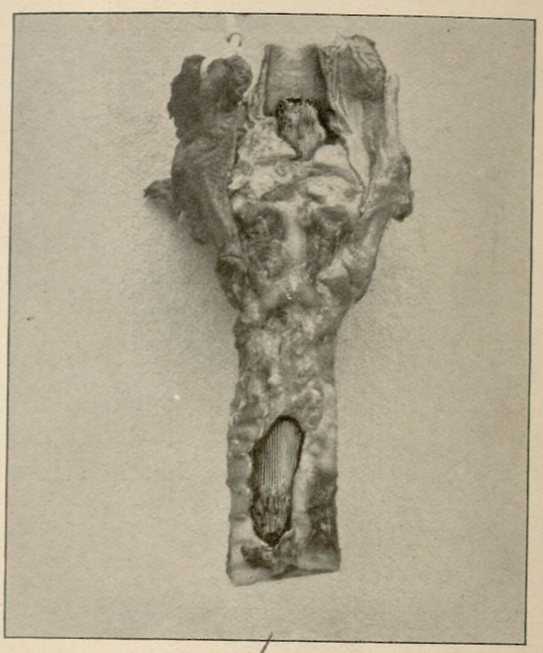

1786 2504.20 Foreign body (pencil)
110
2 in the trachea. Death from suffocation.
See Trans. Coll. Phys. 1896. Reported
and presented by Dr Guy Hinsdale.

2501. see Vol I. Page 1707

~~2506.10~~- Larynx; false membrane.

1791
111
2 A thick, tough membrane invests the larynx reaching from the epiglottis to the middle of the trachea.

From a child.

Presented by Dr. Mütter.

missing

2505- Larynx and trachea;partial ossification.

1787
110
2

Presented by Dr.Francis G.Smith.

2505.10- Thyroid and cricoid cartilages; complete ossification.

1788
110
2

Presented byDr.Francis G.Smith.

missing

2505-20- Thyroid and cricoid cartilages;ossification; caries.

~~1788~~
110
2

The anterior portion of the entire upper part of the thyroid cartilage is carious and on the left side a large amount of tissue is destroyed. The cricoid cartilage is thickened but not carious.

Presented by Dr.Francis G.Smith.

2506- Larynx,trachea,bronchi,lung,and oesophagus;abscesses of the trachea opening into the oesophagus;oedema of the glottis.

~~1787~~ 1789
111
2

Presented by Dr. Mütter.

2506.05- Larynx;abscesses.

1790
111
2

Abscesses formed in the surrounding tissue and opened just above the vocal cords.

Presented by Dr. Mütter.

2501 see Vol I. Page 1707

~~2506.10~~- Larynx;false membrane.

1791
111
2

A thick,tough membrane invests the larynx reaching from the epiglottis to the middle of the trachea.

From a child.

Presented by Dr. Mütter.

2506.10 Trachea and larynx.
Mucosa uniformly covered by heavy dirty brown exudate.
Death from mustard gas pneumonia after 5 days.
Pte. C.J. 203171. 1/4 K.O.Y.L.I. Gassed 22/7/17.
Usual appearance of severe gassing. At autopsy, general active congestion of lungs and broncho-pneumonia, with acute inflammation of entire respiratory tract. Fatty liver, acute splenic tumor.

Medical officer W.B. Cadwalader. Pathologist E.B. Krumbhaar.

Presented by U.S. Base Hospital No. 10.

2506.15 Larynx, trachea and roots of bronchi.
The main bronchus to the right lung has been dissected out to show the cast-like exudate. The root of the left lung shows similar exudate in the bronchus with peribronchial consolidation. Notice the exfoliation of the membrane in the trachea and the main bronchi.
Death from gassing after 3 days.
Bdr. J.D. 102817. 219 So. R.G.A. Gas (mixed?)
11/5/18. Cyanosis and dyspnea. Emphysema, no broncho-pneumonia.

Medical officer R. Beebe. Pathologist E.B. Krumbaar.

Presented by U.S. Base Hospital No. 10.

2507- Larynx; oedema following gunshot wound.
1793
111
2
The parts are greatly tumefied. At the post mortem examination the ball was found between the bodies of the second and third dorsal vertebrae.

Presented by Dr. J. Solis-Cohen.

2508- Larynx and trachea; "diphtheritic membrane of croup."
1794
111
2
The membrane is seen in the larynx, at the base of the epiglottis and extending half way down the trachea.

Presented by Dr. Mütter.

2509- Larynx and trachea; ulceration.
1797
109
3
The mucous membrane of the larynx shows deep ulcers involving the vocal cords. The mucous membrane of the trachea is superficially destroyed.

Presented by Dr. Mütter.

2509.10- Ulceration of the larynx and epiglottis.
1798
109
3
Presented by Dr. Mütter.

2509.20- Larynx; ulceration.
1799
109
3
The vocal cords and the mucous membrane at the base of the epiglottis are ulcerated.

From the Philadelphia Hospital.

2509.30- Larynx; ulceration.
1800
109
3
There is a large excavation in the left ventricle of the larynx

Presented by Dr. J. Solis Cohen.

1801
109
3

2509.31 Larynx; Ulceration

2509.32 Larynx Ulceration Glass tube at site of tracheotomy

Presented by Dr.J. Solis-Cohen.

1802
110
3

2509.40- Larynx and portion of the trachea;ulceration of the tracheal rings;laryngitis.

1803
110
3

Presented by Dr.W.L.Atlee.

2509.50- Larynx;ulceration.

1804
110
3

Presented by Dr. Mütter.

2509.60- Larynx; Tubercular ulceration. Extensive.

1805
110
3

Presented by Dr.R.M.Bertolet.

2509.70- Larynx; Tubercular ulceration.

1806
110
3

There is an abscess cavity 1.5 cm. in diameter posterior to the right vocal cord.

Presented by Dr.R.M. Bertolet.

2509.80- Larynx. Tubercular ulceration.

1807
110
3

Presented by Dr. J.Solis-Cohen.

2519.30 See Vol. I page 1717.

~~2509.90~~ Larynx and Tongue. Primary tuberculosis of Larynx
1814
109-4 Arch. of Laryngology Vol II No 2. April-1881. Pres. by Dr J.S. Cohen.

2510- Larynx and trachea;syphilitic ulceration.

1808
110
3

The right vocal cord is th seat of ulceration.

Presented by Dr.J.Solis-Cohen.

2510.10- Larynx;syphilitic ulceration of the larynx.

1809
111
3

Presented by Dr.J.Solis-Cohen.

2511- Larynx and trachea;extensive tubercular ulceration

1810
111
3

of the former, necrosis of the right arytenoid cartilage and multiple enchondromata of the tracheal rings.

When recently examined, the arytenoid cartilage was seen necrosed and denuded but firmly attached at its articulating surface which had not apparently undergone any change; the vocal cord of that side and the posterior portion of the ventricular band had become obliterated by ulceration; and there was ulceration of the epiglottis on the same side. The trachea was intensely congested but the mucous membrane intact, save here and there evidences of the ulceration of a few glands. There was an irregular arrangement of hard nodules sprinkled over the anterior surface of the trachea, of cartilaginous or even bony consistence to the touch. The lungs were disorganized and studded with small abscesses.

The cartilaginous tumors showed under the microscope the presence of hyaline cartilage, with interspersed points of ossification. These small outgrowths are mostly seated upon the centre of the tracheal rings.

From a man aged 40 years who had pain in the larynx followed by hoarseness; later swelling of the arytenoid cartilage and abscess. Death occurred from broncho-pneumonia.

Trans. Path. Soc. Phila. Oct. 24th, 1872.

Presented by Dr. J. Solis-Cohen.

2511.10- IX
1811
111
3

Larynx and trachea; tubercular ulceration.

Superficial ulceration of the larynx and upper po
of the trachea.

Presented by . J
ed by . Mütte

1716

95.20 Primary Tuberculosis of the Larynx
1814
111
3
Pres by D J Solis Cohen

95.20.10 Tuberculosis of Larynx
1815
111
3
Pres by D J Solis Cohen

95.31.05 Cancer of Larynx
Vol 1- Pg. 1718
1819
109
4
Pres by D. Drysdale

2511.40 Tuberculosis of the larynx
Presented by Dr. Guy Hinsdale.

2620.00 Lung and shell fragment.
Completely collapsed. Section in one plane of the foreign body shows a small cavity surrounded by a large area of consolidation, markedly hemorrhagic toward its Periphera. Pleura is extensively thickened. Shell fragment encapsulated and not contributing to death. Death from head injury after 14 days.
Pte. W.M. 259. 38 Aust.D.Co. Wounded 14/6/17.
Multiple bomb wound. Severe bronchitis and hemoptysis which ceased after several days with return of temperature to normal. Right facial and hypoglossal palsy with fracture of base and destruction of Brain tissue. Foreign body lodged between thyroid and mastoid processes.

Surgeon Major Mackie, C.A.M.C. Pathologist E.B. Krumbhaar
Presented by U.S. Base Hospital No. 10.

deaccessioned gm

2621.00 Lung. Left apex.
Apex transfixed by fragment of rib, driven in by missile which entered left shoulder, traversed both sides of thoracic cavity and lodged in right posterior axillary fold. Note slight amount of adjacent hemorrhage and consolidation.
Death from pyo-pneumothorax after 17 days.
R.fm. J.H. 5390. B. Rifle Btn. Wounded 25/10/18. Penetrating gunshot wound of shoulder. Collapse of right lung with pneumothorax and gas bacillus infection.
Surgeon R. Beebe. Pathologist E.B. Krumbhaar.
Presented by U.S. Base Hospital No.10.

2511.20- Larynx; follicular ulceration.
1812
111
3
From a case of acute tuberculosis.

Presented by Dr. J. Solis-Cohen.

2511.30 see vol I page 1713

2513- Necrosis of laryngeal cartilage. Sequestrum.
1813
111
3
Presented by Dr. J. Solis-Cohen.

2531- Eucephaloid cancer of the tongue and larynx.
1818
109
4
From a man aged 80 years.

Presented by Dr. J. Solis-Cohen.

2516. ~~2534-~~ Tumors of the larynx and pharynx.
1820
109-4
2516.05 ~~2534.10-~~ Larynx; tumors.
1821
109
4
The larynx is from a child; two tumors of the size of small peas are seen, one on either side, just below the vocal cords.

Presented by Dr. S. Weir Mitchell.

2550- Portion of the trachea and bronchi; enlarged bronchial glands.
1822
110
4

Presented by Dr. Mütter.

2605- Lung and fractured ribs; pleuritic adhesions at the point of fracture.
1792
111
2
From the Philadelphia Hospital.

2628- Anthracosis of the lung.
1823
110
4
From a coal miner.

Presented by Dr. Mütter

Pg. 1716- Vol. 1

2531.05 Cancer of the Larynx Presented by Dr Dixon

2623.00 Lung. Left apex.

Focal broncho-pneumonia limited to apex. The dark gray area at the bottom is relatively normal, the whitish patch at the top resembles gray hepatization.

Death from mustard gas pneumonia after 12 days.
Pt. J. M. 20013. 2/4 L. W. Lance. Gassed 12/5/18.
Usual signs and symptoms of mustard gas poisoning.
Developed congestion and edema of lungs.

Medical officer T. Farrell. Pathologist E. B. Krumbhaar
Presented by U. S. Base Hospital No. 10

2623.05 Lung

At autopsy a focal reddish purple peribronchitis was beautifully shown especially in the lower lobe. This now appears as numerous irregular gray spots. A small calcified nobule occurs near the inferior border. ~~The grayish incomplete fixation~~. Notice the exudate on the diaphragmatic pleura and in the bronchi.

Death from effects of gas after 8 days.
Pte. R. C. S. 260373. Gassed (Yellow Cross)
15/8/18. Dangerously ill on admission to base.

Medical officer A. Gerhard. Pathologist E. B. Krumbhaar
Presented by U. S. Base Hospital No. 10

2623.10 Lung.

In the lower lobe a large granular confluent area of broncho-pneumonia. In the upper lobe several raised pinkish foci of broncho-pneumonia are well shown with brown discoloration of the pleura due to faulty preparation.

Death from pneumonia after 11 days.
F. J. W. 353081 7 London. Gassed (Yellow Cross)
17/4/18. Usual signs and symptoms. Ten days later suddenly worse.

Medical officer J. P. Austin. Pathologist E. B. Krumbhaar
Presented by U. S. Base Hospital No. 10

2633- 1824 110 4 Lung; tubercle.

The lung is riddled with small abscess cavities.

Presented by

2633.10- 1825 110 4 Lung; tubercle. deaccessioned gm

Presented by Dr. Mütter.

2633.20- 1826 110 4 Lungs; degenerated tubercle; from a case of fibroid thickening of the stomach.

Adhesions existed at the top and upper third of the right lung. No tubercle at the apex but elsewhere in the pleura and in the substance of the lung were hard white bodies of the size of shot; these were found, on microscopic examination, to be made up of an outside circular ring of connective tissue with a large deposit of pigment in it. The contents of this ring of connective tissue were hard, gritty and friable; did not effervesce on the addition of hydrochloric, nitric or acetic acid, nor was it soluble in these acids. It was probably a degenerated tubercle.

See D 17. Also Trans. Path. Soc. Phila. Vol. III p. 11

2636- 1827 110 4 Lung with a large cavity; from a case of phthisis.

Presented by Dr. John H. Packard.

2636.10- 1828 110 4 Lung with pulmonary cavity. The trachea and bronchi are shown.

2638- 1829 111 4 Melanosis of the lung. deaccessioned gm

The portion of the lung preserved shows numerous rounded eminences of a nearly black color, varying in size from 3 to 5 cm. in diamater.

Presented by Dr. Henry Bond.

2642- Lung; cancer.
1830
111
4

Presented by Dr. W. Pepper, Sr.

2725- Cancer of the diaphragm.
1831
111
4

Presented by Dr. Wm. Pepper, Sr.

DIGESTIVE SYSTEM.

3005
to
3601

3900.05 see Vol I page 1805
~~3003.~~ Right and Middle Lobes of
2852 the Thyroid Gland. Removed
117. from Miss Eberling at the
2 Polyclinic Hospital.
Pres. by Mr. John B. Roberts.
1. 11. 1901.

3900.10 see Vol I page 1805
~~3004.~~ Goitre, Cyst and Contents.
2853 Pres. by Mr. W. H. Rodman.
117.
2

3005- Oesophagus; rupture.
1832
109
5

There is a small opening admitting a probe 3 mm. in diameter, situated in the oesophagus at the level of the cricoid cartilage.

An ulcer having been produced during dilatation of a stricture by the patient, rupture occurred and death was caused by air entering the mediastinum.

Presented by Dr. J. Solis-Cohen.

3016- Oesophagus; cancer.
1833
109
5

The cancer is situated at the level of the arch of the aorta which, together with the larynx and trachea are embraced in the specimen. The mucous membrane of the oesophagus is shaggy, and full of pockets for the space of 10cm. in vertical extent.

From an officer in the U.S.A.

There was great dysphonia due to paralysis of the left vocal cord from pressure upon the left recurrent laryngeal nerve.

Presented by Dr. J. Solis-Cohen.

3016.05- Oesophagus; cancer.
1834
109
5

The cancer is seated at the level of the thyroid gland and about the opening of the larynx. The oesophagus was very much constricted by the growth.

Presented.

3037 Stomach and Intestine. Gastroenterostomy. Presented by Dr. J. B. Roberts.
1843

3039- Stomach; poisoning by corrosive sublimate.
1835
109
5

3054.00 IX

Stomach and duodenum

Petechial hemorrhages on the ruga of the stomach, especially on cardiac path. Hemorrhages less marked in duodenum. These and the milky white appearance of the esophagus have partly disappeared in preparation.

Death from broncho-pneumonia, after 7 days.

Pte. F.G. Btn R.N.G. Hawke. Gassed (Yellow cross)

12/3/18. Leukocytosis changing to leukopenia

Medical Officer W. Drayton. Pathologist E.B. Krumbhaar

Presented by U.S. Base Hospital No.10.

The mucous membrane is generally blackened, thrown into folds.

Presented by Dr. Mütter.

3052- IX

1836
110
5

Stomach; saculated.

There are saculations capable of receiving a pullet's egg.

Presented by Dr. Mütter.

3056 ~~3069.30~~- IX

1851
117
1

Stomach; hypertrophy and carcinoma.

The stomach when recently removed, was small, very hard to the touch, and externally felt rough. On opening it, nearly the whole internal surface, but more especially the posterior wall, about its middle, was found covered with masses of hard elevated nodules, grayish-red or black on their tops, with diffuse inflammation surrounding the base of each. Among these were some softer than others and in some the most elevated portion was ulcerated. The walls of the organ are very hard and firm. The pyloric orifice does not appear closed at all, but there is a slightly increased induration about it from which the disease may have taken its origin. The growth had all the gross appearances of encephaloid.

Microscopic sections across the wall of the stomach show an active proliferation of the epithelium of the mucous membrane, pushing its way into the wall, infiltrating it and forming alveolar spaces, thewall is further infiltrated with young cells, which for the most part, replace

the normal structure of the part.

The process has probably been a chronic catarrh with great hypertrophy, passing gradually into a carcinomatous type.

Sections of the omental nodules show an indistinct alveolar structure filled with epithelial cells and a small celled infiltration of the adipose tissue. The appearances are those of a carcinoma secondary probably to the growth in the stomach.

The omentum was found very hard, much thickened, and quite white, and covered with small pale yellow nodules closely packed together; the whole was tightly adherent to the neighboring structures, so that to move it moved both stomach and intestines. The liver was small and pale, but of natural consistence and appearance on section. The gall-bladder was firmly fastened by adhesions to the liver and to the intestines. Both kidneys were small, very little congested, the capsules easily stripped off, and except that in each were one or two small cysts filled with clear watery fluid, showed no signs of disease. The abdominal cavity contained about sixteen pints of clear yellow fluid. The heart was small, its cavities were filled with little red and white clots, and the valves were all perfectly competent. The lungs were much congested at the bases, and somewhat compressed by the abdominal distension, but had no other evidence of disease.

From J.M., an Irish teamster, aged 63, admitted to the Episcopal Hospital November 28th, 1884. His family history was good, and his own, except that he had always

been a drinking man, and had had lead-poisoning four

3058- Stomach; atrophy.
1837
110
J

The capacity of this stomach is small; the walls are apparently not thickened or otherwise diseased.

From a man aet. 39 years. Intense pain continually for three years; phthisis was the cause of death. The heart was exceedingly small and the stomach was capable of holding only two fluid ounces.

Presented by Dr. J. Solis-Cohen.

eter of about 4 cm. The mucous in this area ~~membrane~~ is destroyed.

Presented.

3059.05- Stomach; ulcer.
1839
110
J

The cavity is contracted. Adhesion with the pancreas prevented rupture at the point of ulceration. The course of the pancreatic duct is marked by a whalebone, which emerges in the duodenum.

Presented.

3059.10- Stomach wall;perforation.

1840
111
5

A small circular opening 5 mm. in diameter is seen in the wall.

Presented by Dr. Mütter.

3063- Stomach and portion of the colon;epithelioma; gestro-colic fistula.

1841
111
5

The pylorus is the seat of epithelioma;the colon has become adherent and involved in the disease. A communication exists between the two cavities, Adhesions to the parietal peritoneum had also taken place.

From a man aged 27,a driver by occupation. No history of syphilis or family history of cancer. The tumor was situated during life at the left of the umbilicus, was painful and entirely movable and apparently of the size of an orange. Cachexia,emaciation and constipation,and later vomiting,attended the growth of the tumor. Duration of the disease,ten months.

Boston.Med.&Surg.Jour.Apr.17th,1884. 110: 371

3065

Presented by Dr.John H.Packard.

D.23- Portion of a stomach;cancer. No history.

Presented by Dr.Isaac Parrish.

3067- Portion of the plyoric end of stomach;polypus.

1842
111
5

The polypus is about 1.5 cm,in diameter and is attached by a short,broad and thin pedicle to the mucous membrane.

From the Philadelphia Hospital.

1735

3069-
1846
117
1

Stomach; scirrhus cancer of the pylorus.

The tumor surrounds the pyloric orifice so far encroaching on its lumen as to have permitted the passage of the little finger only with extreme difficulty. The disease involves the mucous and sub-mucous layers of the stomach. Microscopic examination showed that the amount of dense white connective-tissue stroma strongly predominates over the cellular elements, which are of small size, yet having distinctly the epithelial type and generally arranged in long tubuli, as though they had originated in the ducts of the mucous glands.

The tumor was situated in the median line midway between the umbilicus and epigastrium.

From a man aged 72, whose illness was of six months duration. Nausea at firstlspasmodic abdominal pain during the last four months with pallor. One month before death the tumor was first detected, though looked for previously with care. Vomiting occasional. Anorexia. Death from exhaustion.

Trans.Path.Soc.Phila. Vol.IV p.88. Jul 21-1873

Presented by Dr.Jas.Tyson.

6470.74 See Vol. II - Page 416

~~3069.10-~~ cross index number. ~~Stomach; cancer of the pylorus.~~

1849
117
1

destroyed.
The stomach is of large size.

Presented by Dr. Mütter.

3069.11 Cancer of the Stomach Dr Gallaghan " " " Dr Dysdale

3069.12 " " " " " " "

3069.20- Stomach; cancer of the pylorus.

1850
117
1

The pyloric orifice is obstructed by a thick carcinoma-

tous growth. This condition was associated with cancer of the right lung and diaphragm.

From a female aged 51 years, whose death was preceded by oppression, prostration, emaciation, and oedema without cough or expectoration, solidification of the right lung supervening.

Presented by Dr. Wm. Pepper, Sr.

3069.40- Portion of a stomach; cancer.
1852
118
1

No history.

Presented by Dr. Isaac Parrish.

3069.50- Stomach; cancer.
1853
118
1

Occlusion of the pylorus.

Presented by Dr. L. M. McGuire.

3069.51 Cancer of Stomach " " Dyspepsia
1921
117

~~3069.55-~~ 3070. Stomach; colloid cancer.
1854
118
1

Presented by Dr. J. K. Mitchell.
From a patient at St. Agnes Hospital.

3069.56- Stomach; cancer.
1855
118
1

Presented.

3069.57 Stomach; cancer and dilatation.
1848
110
6

Presented by Dr John B. Roberts.

3072- Stomach; fibroid thickening.
1856
118
1

When freshly removed, the cardiac extremity of the walls of the stomach was somewhat thicker than usual and mobile. A microscopical section showed the glands considerably enlarged. The pyloric extremity

[Co. 1910]

p. 1739a

Dear Dr. Hoffman,
I would like to leave this specimen of Macro-stoma on deposit — with the possibilities of using it some times for teaching perhaps. The specimen has been injected and recently kept in weak formaldehyde. There are also a few pictures in this package for the Surgical Ass'n. Series

John B. Roberts

was about three or four times the normal thickness. A section here gave a large amount of fibrous stroma arranged in oval and circular meshes, containing masses of nuclei and cells; the latter were nearly all fragmentary. Thin walls were generally indistinct, their forms mostly round or if angular, it was apparently by reciprocal pressure. Some few were nucleated.

The lungs were tuberculous. The heart was small and apparently oedematous and contained cysts of gelatinoid matter. The visceral and free peritoneum was dotted with ulcers. One ulcer in the recto-vesical fold was covered with clots of blood; it was 6 cm. long and 1.2 cm. wide and had ragged edges.

From S.J., aged 65 years, a cabinet maker, The disease was of about two years duration and was accompanied with characteristic symptoms.

Trans. Path. Soc. Phila. Vol. III p. 9. - Sep 14-1866

Presented by Dr. S. Weir Mitchell.

3074-
1854
2

Congenitally imperforate duodenum; absence of the gall-bladder.

The specimen when recent was of a pearly white appearance; it extended across from side to side and deep down in the cavity of the abdomen, forming a double pouch of which the stomach contributed two-thirds and the greatly distended proximal portion of the duodenum, one-third. capacity, seven and half fluid

wound.

COLLEGE OF PHYSICIANS,

N. E. COR. THIRTEENTH AND LOCUST STREETS.

Philadelphia, ... *188*

Dear Doctor:

I enclose, with statement of amount due by you to the College of Physicians, of Phila., copy of Chap. 1, Sect. 18, of the Ordinances and By-Laws, viz:—

18. "No Fellow shall be permitted to vote at any election, whether of Officers, Fellows, Associate Fellows, or Corresponding Members, who has not signed the Ordinances and By-Laws, and paid the entrance fee, together with the contributions due by him."

Yours, truly,

C. S. WURTS, M. D.,

Treasurer.

Dr. .....

Please remit to the Treasurer, or to the Librarian, C. P. FISHER, at the College, between 10 A. M. and 2 P. M., 4 and 5 P. M.

1739

was about three or four times the normal thickness. A section here gave a large amount of fibrous stroma arranged in oval and circular meshes, containing masses of nuclei and cells; the latter were nearly all fragmentary. Thin walls were generally indistinct, their forms mostly round or if angular, it was apparently by reciprocal pressure. Some few were nucleated.

The lungs were tuberculous. The heart was small and apparently oedematous and contained cysts of gelatinoid matter. The visceral and free peritoneum was dotted with ulcers. One ulcer in the recto-vesical fold was covered with clots of blood; it was 6 cm. long and 1.2 cm. wide and had ragged edges.

From S.J., aged 65 years, a cabinet maker. The disease was of about two years duration and was accompanied with characteristic symptoms.

Trans. Path. Soc. Phila. Vol. III p. 9. - Sep 14-1866

Presented by Dr. S. Weir Mitchell.

3074-
1859
2

Congenitally imperforate duodenum; absence of the gall-bladder.

The specimen when recent was of a pearly white appearance; it extended across from side to side and deep down in the cavity of the abdomen, forming a double pouch of which the stomach contributed two-thirds and the greatly distended proximal portion of the duodenum, one-third. capacity, seven and half fluid

wound.

ounces. Examining the interior of the duodenal portion a papilla with a central depression is seen, situated posteriorly and the near the ~~loawr~~ lower end; there is no outlet. A thin strip of tissue has been left uniting the external face of this little eminence with a narrow blind pouch which was continuous with the jejunum. The latter and the remainder of the intestinal canal were contracted and presented nothing abnormal. The anus, vagina and urethra were pervious and well formed. On inspecting the liver, the depression between the right and square lobes was found to be without a gall-bladder, a thin cord of tissue, somewhat expanded anteriorly, occupied this position.

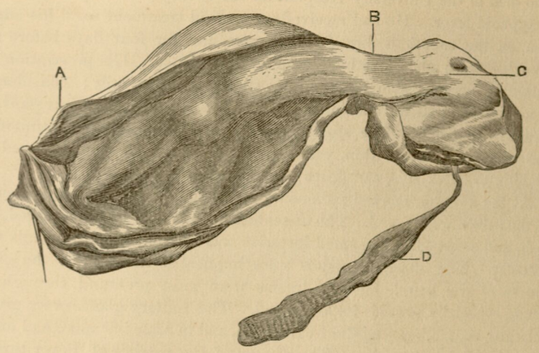

Fig. 2.

A. Stomach.
B. Pylorus.
C. Portion of duodenum above imperforation enormously dilated.
D. Small intestine.

omiting began
ss and later
e on the
o the end.

Trans.Path.Socy.Phila.Vol.V p.38. Sept 24-1874

3074.10 Imperforate Rectum — Presented by Dr.R.A.Cleemann.
1858 117 1 — " " " Drysdale

3075. ~~D.81~~- Rectum and anus; pouch of the rectum.
1869 117 3

Presented by Dr. Mütter.

1859-117 3075.50 Ileocecal Valve and appendix. Infantile normal
Presented by Dr. Hinsdale.

3076- Portion of intestine; gunshot wound.
1860 117 1

who died in the University Hospital on the twenty-third day of an attack of typhoid fever. He had received no medical treatment until his admission on the twentieth day of the disease, and for four days before that time had been almost without food or attendance. His prostration was extreme; nervous symptoms mild; slight eruption only; considerable bronchial congestion; abdomen distended and tender, and incessant colliquative diarrhœa. The stools ran away from him almost continuously, and were composed of thin, yellowish liquid. All treatment proved unavailing to check this, and death occurred from exhaustion.

At the *autopsy*, marked pulmonary congestion and decided enlargement of the spleen were found. The mesenteric glands very much enlarged, reddish, and softened. The small intestine was distended, and its walls were vascular. The intestinal glands were implicated throughout the entire course of the bowel, but the lesions were most profound through the ileum, especially towards its lower end. The solitary glands were greatly enlarged, containing semi-fluid exudation, and in some instances had undergone superficial ulceration. The disease of the patches of Peyer towards the lower end of the ileum was extraordinarily intense. The intestine presented for a distance of more than a foot, a mass of large, oval ulcers, almost confluent, with thick, rounded edges and irregular fungous surfaces.

September 24th, 1874.

ounces. Examining the interior of the duodenal portion a papilla with a central depression is seen, situated posteriorly and the near the ~~leawr~~ lower end; there is no outlet. A thin strip of tissue has been left uniting the external face of this little eminence with a narrow blind pouch which was continuous with the jejunum. The latter and the remainder of the intestinal canal were contracted and presented nothing abnormal. The anus, vagina and urethra were pervious and well formed. On inspecting the liver, the depression between the right and square lobes was found to be without a gall-bladder, a thin cord of tissue, somewhat expanded anteriorly, occupied this position.

From an infant who lived five days. Vomiting began on the first day accompanied by restlessness and later great agony. The child ceased to micturate on the second day but had motions of the bowels to the end.

Trans.Path.Socy.Phila.Vol.V p.38. Sept 24-1874

3074.10 Imperforate Rectum — Presented by Dr.R.A.Cleemann.
1858 117 1 — " " " Dr Syd Ree

3075. ~~P.81~~ - Rectum and anus; pouch of the rectum.
1869 117 3

Presented by Dr. Mütter.

1859.117 3075.50 Ileocecal Valve and appendix. Infantile normal
Presented by Dr. Hinsdale.

3076- Portion of intestine; gunshot wound.
1860 117 1

3076.3 Rupture of the Intestine
1870
117
3

Pres by D Drysdale

3076.05 Colon.
Several unplugged punctures with surrounding areas of hemorrhage.
Acute peritonitis with fecal matter in cavity.
Death from peritonitis in 2 days.
Gnr B.T. 179315 R.F.A. Wounded 21/3/18. Entrance wound just below umbilicus, exit posteriorally near crest of ileum. Much rigidity and distention.
Medical Officer C.F. Mitchell. Pathologist E.B. Krumbhaar.
Presented by U.S. Base Hospital No. 10.

A large opening 2 - 3 cm. is seen in the intestinal wall.

Presented by Dr. Mütter.

3076.10- Descending colon;rupture from external violence.
1871
117
3

A post-mortem examination of the body showed in the left lumbar and iliac regions discolored skin and extravasation of blood without tearing. Coagulated blood was found between the external and internal oblique muscles with more extensive bruising of the internal;the parietal layer of the peritoneum was separated by an effusion of blood;the whole abdominal cavity was filled with blood. The only injury discovered in the abdominal organs was the rupture of the colon about 6 or 8 cm.above the sigmoid flexure. A small lump of hardened feces was found in the abdomen near this rupture and a prune seed in the opening,several seeds were above and one or two below. There was no fracture of the pelvis.

From Chas.F.,aged 14 1/2 years,who fell down three stories in the hatchway of an elevator pulling a light cart after him. He sustained,beside the conditions noted above,contusion of the back and fracture of the right tibia and fibula. He died in two hours after admission to St.Mary's Hospital,having experienced great shock,the pulse having reached 160 and the temperature 97.5°;consciousness was preserved.

Mears Trans.Path.Soc.Phila.May 25 1882.

Presented by Dr.J.Ewing Mears.

117
3

Pres by D

1945

3077. 10 Intestinal Anastomosis, Lateral.
1862 Presented by Dr Roberts.
117
2

3077 Seven specimens illustrating intestinal
Anastomosis; from experiments on dogs.
1861
117
2 Presented by Dr J.M. Baldy.

3077.20 Proctectomy
1863 Pres by Dr J.B. Roberts
118
2

3077.30 End to end anastomosis (Dog)
1864
118
2 Pres by Dr J.M. Baldy

3077.40 Lateral anastomosis. Ileo-colic. Rings in place (Dog)
1865
118
2. Pres by Dr J.M. Baldy

3077.50 Resection of sigmoid flexure Cancer
1866
118
2 Pres by Dr J.B. Roberts

3077.60 Lateral Anastomosis showing inverted end
1867 early after the operation
118
2 Pres by Dr J.M. Baldy

3077.70 Lateral Anastomosis (Dog) Recovery
1868
118
2 Pres by Dr J.M. Baldy

3077.80 Artificial Anus.
1872
117
3 Pres by Dr Mitter

1747

Reprinted from
UNIVERSITY MEDICAL MAGAZINE
June, 1892.

1757

3084.

A CASE OF GIANT GROWTH OF THE COLON, CAUSING COPROSTASIS, OR HABITUAL CONSTIPATION.[1]

BY HENRY F. FORMAD, M.D.,

Demonstrator of Morbid Anatomy and Lecturer on Experimental Pathology at the University of Pennsylvania.

THE case to be recorded, and from which I present the specimens, is unique in the history of morbid anatomy. It represents a human colon of dimensions equal to that of a cow, and the accompanying illustration, which is a reproduction of a photograph, taken side by side and simultaneously with a normal human colon, will convey to those who did not see the specimen an adequate idea as to its size. (See Plate III.)

The exact measurements of the different parts of the bowel will be given hereinafter.

Definition. The specimen is one of *giant growth* of the colon, or a congenital anomaly belonging under the category of *monster per excessum,* followed by coprostasis or habitual constipation, which eventually terminated fatally in the adult. This case differs from all on record in the following points:

1. In that the enlargement or dilatation preceded and was the cause, and not the result, of coprostasis.
2. There was no acquired morbid change, such as colitis or obstruction of the bowel, that led to this condition.
3. The mode of death was not due to ulceration or perforation of the bowel, or to peritonitis, as in the cases on record.
4. The specimen exceeds in magnitude the few cases heretofore recorded.

History of the case. J. W., aged twenty-nine years, white, single, was found

[1] Read before the College of Physicians, Philadelphia, April 6, 1892.

...kard.
Presented by Dr. W. A. Edwards.
3077 45
1873 Circular Enterostomy.
117-3
3087- Mucous colitis. The mucous membrane is crowded
1874 in patches.
117 Case of Dr. Edward Parker.
3
Destroyed Jan. 24, 1941 because it could not be identified. Auth. Committee Drs. Schaeffer, Custer, McGuigan
3087.50 Specimen not labelled
1880
118
3
Pres by Dr. W. A. Edwards
Dr. McFarland Curator

dead in the water-closet on the premises of a society to which he belonged, and the case subsequently became subject to the investigation of the Coroner. Being delegated to make an autopsy and an investigation of this case, my inquiries revealed the following facts:

His mother tells that up to the age of one and a half years the subject under consideration was a normal infant, with the exception of a rather large abdomen, frequent irregularity of the bowels, and attacks of constipation, but no other deformity of the body had been noticed by her up to that time. Subsequently, and especially noticeable at the age of two years, the abdomen began to swell and the disturbances in defecation began to be more marked, so that constipation would last from two to four days as a rule. His appearance was said to be that of a marasmic child, lean and emaciated, and until five years of age he was unable to rise without assistance. Subsequently the bodily development was progressive, although he was rather spare. At the age of twelve years he was able to go to school, and although the history of his intellectual success as a schoolboy is uncertain, he appeared to have had the normal intelligence of lads of his age. At the age of sixteen years he earned his living at a foundry, for eighteen months, at continuous work. Subsequently he worked for several years as a laborer at an oil refinery, and while his work was uninterrupted during this period, his parents say that he was subject to habitual constipation, said to last as long as a whole month at a time, although no correct clinical data covering this period of his life could be obtained. Yet it was obvious that his abdomen continued to grow in size. At this period of his life, while not feeling distressed by any painful ailment, he is said to have visited the dispensaries of various hospitals of this city. At twenty years of age his abdomen had reached very large dimensions, and the figure of his body became so peculiar that the managers of the Ninth and Arch Streets Museum saw fit to put him on exhibition as a "freak;" and for eight or ten years he was known as the "Windbag" or "Balloon-man." It is said that the circumference of his body at this time was equal to his height, and that he was able to diminish or increase the circumference of his abdomen and chest at will to the extent of fourteen inches. He took particular delight in pounding himself upon the abdomen with his fist, and permitted spectators at the museum to do likewise. Eye-witnesses say that when his abdomen was thus pounded it resounded like a drum. It appears evident that his abdomen must have been larger at previous periods of his life than at the time of death. For about one year he ceased appearing as a museum freak and acted as a messenger for a market, being quite a well-known figure on the streets during the year previous to his death.

The whole history of his life and habits does not present anything peculiar, except that he had an enormous appetite and was generally a good feeder. He was known to relish a few extra heavy meals a day. He was occasionally of intemperate habits.

He applied lately to the Hahnemann Homœopathic Hospital, complaining of obstinate constipation of his bowels, general weakness, pain in the abdomen, shortness of breath, and great tympanites. He complained also of having a passage of his bowels only once every few weeks. He was admitted as a

patient under the care of Dr. Vischer, one of the attending surgeons of the hospital, being admitted to the surgical wards under the supposition that there was a large abdominal tumor or some obstruction of the bowels that had led to the enormous distention of the abdomen. He was etherized, and, to the credit of Dr. Vischer, it must be said that a simple enlargement of the colon, without any other complication or tumor formation, was made out. It is evident that the case was carefully studied by the physicians of the Hahnemann Hospital, and the two accompanying reproductions of the photographs—one showing the front and the other showing the side view of the patient—were obtained through the courtesy of Dr. Vischer. These photographs convey most excellent ideas of the physical condition of the patient, especially as they were taken within a short time of his death.

The patient was dismissed from the hospital, but frequented for some time the dispensary of the same, until the day of his death, when he was found dead in the water-closet of a restaurant, as stated.

Autopsy, twenty-four hours after death. Body of very peculiar configuration. While abdomen and chest were enormously distended, the body was that of a very lean subject. Bodily height, 5 feet 7½ inches; total body weight, approximately, 150 pounds. Circumference of abdomen on line of umbilicus, 7 feet 2½ inches; circumference of chest, below nipples, 5 feet and a fraction of an inch. (Plates I and II give a quite adequate appearance of the shape of the body, yet the dimensions of the thoracic and abdominal cavities were greatly augmented at the time of death, or, rather, at the autopsy.)

The skin had a glossy, pale appearance, and about the abdomen there were some post-mortem discolorations of the integument, most marked in a broad line about five inches wide, going obliquely from the right hypochondriac region toward the left groin. The abdomen was extended by gas, like a drum, and a large quantity escaped on incision. Section of the integuments of the body revealed nearly complete absence of the *panniculus adiposus.* In fact, there appeared to be general absence of adipose tissues, not only in the trunk of the body, but also in the integuments of the extremities, there being even less in the latter. There was also a general atrophy of the muscles of the body. The extremities were reduced to about two-thirds of their normal circumference.

The peculiar disfigurement of the body was found to be due to an enormous distention of the abdominal cavity, with huge increase of its viscera, encroaching upon the thoracic cavities. The spine was unduly straight. The ribs were normal in number, but anomalous as to direction of their growth. They all extended at right angles from the axis of the spine, which, as stated, was remarkably straight. In other words, the ribs—even the lower ones—pointed upward instead of downward; and the sternum, which was unusually short, measuring only 4½ inches, pointed at an angle of 90 degrees from the cervical portion of the spine.

The distention of the peritoneal cavity had pushed up the diaphragm as high as the third intercostal space anteriorly, and the fifth dorsal vertebra posteriorly. The thoracic cavity was reduced to about one-third of its normal

1757
ackard.
Presented by Dr. W. A. Edwards.
45
3077.
1873
117-3
3087-
1874
117
3
Circular Enterostomy.
Mucous colitis.
The mucous membrane is eroded in patches.
Case of Dr. Edward Parker.
Destroyed Jan. 24, 1941 because it could not be identified. Auth. Committee Drs. Schaffer, Custer, McGuigan, McFarland, Curator
3087.50
1880
118
3
Specimen not labelled
Pres by Dr. W. A. Edwards

capacity. The heart was normal in every respect, but occupied a perfectly horizontal position to the axis of the body, the apex occupying about the second intercostal space to the left side of the sternum.

The section of the heart and aorta did not reveal anything abnormal, all the valves and orifices being perfectly consistent, and the musculature of the walls perfectly proportionate.

The blood was absolutely fluid in the cavities of the heart, as well as throughout the rest of the body, indicating that death must have been instantaneous. The pleural sacs contained no fluid, and, like the pericardium, showed nothing abnormal except diminution in size. The lungs, likewise, occupied a horizontal position, the apices pointing toward the spine, whereas the basis of these organs faced the sternum lying between the first and third ribs. Sections of the lungs showed them to be highly congested from passive hyperæmia and somewhat œdematous ; otherwise the parenchyma of the organs was normal.

Abdomen. No excess of peritoneal fluid, although the surfaces of the peritoneum had an unusual degree of moisture. The color of the surfaces was normal, no evidence of any hyperæmia or inflammatory conditions in any part. A most striking appearance was presented by the colon. It was distended by fæcal contents and by gas, and although occupying a normal direction in the abdomen, it was of huge dimensions and occupied large portions of the thoracic regions of the body. By a rough estimate it had the appearance of being at least ten times wider than normal, the exact measurements being as follows : Total length of colon, 2.52 metres (about 8 feet 4 inches). The rest of the figures relate to the circumference of the bowels : Cæcum, 26 c.m. (10 inches) ; colon, ascending part, 37 c.m (15 inches) ; colon transverse part, gradually increasing from 38 c.m. to 76 c.m. (15 inches to 30 inches) ; colon, descending part 60 to 62 c.m. (24 to 25 inches) ; sigmoid flexure, 62 to 69 c.m. (25 to 27 inches).

The meso-colon was abnormally large and thick, which, however, was perfectly consistent with the enormous hypertrophy of the colon.

The whole of the colon thus presented a gradual increase in size or width from the cæcum to the sigmoid flexure, the greatest increase in width being in the transverse portion.

There were no distinct angles or M-shaped figuration of the colon or the so-called kinking of the bowel, as has been described in some cases. In fact, no mechanical, visible, or obvious reason for obstruction could be discovered in any part of the tube.

The contents of the colon was represented by two and a half pailfuls of fæces, which weighed forty pounds. The physical character of the fæces appeared to be normal, appearing as a semi-fluid, dark-brown mass, with perhaps a somewhat greenish tinge ; microscopically and chemically nothing abnormal was discovered.

The rectum was perfectly normal in dimensions ; its muscular coats were quite thick, and it presented a striking transition from extreme dilatation of the sigmoid flexure and the rest of the colon above to that of contraction, although no abnormal anatomical appearances of contraction, that

could have led to any obstruction, could be discovered either in the rectum or anus.

This remarkable excess in size was, however, limited to the large intestine ; the small intestines, as well as the rest of the alimentary canal, being of normal dimensions. The vermiform appendix also was normal, measuring 15 c.m. (6 inches) in length and 1 c.m. ($\frac{2}{5}$ inch) in width. It was patulous, and contained a small amount of fæcal concretions.

The coats or walls of this specimen of large intestine, even when examined fresh, did not appear to be unduly thick ; in fact, the bowel presented to the naked eye no alterations except those referring to the muscular coat, which will be described below. There was a notable absence of sacculations throughout the whole of the colon, evidently due to an abnormality of the muscular coat, and a remarkable lack of epiploic appendages. I have stated before that there was a nearly total absence of visible adipose tissue, and this particularly holds good for the peritoneum and omentum. The omentum was ill-developed, and was found retracted or rolled up toward the diaphragm. The whole alimentary canal, with contents intact, was removed, ligatures being put at the œsophagus and rectum, and, without the liver, proved to present the actual weight of 57½ pounds, and although, unfortunately the colon was not weighed by itself, at least 47 pounds must be allowed for its weight, for the stomach and the small intestines, being normal in size, hardly represented a weight exceeding 10 pounds, as will be seen below.

Stomach. Contained some undigested food, which presented the appearance that death had ensued after a full meal. The stomach was of absolutely normal dimensions, and showed no other pathological changes than some thickening of the mucosa with mamillation or folds. Microscopical sections revealed a simple hypertrophic condition and a catarrhal condition of the gastric and peptic glands, and a decided increase of connective tissue in the submucosa. The muscular coats were also somewhat increased in thickness. The œsophagus was normal. Duodenum and small intestines did not present anything visibly abnormal, either as to length or calibre, and microscopical examination made from the fresh specimen showed nothing beyond some slight catarrhal change, and some increase in the volume of the tissues in both the submucosa and muscular coats.

Liver. Weighed 3½ pounds. Shape of the organ somewhat deformed, the left lobe being nearly as large as the right. There was nothing otherwise noteworthy. Its color, consistence, and surface presented nothing abnormal.

Gall-bladder, and contents, normal and ducts likewise.

Pancreas and duct normal, there being only a few hemorrhagic foci in the glandular structure. The only abnormality, which relates also to the liver, was that of position, both organs being located in a region normally belonging to the thoracic cavity, approximately as high as the fourth or fifth rib or intercostal space.

Spleen. Weighed six ounces. Normal in appearance, but in a position at least six inches higher than normal, and unusually movable and without any contact or proximity with the left kidney.

1757

Presented by Dr.W.A.Edwards.

3077 45
3077 200
1873
117-3
3087-
1874
117
3

Circular Enterostomy.

Mucous colitis. The mucous membrane is crowded in patches.

Case of Dr. Edward Parker.

Destroyed Jan. 24, 1941 because it could not be identified. Auth. Mutter Committee Drs. Schaffer, Custer, McBride

3087.50 Specimen not labelled
1880
118
3

Pres by Dr. W. A. Edwards

Dr. McFarland Curator

Kidneys. Normal, also supra-renal bodies.

The *semilunar ganglion* and a few other nerve plexures were secured for microscopical examination, the result of which was rather negative, because nothing abnormal could be seen, except, perhaps, some undue pigmentation of the ganglionic cells, a condition that is sometimes observed in perfectly normal cases.

Urinary Bladder. Ureters and generative organs perfectly normal, except that the left testis, which was larger than the right, showed a few small cysts.

Brain showed nothing abnormal.

Cord, not examined.

A close search was made for any evidences of obstruction of the bowel, of recent or old origin, but in no part of the intestinal tract was any lesion discovered that could or would have led to obstruction.

The great hypertrophy of the colon thus finds no explanation in any morbid or acquired anatomical lesion. Examination of the walls of the large intestine failed to reveal any morbid changes whatsoever beyond a numerical hypertrophy.

I much regret that the examination was not made at a time when the specimen was fresh, on account of our anxiety to preserve the specimen unmutilated, and to enable us to make a dry preparation after the specimen was inflated to exactly the same proportions as found at the autopsy. Only subsequent to this, and after the specimen was fairly dried, a microscopical examination was made of three parts of the colon, viz., ileocæcal valve, transverse colon, and near the rectum. Although the examination of these specimens, which had to be re-moistened, did not yield quite satisfactory microscopical sections, yet they presented the same appearances as a normal colon did prepared under the same circumstances and conditions.

The naked eye appearance of the specimen when fresh failed to indicate or suggest other than structural change, those of bulk or size; in fact, the walls of this colon, if anything, are somewhat thinner than normal.

From a morphological standpoint it may be said, however, that besides the giant growth, this colon presented an abnormality in the distribution of the longitudinal bands of muscular tissue, and possibly also of the circular coat. The well-known three bands, or *tæniæ*, that traverse the colon longitudinally were unusually ill-defined, in fact, appear to be missing in certain parts of this bowel, or are so uniformly dispersed that they have lost their individuality.

The lack of the prominence and effects of these muscular bands easily explains the rather imperfect sacculation of the walls of this colon.

From the above it is evident that we deal here with a uniform hypertrophy of the colon, which might be defined as a numerical hypertrophy without morbid change or morbid cause, except those of excess in bulk or size, and we must class this specimen as one belonging in the category of giant growths or *monster per excessum.*

Literature. An examination of the literature of this subject, both as regards the congenital hypertrophy or dilatation, or constipation leading to dilatation, revealed but a few cases in which the enlargement of the colon had reached such dimensions.

1757

The external opening is about 3 cm. long. The bowel is well united to the abdominal wall.

Presented by Dr. Mütter.

3077.35 4
3077.~~100~~ 35
1875
118
3

Specimens from a case of lumbar colotomy. The specimen embraces the uterus, the seat of an extensive cancer involving the fundus, neck and vegina; also a portion of the bowel terminating in the artificial anus, the edges of which appear perfectly healthy and show an opening 3- 4 cm.

From Mrs. H. aged 49 years, who underwent the operation of lumbar colotomy for uterine cancer. The tumor encroached on the calibre of the rectum so as to produce by mechanical interference with the passage of faeces, the most intense distress. The gut was reached by an incision four inches long, slightly curving outwards and downwards from the upper and outer corner of the quadratus lumborum muscles. An opening one inch long was made in the bowel and the edges were turned over and secured to those of the incision through the skin.

The woman was at the end of fifteen weeks suffering from only the original disease.

Presented by Dr. John H. Packard.
Presented by Dr. W. A. Edwards.

3077.45 4
3077.~~200~~ 45
1873
117-3 4
3087-
1874
117
3

Circular Enterostomy.

Mucous colitis. The mucous membrane is crowded in patches.

Case of Dr. Edward Parker.

Destroyed Jan. 24, 1941 because it could not be identified. Auth. Mütter Committee. Drs. Schaeffer, Custer, McGrigor, Dr. McFarland Curator

3087.50 4
1880
118
3

Specimen not labelled

Pres by Dr. W. A. Edwards

1739

CHOLERA.

3090-1 to 3090.20 all listed separately on Pg 1767 1769 1771

The following preparations were made in 1849 by Dr. John Neill then demonstrator of anatomy in the University of Pennsylvania at the instance of a committee appointed by the College of Physicians to investigate the condition of the mucous membrane of persons dying of cholera. The committee consisted of Drs. Samuel Jackson, John Neill, Henry H. Smith, and William Pepper.

The specimens have been injected with turpentine and either vermillion, orange or yellow coloring matter so as to reach the capillaries.

The committee after examining specimens from twenty-five cases of cholera reported that, in the recent subject, that,

1st. The peritoneal coat, like all the serous membranes was in all remarkably dry; that the lubricating serosity is deficient in all the membranes.

2nd. The epithelial layer of the intestinal mucous membrane was, in all specimens, either entirely removed or was detached, adhering loosely as a pulpy layer, mixed with mucous or an albuminoid substance.

3rd. Peyer's glands were developed to a greater or less extent in all the cases examined.

4th. The villi were denuded of their epithelial covering, but were unchanged in other respects.

5th. The capillaries were entire and manifested no departure from the normal state, being, in appearance, identical with healthy mucous membrane when the epithelium has been removed.

See Trans. Coll. Physicians Phila. 1849. 3. 35

3090- Small intestine from a case of cholera;injected
1876
118 yellow.
3

Presented by Dr. John Neill.

3090.01- Small intestine from a case of cholera;
1877 injected.
118
3

Presented by Dr.Neill.

3090.02- Small intestine;cholera;injected yellow.
1878
118

Presented by Dr.Neill.
3

3090.03- Intestine;cholera;injected red and dried.
1879 The glands of Peyer are well seen.
118
3

Presented by Dr.Neill.

3090.04- Healthy intestine;injected.
1881
118 The epithelium has been removed by maceration.
3

Presented by Dr. Neill.

3090.05- Portion of large intestine;cholera.
1882
117

Dr.Neill.
4

3090.06- Intestine;cholera;injected yellow.
1883
117

Dr.Neill.
4

3090.07- Intestine;cholera;ulcers in the mucous mem-
1884 brane.
117
4

Dr.Neill.

3090.08- Intestine;cholera;injected red.
1885
117
4
Dr.Neill.

3090.09-D.47Intestine;cholera;injected yellow.
1886
117
4
Dr.Neill.

3090.10-D.48Intestine;cholera;injected red.
1887
117
4
Dr.Neill.

3090.11- Intestine;cholera;injected red. Showing denuded mucous membrane.
1888
117
4
Dr.Neill.

3090.12- Intestine;cholera; yellow.
1889
117
4
Dr.Neill.

3090.13- Intestine;cholera;yellow.
1890
117
4
Dr.Neill.

3090.14- Intestine;cholera;yellow.
1891
118
4
Dr.Neill.

3090.15-D.53-Intestine;cholera;yellow.
1892
118
4
Dr.Neill.

3090.16-D.54-Intestine;cholera;red.
1893
118
4
Dr.Neill.

3090.17D.55-Intestine;cholera;yellow.
1894 -118- 4
Dr.Neill.

deaccessioned

3090.18D.56-Intestine;cholera;yellow.

1895
118
4

Dr.Neill.

3090.19D.57-Intestine;cholera;injected orange.

1896
118
4

Dr.Neill.

3090.20D.58- Intestine;cholera;yellow.

1897
118
4

Dr.Neill.

3092- Portion of large intestine;ulceration of the peri-
1898 toneal coat,
117
5

From a case of fibroid thickening of the stomach,

See D.17

Presented by Dr.S.Weir Mitchell.

3092.05- Colon;ulceration.
1922
117 The ulcers are small and are generally disseminated
7 throughout the mucous membrane of the bowel.

From the Philadelphia Hospital.

3092.10- Colon;ulceration.
1923 This specimen is similar to the last;a perforation oc-
117 curred at one point.
7

From the Philadelphia Hospital.

missing

3092.20- Portion of the colon;ulceration.
2064 The mucous membrane is ulcerated in large irregular
120 areas.
6

Presented by Dr. Mütter.

1772
3105.12 Cancer of Rectum. Stricture
1928
118
7
Pres by Dr Drysdale

3098- Intestine - Dysentery ulcer of ileum
Colon - Pg. 1773

1773

3099.
~~3092.50~~ Portions of small intestine;lesions of typhoid
1845
110
6 fever.

Peyers patches are large and were in the stage of ulceration, The specimen is mounted dry between glass plates.

Presented by Dr. Mütter.

3099.05
~~3092.40~~ Portions of small intestine;lesions of typhoid
1920
117 fever.

3099.10 Portion of Small Intestine; lesions of typhoid fever.
~~3092.41~~
1925
117

3093- Portion of small intestine. Enlarged longitudinal
1899
117 gland.
5

Presented.

3098. Dysentery - Intestine see filing card.
Presented by U.S. Base Hospital No. 20

3103.10- Stricture of the small intestine.
1900
117
5 The intestine is totally occluded by a firm stricture.

From an adult.

Presented.

3105-
1901
117
5 Stricture of the large intestine;cancer.

Presented by Dr.W.L.Atlee.

3105.10 Stricture of Rectum " " " Drysdale
1926
118-7

~~3105.10~~ 3105.12. Pg. 1772 ~~Cancer of the rectum;stricture.~~

3105.11 " " " " Presented by Dr Drysdale
1445 Missing
39
6

Presented.

3105.15- Large colloid cancer of the abdomen.
1927
118
7

Presented by Dr. Mütter.

3105.20- Caecum;cancer.
1910
117
6

Presented by Dr. Mütter.

3120.5 X Appendicitis
1908
118
5
Pres by Dr J B Roberts

3113.50 X Inguinal hernia
1911
117
6
Pres by Dr J B Roberts

IX
3130.50 Appendix partly Gangrenous, showing
2849 Entrolith, also a large portion of
118 omentum Resected
5
Pres. by Mr. W. S. Rodman.

3112.00 See Page 1783 - Vol. 1
Vermiform appendix. Removed by Dr.
John B Roberts

Specimen 3110

P. 1775 A
1889 Mar. 18

1317 Spring Garden St.
March 18th 1889.

#3110

Guy Hinsdale, M.D.

My dear Dr.

I have a beautiful specimen of obstruction of the bowel which I will be pleased to give the College of Physicians and Surgeons' Museum - and as soon as the recovery of the case is complete, will give you its history also - You can either send for specimen or I will try and deliver it soon -

Yours truly
Mordecai Price -

Dr. Guy Hinsdale -

Lep. 6325
Ove. lipoma
637.045

3120.5 X Appendicitis
1908
118
5

Pres by Dr J B Roberts

3113.50 X
1911
117
6

Inguinal hernia

Pres by Dr J B Roberts

3130.50 IX
2849
118
5

Appendix partly Gangrenous, showing Entrolith, also a large portion of omentum Resected

Pres. by Rev. W. S. Rodman.

3112.00 See Page 1783 - Vol. 1
Vermiform appendix. Removed by Dr. John B Roberts

Well write you further soon.

3120.5 Appendicitis
1908
118
5
Pres by Dr J B Roberts

3113.50 Inguinal hernia
1911
117
6
Pres by Dr J B Roberts

3130.50 Appendix partly Gangrenous, showing
2849 Entrolith, also a large portion of
118 omentum Resected
5
Pres. by Dr. W. S. Rodman.

3112.00 See Page 1783-Vol. 1
Vermiform appendix. Removed by Dr.
John B Roberts

3105.25- Caecum; cancer.
1902
117
5
A cork is in the small intestine; the appendix has been removed.

3105.30 Cancer of the bowel. Presented by Dr. Mütter.
Presented by Dr. Drysdale
3105.35 Carcinoma of the sigmoid flexure
3105.40 Cancer of the rectum Dr Baldy

3107- Small intestine. Polypi.
1929
118
7
From a case in the Philadelphia Hospital. Cysts were found in the ovary.

Purchased.

3108 Villous Tumor of the Rectum.
1903
117-5
The specimen has been cut into two pieces. Presented by Dr. Shober.

3109- Rectum; large hemorrhoids.
1904
118
5
Presented by Dr. Mütter.

3110- See letter
1905
118
3
Intestinal obstruction.

Dr. Mordecai Price.

3113 Intestine from strangulated femoral hernia. 5 days strangulated
1906
118
5
Dead 12 hours after operation. Presented by Dr. John B. Roberts.

3120-D.67- Portion of caecum and small intestine; perforation of the appendix. The appendix is perforated at its extremity.
1907
118
5

Presented by Dr. Mütter.

3130- Appendix vermiformis; gangrene and perforation.
1909
118
6
When recently observed the appendix was inflamed and greatly enlarged and intimately adherent to the surrounding parts. It was distended to a sac 5 cm. long and 2cm. broad and communicated by a small orifice with the cavity of the head of the colon. Its walls were thickened and infiltrated with dark blood and serum. Its peritoneal coat was highly injected and covered with exudations and its mucous lining presented

traces of extensive inflammation which had run into superficial gangrene;the latter has produced a honey combed appearance of the inner surface and had covered it with a dark-greenish,pulpy and extremely fetid matter.

"On its side,about two-thirds of the distance from its coecal extremity,an ulcerated perforation,some six ~~lines~~ inches long by three in width,was found,from which fluid foecal and other matter had been flowing in small quantities. Immediately behind this opening,and encased by the appendix,a peculiar, moderately-hard concretion,of the shape and color of an elongated olive stone,presented itself,having been apparently moulded by the cavity by which it was contained. Longitudinal and transverse sections of this mass showed it to have been cast in successive layers,and that it was probably hardened faecal excrement which had accumulated by a slow deposit from the oozings of the fluid contents of the large intestine through the orifice of the appendix.

" No other evidence of morbid action in the abdominal or pelvic cavities,except a congested and oedematous condition of the ovaries and fimbriated tubes. The right ovary was enlarged to more than twice its natural size,and affected witha serous cyst of the size of a large English walnut. The left was similarly affected,but not to the same extent.

" The examination was not extended beyond the cavities described.

From J.M.L.,aged 14;of fair complexion,and rather delicate in general appearance; had usually

enjoyed good health. The only complaint to which the attention of her parents had ever been attracted was an occasional catarrh,or something of that kind, which they called a 'bronchial affection'. Some other members of her family had remarked, however, that she was in the habit,from time to time, of suddenly putting her hand to her side and exclaiming that she suffered froma shooting pain in that region.

"About 11 o'clock in the forenoon of Tuesday, Feb.26th, while sitting quietly at school,she was suddenly seized with nausea and vomiting of bilious matter,and with pain in the bowels. On Friday,irritation of the bladder supervened,presenting all the symptoms of a distressing strangury. By Friday evening the suffering of the poor patient had become intolerable. Distension of the abdomen,unceasing thirst,constant inclination with entire inability to urinate,and finally nausea,with vomiting of a dark-greenish brown fluid resembling coffee grounds, were prominent symptoms. The countenance was pinched,and altogether cadaverous incolor and expression;skin cold and clammy,and the whole body bathed in a prostrating perspiration. Pulse 130,very small and thready,so feebleand uncertain in its action as at times to be almost imperceptible. Pain seated in the whole lower part of abdomen,but principally around the navel and in theright iliac region. She complained of constant agonizing thirst,and death-like nausea,and was annoyed with frequent

1781

retching and ejection of flocculent coffee-colored fluid. Abdomen distended and resonant, and moderately tender to the touch throughout, but especially around and in the umbilicus (which was red and swollen) and in the right iliac region.

Peritonitis continued, ending in death on the fifth day.

1:86

Trans. Coll. Phys. Phila. Apr. 1st, 1851.

Presented by Dr. E. Hartshorne.

3131-
1912
117
6

Appendix vermiformis. Cæcum and a portion of the ileum; perforation; peritonitis; death.

When recently examined a perforating ulcer of the appendix was found through which a grooved director could be passed communicating freely with the peritoneal cavity. There are two perforations; one, 25cm. from the caput coli; the muscular coat of the bowel appeared to have been destroyed by ulceration and then the peritoneal coat had given way in three small openings about 2mm. in diameter. These were arranged in a triangular manner. The second was a solitary perforation 4 cm. from the end of the appendicula. Although thick patches of lymph had been thrown out, still no attempt to limit the effusion of foreign material by lymph barriers was discoverable. There was nothing to show that any foreign body or impaction of feces had been the origin of the lesion. Fluid pus was found in the interspace between the liver and stomach and six fluid ounces of turbid serum in the pelvic cavity. The intestines were

glued together by lymph.

From Mrs.S.,aged 25 years,the mother of two children,the younger four months old. Death occurred on the fifth day of idiopathic peritonitis with characteristic symptoms.

missing Page 1774-Vol. 1

3112 Presented by Dr.A.D.Hall.

1913-117-6 ~~3131~~ Vermiform appendix. Removed and presented by Dr. John B. Roberts.

1914-117-6 3132.1 " " "

he had been subject to sudden and severe attacks of abdominal pain. These attacks came on without warning while he was in excellent health, and would completely prostrate him. The pain was of a stabbing character, and was most intense across the lower part of the abdomen, and especially around the umbilicus; it was attended by great irritability of both rectum and bladder; sometimes there would be diarrhoea, but there was always a marked increase in the quantity of water voided, the urine being red "like blood" in color. He is of the opinion that he has at times passed blood in his urine. These attacks, after lasting a few hours, usually passed a way gradually, leaving him rather weak for a short time; but he rapidly recovered, and enjoyed uninterrupted good health until the next attack came on.

April 20th. He looked haggard, said that he felt miserable, and had pains in his muscles in different parts of his body. At this time, he did not complain of abdominal pain.

April 24th. Pain persisting; copious movements from calomel. Point of greatest tenderness midway between the umbilicus and the middle of Poupart's ligament. A resisting mass the size of a small egg could be felt on deep pressure. Temperature 103.5 Pulse 140.

April 25th. Excruciating pain. Swelling larger, tender.

April 27th. Right lower half of abdomen

dull on percussion. After consultation with Dr. James C.Wilson and Thomas G. Morton, laparotomy was performed by Dr.Morton.

The incision was made directly over the swelling, and finding the muscles infiltrated with pus it was extended until it measured nearly ten inches; commencing just above and two inches to the right of the umbilicus, it continued obliquely downward to the pubes. The peritoneum was opened, and a free flow of pus followed, having a decidedly fecal odor; in it was found a concretion resembling a cherry-stone. The vermiform appendix was greatly swollen, and exhibited a perforating ulcer extending three-fourths around its circumference, and very near to the point of origin. A silk ligature was applied close to the caecum and at the terminal portion of the appendix, and the intervening portion, comprising almost the whole organ, was removed, together with a large portion of omentum which projected into the abscess-cavity, the walls of which were then scraped with a curette and douched with simple warm water.

Following the operation he entered upon convalescence, which was uninterrupted. He was entirely free from abdominal pain, except from distention of the bladder, requiring the use of the catheter for a week. The bowels were moved naturally on May 1st, after he had yolks of two eggs in milk. The temperature fell after the operation, and did not again rise above 100°. The drain-

3203 No labelled Destroyed Jan 24, 1941 because it could not be identified. Auth. Mütter Committee
1916 Dr. J. Parsons Schaeffer - Dr. R. Philip Custer - Dr. Amos C. McGuinness
118
6

3205 Malignant disease of the rectum
1917
118
6 Pres by Dr J B Roberts

3205.5 Malignant disease of the omentum
1919
118
6 Pres by Dr J B Roberts

3310. Femoral Hernia.
2063
120
6.

3309. Sac of Hernia and Omentum
2850. removed in operation for Strangulated
118 Hernia at Clinic. Kentucky of
4 Medicine. Pres. by Dr. W. S. Rodman

age tube was removed piecemeal; the last portion was taken away on the 13th of May. He sat up on May 11th, and rapidly regained strength. He was out riding May 21st. His recovery was complete June 18th.

9:183

Trans. College of Physicians, June 1st, 1887.

For concretion analysis, see 14683.

Presented by Dr. F. Woodbury.

missing
3142.10- Appendix vermiformis containing a calculus.
1930
118

Presented by Dr. J. M. Corse.

3202. Tuberculous mesenteric lymph nodes. Extensive ~~caseation~~ necrosis

3225- Enlarged mesenteric glands.
1918
118
6.

Presented by Dr. Mütter.

missing
3225.10- Enlarged mesenteric glands.

Presented by Dr. Mütter.

missing
3311- Inguinal hernia.

The specimen shows the gut protruding through the external abdominal ring. The bowel was apparently in good condition.

Presented by Dr. Mütter.

missing
3311.05- Inguinal hernia; strangulated.

The bowel is seen at both extremities of the inguinal canal; several large loops project from the external ring; they are gangrenous.

Presented by Dr. Mütter.

3311.10-
D.88- Strangulated inguinal hernia.

1920
118
6

Presented by Dr. Mütter.

3311.15-
D.89- Double inguinal hernia.

1445

This is a dried preparation. The vessels have been injected; the obturators and epigastrics arise by a common branch from the external iliacs. It is difficult, from the specimen to say what their position was in reference to the crural ring. Dissecting room specimen.

Presented by Dr.F.C.Hand.

3322- Mesenteric hernia.

2014
119
1

There is an opening in the Mesentery through which several coils of small intestine have been forced.

From a man who suffered from cancer of the stomach attended by retching and momiting which occasioned this displaceness of the bowel.

Presented by Dr.Horace Williams.

3327- Invagination of the ileum.

1931
119
1

The intussuscepted portion is about 45cm. long. The whole of the intestine included in the intussusception and below the point of constriction is gangrenous and, at the point of constriction at the commencement of the Intussusception, there is a gangrenous ulcer.

1793

From a woman who died after a history of attempted abortion. One year previously she had an attack of peritonitis. Previous to death she had on several occasions abdominal tenesmus.

Presented by Dr.C.M.Wilson.

3329-
1932
119

Invagination of the ileum, caecum and ascending and transverse colon in an infant aged 6 months.

At the autopsy the ileum was found to terminate by apparently plunging directly into the descending colon. The mesentery was tightly wound around the ileum at the point of entrance. The lower part of the ileum has passed through the ileo-caecal valve and the caecum and ascending and transverse colon have successively been invaginated until the whole mass has been forced down the descending colon and rectum to within three inches of the anus. The descending colon was little congested; the mucous membrane of the invaginated bowel was intensely congested, much discolored and roughened and presented numerous shreds of grayish lymph. The most dependent portion of the invaginated mass presented (where the colon was doubled on itself again to form the internal layer) a slit-like orifice with thick rounded lips, not unlike the os of a mutiparous uterus. The wall of the middle layer of the invaginated mass was thickened, softened and intensely congested. The space between the middle and internal layers of the invagination was occupied by recent, succulent

1795

lymph presenting numerous delicate organized fibrillar trabeculae. The vermiform appendix of the caecum was found coiled up in this space, imbedded in the lymph. The entire length of the invagination was 18 cm. So that the amount of bowel invaginated was between 36 and 40 cm.

The extreme congestion and thickening of the invaginated bowel led to its firm incarceration, so that it was impossible to withdraw the ileum even by the use of considerable force. The intestine about the point of intussusception was distended with fluid yellowish fecal matter.

From a male infant aged 6 months, who died on the fifth day of a painful illness characterized by nausea, vomiting and bloody stools and the presence of a distinct tumor in the left iliac region.

See Dr. Wm. Papper's reprint in Trans. Path. Soc. Phila. 187~~1~~4. 4: 50 - April 13

Presented by Dr. Isaac Norris.

IX

3331-
1933
119
1

Ten inches of large intestine passed per anum as a slough.

Presented by Dr. Traill Green.

3403
1942
119
2

Rupture of the Liver. " " " W. J. Taylor.

3409-
1934
119
1

Syphilitic liver.

The specimen shows syphilitic cirrhosis. From a man aged 35 who died of chronic nephritis after six months illness. He [illegible]nied syphilis.

3423.5 Cancer of the liver
1937
119
1
missing

3423.7 Specimen of Liver and spleen.
2065 Showing many small nodules on
120 each.
6. missing

No other evidences of syphilis present.

Presented by Dr. Judson Daland.

2015
119
1
3410 Cirrhotic ("hob-nailed") liver. Presented by Dr Dysdale.

3416-
1959
119
4
Abscess of the liver.

The liver is large and shows in its diaphragmatic surface a large abscess cavity deeper posteriorly than anteriorly. The liver tissue of the cavity is ragged.

Presented by Dr. Mütter.

3416.10- Abscess of the liver.
1960
119
4

Presented by Dr.M.B.Musser,
12/1886.

~~3417~~ ~~Liver. Cystic disease~~ Presented by Dr John B. Roberts
~~2061~~
~~120~~
~~6~~
~~See 4339.35 History in full.~~ This is number of specimen

3422-
1933-
119
1
Melanosis of the liver.

The specimen is small and exhibits two melanotic spots, the larger of which, is about 1 cm. in diameter. They are separated only about a millimeter from each other.

Presented by Dr. Henry Bond.

3423-
1936
119
1
Large cancer of the liver.

Presented by Dr. W. E. Hughes.

missing
3423.4 Cancer of the Liver.
Associated with Cancerous stricture of the ascending Colon and followed the removal of a rapidly growing ovarian tumor. Nov. 13. 186
Presented by Dr. Dysdale

3423.10- Cancer of the liver.

The specimen consist of a pale section of the liver which probably showed, ~~when~~ , characteristic appearances.

Presented by Dr. Mütter.

3454.1 Rupture of the Gall-bladder
1940
119
1.
Pres by Dr F A Packard

3450- Gall-bladder which originally contained a calculus.
1938
119
1

The calculus has long since been dissolved or disintegrated by the action of alcohol. Silk threads which were used to fix it in place show that the stone was about 1cm. in diamater. Some fine undissolved powder is seen in the bottom of the jar.

Presented by Dr. Mütter.

3454- Rupture of the gall-bladder.
1939
119
1

Presented.

3455- Gall-bladder with a portion of the liver; cellular degeneration of the liver; hypertrophy of the gall-bladder;gall-stones,
1941
119
1

6095.05 When recently removed,the liver was considerably enlarged;the parenchyma about the gall-bladder which projected far beyond the lower edge was changed into a white hard mass which showed on its surface a number of smaller blood-vessels;on cutting into it,it was soft like cellular tissue and had not the hardness of scirrhus; on pressing it there appeared on the cut surface a white cheesy mass. The parenchyma was engorged with blood and contained several grayish tumors the size of walnuts, The gall-bladder was three times its normal size,owing to hypertrophied cellular tissue;the duct was ob-

1801

literated; its walls were thickened and it contained two large gall stones consisting of cholesterine mixed with dried gall which, united, had an ovoid figure. The larger of the two, washed and dried, weighed 37 grammes (555 grains); the smaller 17 grammes (255 grains). They were brownish yellow, only in some spots perfectly white and covered with a white film on their surface. No gall in the gall-bladder.

Cysts of the Fallopian tube were also present.

From a woman aged seventy years, of perfect health until four months previous to death. She then complained of intense pains, of a bearing down character, in the lower part of the abdomen. The latter began to swell a few days before death and the bowels remained obstinately closed. She never complained of any pain in the region of the liver.

Trans. Coll. Phys. Phila. June 1851. 1:118

Presented by Dr. Keller, 1851.

3456, 1986 120 1 Gall stones from the same.

3460- 1987 120 1 Hypertrophied and perforated gall-bladder. The perforation occurred near the middle of the gall-bladder and admits a knitting needle. The walls of the bladder are thickened.

Presented by Dr. Mütter.

3510- 1988 120 1 — Pancreatic duct opening into the intestine.

Presented by Dr.Packard.

3540- 1989 120 1 — Scirrhus of the pancreas and ulceration of the duodenum.

Presented by Dr.Alfred Stille.

3575- 1990 120 1 — Submaxillary gland; scirrhus.

Presented by Dr. Mütter.

3601- 1991 120 1 — Spleen and stomach. Anomaly.

The spleen was taken from a negro child aged 6 months, who died in the Philadelphia Hospital.

3605. 2062 120 6 — *Hypertrophied Spleen. Presented by Dr. John B. Roberts.*

3800- 1992 120 1 Res. — Addisons Disease.

Two specimens of right and left kidney, Showing arterial supply, ureters, etc.

The smaller specimen is from a boy aged eleven years.

Presented by Dr.Osler.

3900.15 see Vol I page 1805 ~~3800.1~~ Enlarged & cystic thyroid

1993 120 1

Pres by Dr JB Roberts

1805

3900 Hypertrophied Thyroid Gland. Presented by Dr. J. B. Roberts

1994

120

3900.05 see Vol I Page 1724. Old No. 2857

3900.10 see Vol I Page 1724. Old No. 2853

3900.15 see Vol I Page 1803

1807

1889
1889
07
20

50
10